



## PEARLY PENILE PAPULES WITH HAIRY PENILE SHAFT : A CASE REPORT

### Dermatology

**Dr. Vipul Paul  
Thomas**

Junior Resident, Department of Dermatology, Venereology & Leprosy, Sree Balaji Medical College & Hospital, Bharath University, Chennai 600044, Tamil Nadu, India.

**Dr. Subashree**

Junior Resident, Department of Dermatology, Venereology & Leprosy, Sree Balaji Medical College & Hospital, Bharath University, Chennai 600044, Tamil Nadu, India.

**Dr. Jayakar  
Thomas\***

HOD & Professor, Department of Dermatology, Venereology & Leprosy, Sree Balaji Medical College & Hospital, Bharath University, Chennai 600044, Tamil Nadu, India. \*Corresponding Author

### ABSTRACT

Pearly penile papule are dome shaped papules commonly affecting the coronal margin of the penis and sometimes seen over the glans also. This report describes a 32 year old man with multiple pearly papules over the coronal sulcus of penis with hair over the shaft of the penis.

### KEYWORDS

Pearly Penile Papules, Coronal Sulcus

### INTRODUCTION:

Pearly penile papule like lesions were first described by Littre in 1700. Later in 1888 Duhring explained that these lesions might be nervous tissue.

Penile pearly papules appear as small, asymptomatic, smooth, dome shaped papules occurring at the coronal sulcus mainly but also involve the glans rarely<sup>1</sup>. These are relatively common and are found in up to fifty percent of men.

### CASE REPORT:

A 32 year old male came to the Dermatology OPD with complaints of multiple papules over the penis for past 4 years. Patient also complains of hair growth over the shaft of penis. 4 years back he underwent circumcision. After a few weeks he noticed papules over his penis. He also noticed hair growth over the shaft of the penis. History of itching present. History of pain after shaving. No history of drug intake prior to the appearance of papules and hair growth. No history of similar lesions elsewhere. No history of trauma. No history of similar lesions in the family.

On examination, multiple flesh colored pearly papules over the coronal sulcus in a ring like pattern seen. Papules are dome shaped and non-tender. Hair growth seen over the shaft of penis.

### DISCUSSION:

Pearly penile papules of the penis also known as Papillomatosis Corona Penis, Corona Capillitii, Hirsuties Coronae Glandis, Papillae Coronis Glandis, and Hirsutoid Papillomas are benign lesions of the penis. PPP are considered to be a type of normal genital variants and are sometimes described as vestigial remnants of penile spines.

PPP present to as rows of rings of flesh colored shiny dome shaped papule at the coronal margin and also the glans. Size may vary from <1 mm to 3 mm. Mostly seen in adolescent adults.

Histopathology is that of angiofibroma (epidermis appears raised in a dome shaped pattern overlying a localized area of fibroplasia and fine vascular proliferation in the upper dermis) without associated hair follicles.<sup>2</sup>

Differential diagnosis for the PPP include Viral Warts<sup>3</sup>, Tyson glands, Ectopic Sebaceous Glands of Fordyce, Scrotal Calcinosis, Lichen Nitidus, Secondary Syphilis, Acrochordons, Seborrhea Keratosis, Epidermoid Cyst.

The patient is reassured and advised to avoid shaving. Clipping of the hair with a pair of scissors is advisable. Other treatment options include Cryotherapy and Laser ablation<sup>4,5</sup>.

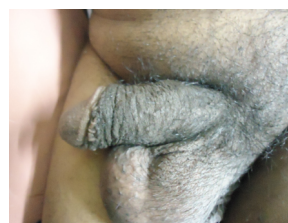### CONCLUSION:

Pearly penile papule is a normal variant of the male genital


morphology. Reassurance is the main cornerstone of management. The patient was reassured and advised clipping of hair rather than shaving.

### LEGENDS TO IMAGES

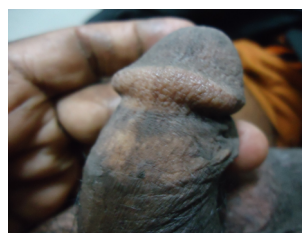**FIG:1-2 Hair Over The Shaft Of The Penis**



**FIGURE 2**



**FIGURE 3: Pearly Penile Papules Over The Coronal Sulcus**



**ACKNOWLEDGMENT:** None

**CONFLICT OF INTEREST:** The authors declare that they have no conflict of interest.

### REFERENCES

1. Agha K, Alderson S, Samraj S, Cottam A, Merry C, Lee V, Patel R. Pearly penile papules regress in older patients and with circumcision. International journal of STD & AIDS. 2009 Nov;20(11):768-70.
2. Ackerman AB, Kornberg R. Pearly penile papules: Acral angiofibromas. Archives of dermatology. 1973 Nov 1;108(5):673-5.
3. Hogewoning CJ, Bleeker MC, van den Brule AJ, Voorhorst FJ, van Andelb RE, Risse EK, Starink TM, Meijer CJ. Pearly penile papules: still no reason for uneasiness. Journal of the American Academy of Dermatology. 2003 Jul 1;49(1):50-4.
4. Porter WM, Bunker CB. Treatment of pearly penile papules with cryotherapy. British Journal of Dermatology. 2000 Apr;142(4):847-8.
5. Bunker C. Male genital skin disease. Saunders Limited; 2004.