



AN UNIQUE CASE OF OBSTRUCTIVE SLEEP APNEA – TORUS TUBARIS CYST AND REVIEW OF LITERATURE

Otolaryngology

Dr. Lakshmi Shree N. Junior Resident, Department of ENT – Head & Neck surgery, Saveetha Medical College and Hospital, Thandalam, Chennai – 602105, Tamil Nadu, India.

Dr. Shyam Sudhakar S* Senior Resident, Department of ENT – Head & Neck surgery, Saveetha Medical College and Hospital, Thandalam, Chennai – 602105, Tamil Nadu, India. *Corresponding Author

Dr. K. Shoba Professor, Department of ENT – Head & Neck surgery, Saveetha Medical College and Hospital, Thandalam, Chennai – 602105, Tamil Nadu, India.

Dr. K. Srinivasan Professor & Head, Department of ENT – Head & Neck surgery, Saveetha Medical College and Hospital, Thandalam, Chennai – 602105, Tamil Nadu, India.

ABSTRACT

Case background: A 41 year old gentleman presented with complaints of disturbed sleep, choking spells, daytime sleepiness and snoring for past five months to the ENT department at a tertiary health centre. Clinically, a cystic swelling was noted in the right oropharynx possibly extending from the nasopharynx. Patient underwent Diagnostic Nasal Endoscopy and Computerized tomography of paranasal sinuses which also showed a cystic swelling in the nasopharynx arising from the right salpingopharyngeal fold with oropharyngeal extension. Polysomnography confirmed features of obstructive sleep apnea. Coblation Cyst excision was performed and histopathological evaluation of cyst showed features of a simple cyst. Post-operative sleep study showed normal sleep pattern.

A simple cyst arising from the nasopharynx is commonly labeled with a differential diagnosis of tornwaldt's cyst when in the midline or less commonly a unilateral fossa of rosenmuller cyst. After extensive PUBMED search it was understood to be the first case report showing the rare possibility of a cyst arising from the mucosa over the salpingopharyngeal fold – a torus tubarius cyst and presenting as Obstructive sleep apnea (OSA).

Conclusion: First to be reported torus tubarius cyst with features of obstructive sleep apnea. Coblation cyst excision was done to alleviate disordered sleep pattern.

KEYWORDS

Torus tubaris cyst, Obstructive sleep apnea (OSA), nasopharynx, polysomnography (PSG), diagnostic nasal endoscopy (DNE), nasopharyngeal branchial cysts, mucus retention cyst; Torus tubarius cyst

INTRODUCTION AND LITERATURE REVIEW:

The first ever description of an Obstructive Sleep Apnea (OSA) sufferer was generally attributed to the novelist Charles Dickens, who described "Joe" in The Posthumous Papers of the Pickwick Club, published in 1836^[1].

The first physician to describe the clinical features of sleep apnea was Broadbent in 1877^[2]. Nevertheless, the first scientific case series was published only a few decades ago by Christian Guilleminault et al., 1976^[3] and coined the term "Obstructive Sleep Apnea Syndrome (OSAS)" to emphasize the occurrence of this syndrome in non-obese patients. Treatment of sleep apnea has advanced significantly. Varied etiology and clinical presentation makes room for a spectrum of treatment options.

Nasopharyngeal cysts are rare, small in size and asymptomatic, usually diagnosed as in incidental finding on nasal endoscopy / radiological imaging^[4,5]. Cystic lesions of the nasopharynx are typically benign^[6]. However, care must be taken to distinguish these presentations from neoplasms that may also arise in this region. Cystic masses of the nasopharynx are often found incidentally^[6], and as these lesions grow they can produce local compressive symptoms of nasal obstruction, aural fullness, conductive hearing loss, or cranial nerve dysfunction.

Cysts arising from the nasopharynx are classified into midline and lateral types^[7]. The most common midline nasopharyngeal cysts are mucus retention cysts^[8] and the most common lateral nasopharyngeal cysts are branchiogenic cysts. These are distinguished from other cysts based on their origin – whether superficial / deep to the pharyngobasilar fascia. Nasopharyngeal branchial cysts (NBCs) are lined with stratified squamous epithelium, pseudostratified squamous epithelium, or both. Lymphoid aggregation may be found in the subepithelial connective tissue^[9]. Oncocytic cysts (Warthin's tumor) are also a rare cause of acquired lateral nasopharyngeal cysts^[10,11]. Total excision has previously been described as the standard treatment method^[12]. But it is often challenging and carries with it the risk of potential vascular injury at the level of the skull base. Marsupialization with microdebrider has also been reported^[13].

Torus tubarius is a mucosal elevation in the lateral aspect of the nasopharynx formed by the underlying pharyngeal end of cartilagenous part of eustachian tube. The opening of the Eustachian tube is anterior to the torus tubarius. Immediately posterior to it lies the fossa of Rosenmuller. A simple cyst arising from the nasopharynx is commonly given a DD of Tornwaldt's cyst^[14] if in the midline or fossa of Rosenmuller / Nasopharyngeal branchial cyst (NBC) if unilateral. Torus tubarius cysts like other nasopharyngeal cysts are likely to present with nasal, nasopharyngeal and otological symptoms^[15]. Here we document a rare case report showing a cystic lesion from the torus tubarius with an unusual presentation.

Case details

A 41 year old gentleman presented to our tertiary health centre with symptoms of snoring, disturbed sleep, choking spells, daytime sleepiness with foreign body sensation in pharynx for the past 2 months with no comorbidities. He had no history of substance abuse. Body-Mass Index was 24 Kg/m². On examination, a smooth cystic swelling was noted in the right side oropharynx extending from the nasopharynx (Fig. 1 – inset). Diagnostic nasal endoscopy noted that origin of the cyst was from right torus tubarius (Fig. 2). Polysomnography (PSG) showed features of mild obstructive sleep apnea. PSG values were Apnea-Hyponea index (AHI) – 8, Average saturation – 92%, lowest saturation – 86%, snore counts – 557, electromyography was positive showing a probable restless sleep, Thoracic and abdominal efforts were positive. Case rarity was presented to the Institutional Review board and Ethical clearance from the Institutional Review Board (IRB) and Institutional Ethics Committee (IEC) was obtained. Written informed consent was also obtained.

Pure Tone Audiogram showed bilateral normal hearing levels, with Impedance audiogram showing bilateral type 'A' curve. X-ray soft tissue lateral view showed soft tissue mass occupying nasopharynx with no crescent sign. Computed Tomography scan of Paranasal sinuses and nasopharynx was suggestive of lateral cystic mass arising from right torus tubarius (Fig. 1). Angiography showed no vascular lesion. Dynamic Sleep MRI and Drug induced sleep endoscopy (DISE) showed right torus tubarius cyst getting sucked antero-inferiorly and causing OSA. Coblation cyst excision was done

and haemostasis of base was secured. Cyst was excised in toto (Fig. 2 - inset), and content did not show Acid Fast Bacilli and cyst wall on histopathology showed features of simple cyst. On discharge, patient was put on saline nasal douching thrice daily and cefixime 200mg bidaily, both for 5 days.

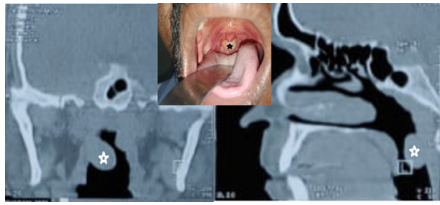


Figure 1. Computerised Tomography image of Torus tubarius cyst (white hollow star). Inset - Clinical picture - cyst marked by black star.

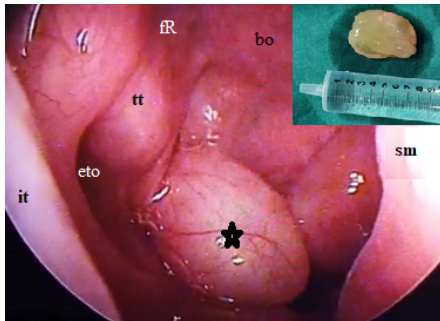


Figure 2. Diagnostic nasal endoscopy showing right torus tubarius cyst (black hollow star). Inset - simple cyst specimen excised in toto. Inferior turbinate (it), eustachian tube orifice (eto), torus tubarius (tt), basioociput (bo), fossa of Rosenmuller (fR), septum (sm)

After extensive Pub Med medline search (Table 1), it was understood that this was the first case report of a torus tubarius cyst. Hence, further case-series studies are required to study the complete etio pathogenesis, clinical manifestations of torus tubarius cysts, and plan comparative studies for management, like cold-steel cyst excision vs coblation.

According to previous studies (Table 1), adenoid hypertrophy with variants like adenoid cysts and abscess were topping the chart in terms of occurrence (40%, n-33) with allergic manifestations of upper airway / polyps coming a close second (19%, n-16). Other common pathologies are dispersed over a spectrum as aforesaid. Craniofacial synostosis was the only category which had been reported with OSA. Features like serous otitis media, headache were the common presenting complaints. Neoplastic lesions in addition had associated Trotter's triad / otalgia. Another interesting feature of the search was that keyword 'torus tubarius' yielded 79 items while a variant 'torus tubaris' yielded 4, a total of 83 reports in PubMed. The dual usage of the term torus may have possible isolated case reports which are less likely to be indexed. A deeper search could highlight the actual incidence of such nasopharyngeal pathologies.

Table 1. Documented nasopharyngeal pathologies with occurrence (%), n). PubMed search.

Sr. No.	Nasopharyngeal pathologies (n=83)	Presentation	Occurrence % (n)
1	Adenoid hypertrophy / cysts / abscess	Serous otitis media	40 (33)
2	Allergic inflammation of upper airway / polyps	Serous otitis media	19 (16)
3	Isolated sphenoid pyocoele with Thornwaldt's cyst	headache	1 (1)
4	Torus tubaris calcification / tubal tonsillar hypertrophy	Serous otitis media	2.5 (2)
5	Torus tubaris mucopyocoele	headache	1 (1)
6	Aberrant Carotid artery	headache	4 (3)
7	Craniofacial synostosis	Serous otitis media / Obstructive sleep apnea	10 (8)

8	Nasopharyngeal Neoplasms	Primary Extranodal mantle cell lymphoma	Serous otitis media / Trotter's triad / headache / otalgia	1 (1)
9		Clival Chondroma / Chondrosarcoma		4 (3)
10		Neurilemmoma		1 (1)
11		Pleomorphic adenoma - Minor salivary glands		2.5 (2)
12		Nasopharyngeal Carcinoma		11 (9)
13		Rhabdomyoma		1 (1)
14		Angiofibroma		1 (1)
15		Lipoma		1 (1)
Total				100 (83)

CONCLUSION:

Torus tubarius cyst of simple cyst variety is a very rare entity. Rarer was its presentation as OSA. Coblation excision was effective as post-surgical edema and scarring were minimal and no velopharyngeal insufficiency was reported. On follow-up, the patient was very much satisfied with resolution of his complaint and the quality-of-life he regained after OSA treatment. Therefore, Incidental nasopharyngeal abnormalities, may be clinically significant and warrant further evaluation and treatment. This being the first report of simple cyst is likely to open up a new avenue of research on nasopharyngeal pathologies.

Conflict of interest: None to declare.

REFERENCES:

- Dickens C. The posthumous papers of the Pickwick club. London: Chapman & Hall; 1836.
- Thorpy M. Historical perspective on sleep and man. In: Culebras A, editor. Sleep disorders and neurological disease. New York: Marcel Dekker; 2000. p. 1-36.
- Guilleminault C, Tikian A, Dement WC. The sleep apnea syndromes. Annu Rev Med. 1976;27:465-84.
- Mukherji SK. Pharynx. In: Som PM, Curtin HD, editors. Head and neck imaging. 4. St. Louis: Mosby; 2003. pp. 1507-1509.
- Ben Salem D, Duvillard C, Assous D, Ballester M, Krausé D, Ricolfi F. Imaging of nasopharyngeal cysts and bursae. Eur Radiol. 2006;16(10):2249-2258.
- Ali MY. Pathogenesis of cysts and crypts in the nasopharynx. J Laryngol Otol. 1965;79:391-402.
- Nicolai P, Luzzago F, Maroldi R, Falchetti M, Antonelli AR. Nasopharyngeal cysts. Report of seven cases with review of the literature. Arch Otolaryngol Head Neck Surg. 1989;115:860-864.
- Sekiya K, Watanabe M, Nadgir RN, et al. Nasopharyngeal cystic lesions: Torwaldt and mucous retention cysts of the nasopharynx: findings on MR imaging. J Comput Assist Tomogr. 2014;38(1):9-13.
- Little JW, Rickles NH. The histogenesis of the branchial cyst. Am J Pathol. 1967;50:533-547.
- Guggenheim P. Cysts of the nasopharynx. Laryngoscope. 1967;77:2147-2168.
- Ben Salem D, Duvillard C, Assous D, Ballester M, Krausé D, Ricolfi F. Imaging of nasopharyngeal cysts and bursae. Eur Radiol. 2006;16:2249-2258.
- Verma A, Sohail MA, al-Khabori M, Moosa M. Nasopharyngeal cyst of branchiogenic origin: report of a case and review of the literature. Ear Nose Throat J. 2000;79:722-724, 726, 730-731.
- Tsai TY, Su CY. Surgical technique of transoral marsupialization for the treatment of nasopharyngeal branchial cysts. Ann Otol Rhinol Laryngol. 2010;119:336-341.
- Miyahara H, Matsunaga T. Thornwaldt's disease. Acta Otolaryngol Suppl. 1994;517:36-39.
- Eloy P, Watelet JB, Hatert AS, Bertrand B. Thornwaldt's cyst and surgery with powered instrumentation. B-ENT. 2006;2(3):135-139.