



CORRELATION BETWEEN ENDOSCOPIC AND HISTOPATHOLOGICAL FINDINGS IN GASTRIC LESIONS.

Pathology

Amarnath Kumar Nayak Post Graduate Student, Department of Pathology, Rajendra Institute of Medical Sciences (RIMS), Ranchi, Jharkhand.

Ratna Choudhary* MBBS, M.D. (Patho.), Professor, Department of Pathology, Rajendra Institute of Medical Sciences (RIMS), Ranchi, Jharkhand. *Corresponding Author

Nisha Kumari Post Graduate Student, Department of Pathology, Rajendra Institute of Medical Sciences (RIMS), Ranchi, Jharkhand

ABSTRACT

Background: Stomach is a common site for wide variety of lesions. The visualisation of the site with endoscopy and its biopsy leads to the early detection of the pathological process and appropriate therapy.

Objectives: The objective of this study is to correlate the histopathological pattern of endoscopic biopsies with distribution of gastric lesions according to age and sex.

Method: The study was carried out among 100 cases with endoscopic biopsies and histological assessment, received at Department of pathology, Rajendra Institute of Medical Science, Ranchi.

Result: Out of 100 cases majority of cases were male gender with male : female ratio was 2.1:1. Our study showed a poor correlation between endoscopic and histopathologic evidence of inflammation of the stomach. Five cases were diagnosed as intestinal metaplasia which were diagnosed as intestinal metaplasia which were diagnosed endoscopically as ulcer and erosion. Out of 34 cases diagnosed endoscopically as ulcer, only 4 cases were confirmed histologically. Our study showed good correlation in the cases of carcinoma. Out of 32 cases diagnosed endoscopically as gastric carcinoma correlated histologically as gastric adenocarcinoma. Majority of carcinoma cases showed ulcerating fungating growth followed by ulcero-proliferative growth.

Conclusion: Endoscopy is incomplete without biopsy and histopathology. Histopathology is the gold standard for the diagnosis of endoscopically detected lesions. Endoscopic examination and histopathological examination of suspected gastric lesions should go parallel and neither should be a substitute of each other.

KEYWORDS

Carcinoma, endoscopy, helicobacter pylori, histopathology

INTRODUCTION

Human gastrointestinal tract which is long and tortuous is an important site for wide variety of lesions which includes congenital, inflammatory and neoplastic conditions. To facilitate diagnosis of different lesions, endoscopy and histological examination are complementary.

Histopathological study of biopsy specimens are used to confirm endoscopic diagnosis in suspected malignancy or to rule out in endoscopically benign appearing lesions and also are performed for monitoring the course, determining the extent of a disease as response to therapy and for the early detection of complications. The aim of this study is to correlate the histopathological pattern of endoscopic biopsy with distribution of gastric lesions according to age and sex.

METHODS

Source of data

The study was done in pathology department of Rajendra Institute of Medical Sciences, Ranchi, Jharkhand in collaboration with Department of Surgery, RIMS, Ranchi, Jharkhand.

Collection of data

Biopsies were fixed in 10% formalin and histopathological slides were prepared for staining with Hematoxyline and Eosin, Geimsa and Immunohistochemical methods using paraffin block.

Inclusion criteria

The study included all endoscopic biopsies which were done for various chronic upper abdominal pain, dyspepsia, hurtburn, nausea, vomiting and for associated systemic manifestations like anorexia, weight loss. Irrespective of age and sex.

Exclusion criteria

Inadequate specimen and autolysed specimens

Study period

2 year from September 2017 to August 2019

Number of cases

A total number of 100 patients with gastric lesion.

METHODS:

Staining technique

H&E stained sections of all the cases were reviewed. All endoscopic gastric mucosal biopsies taken from different sites were brought in 10% buffered formalin and were oriented with submucosa embedded downwards. After overnight fixation in formalin, dehydration done with graded alcohol, clearing in chloroform followed by paraffin embedding and section cutting in rotatory microtome. Sections of 3 to 5 micrometre thickness will be made & stained with H&E, Giemsa and immunohistochemical staining. All the sections were reported by pathologist. Data was collected and analyzed for frequency, percentages and results were presented through table.

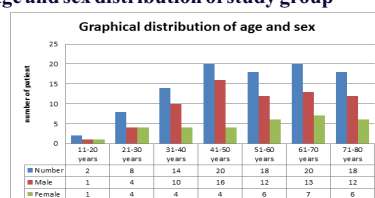
RESULT

Among the 100 cases, 68 were male and 32 were females. Patient with gastric lesions in the study ranged from 13 years to 76 years. Age and Sex distribution of the study groups were Table 1 and Graph 1.

Table 1: Age and Sex distribution of study group

Age(years)	Number	Male	Female
11-20	02	01	01
21-30	08	05	03
31-40	14	09	05
41-50	20	16	04
51-60	18	12	06
61-70	20	13	07
71-80	18	12	06
Total	100	68 (68%)	32 (32%)

Graph 1: Age and sex distribution of study group



Out of 10 cases, of erythematous patches diagnosed endoscopically, 2 cases (20%) were found to be normal, 4 cases (40%) were as chronic gastritis and 4 cases(40%) were diagnosed Helicobacter pylori induced gastritis. Out of 32 cases which were diagnosed as gastric ulcer endoscopically, 4 cases (12.5%) were found to be normal, 12 cases (37.5%) were diagnosed as chronic gastritis, 8 cases (25%) were diagnosed as Helicobacter pylori induced gastritis, 4 cases (12.5%) diagnosed as ulcer, 2 cases (6.25%) each of metaplasia and carcinoma. Similarly 26 cases diagnosed as erosion endoscopically, 8(31%) cases were found normal, 10(38.5%) cases were diagnosed as chronic gastritis, 2(7.5%) cases were diagnosed as metaplasia and 6 (23%)cases were diagnosed as Helicobacter pylori induced gastritis

Table 2: correlation between endoscopic and histopathological diagnosis

Endoscopic diagnosis	Histological diagnosis						Total
	Normal study	Ulcer	Chronic gastritis	Metaplasia	Carcinoma	H.pylori induced gastritis	
Erythema	2	-	4	-	-	4	10
Ulcer	4	4	12	2	2	8	32
Erosion	8	-	10	2	-	6	26
Growth	-	-	-	-	32	-	32
Total	14	4	26	4	34	18	100

However , all 32 of the endoscopically suspected carcinoma correlated histologically as adenocarcinoma, majority of carcinoma correlated histologically as adenocarcinoma, majority of carcinoma presented as an ulcerating fungating growth on endoscopy. (Table-3)

Table3. Endoscopic and histopathological findings of gastric carcinoma.

Endoscopic findings	Adenocarcinoma
Ulcerating fungating growth	12
Ulcer – proliferative growth	10
Friable growth	06
Nodular ulceration	04
Total	32

DISCUSSION

The biopsy sampling of the gastric mucosa at diagnostic endoscopy provides useful information which helps in the diagnosis of various lesions. The study aimed toward finding a strong endoscopic and histological correlation of gastric lesions.

In our study majority of cases were of male. This gender ratio favouring males could be reflecting of the fact that males are exposed to more risk factors than females. Biopsies from each area with endoscopic diagnostic feature such as erythema, ulcer, erosions were examined to assess possible histological counterparts to these endoscopic findings. The severity of inflammation presence or absence of inflammatory cells, epithelial damage were compared. There was poor correlation between endoscopic and histological evidence of inflammation in the stomach. Out of 32 cases diagnosed endoscopically as ulcer only four were diagnosed histologically. In our study gastritis was the most commonly diagnosed histologically, it includes both chronic gastritis and H.pylori induced gastritis. Previous studies have also shown variation in results. This can be due to study conduct on different population and varying results of endoscopic finding, and histological findings, misinterpretations during endoscopic examination, misinterpretations by histopathologist, sampling error between the actual site biopsied and endoscopic abnormality. These all findings emphasized that the diagnosis of ulcer or gastritis should based on histopathological examination of gastric mucosa.

In our study four cases were found to have as intestinal metaplasia which were diagnosed as ulcer and erosion endoscopically. Intestinal metaplasia are premalignant gastric lesions and histopathological diagnosis of these lesions could be helpful to describe a group at risk for gastric cancer. Our study showed good correlation in the cases of carcinoma. Out of 32 cases diagnosed endoscopically as gastric carcinoma correlated histologically as gastric adenocarcinoma. These findings recommended endoscopy and biopsy as valuable diagnostic procedure among patients suspected gastric carcinoma. Used together they can eliminate the necessity for diagnostic laparotomy. Majority of carcinoma cases showed ulcerating fungating growth followed by ulcero-proliferative growth. Study with similar findings have also been reported. In our study there was increase of incidence of carcinoma

with increase of age.

Limitation of this study are the sampling errors and misinterpretation of endoscopic findings.

CONCLUSION

It was observed that endoscopic diagnosis of benign gastric lesions poorly correlated with those of histopathological diagnosis. Hence care should be taken for processing of the tissue and interpretation by the pathologist. Endoscopy is incomplete without biopsy and histopathology is the gold standard for the diagnosis of endoscopically detected lesions. Endoscopic examination and histopathological examination of suspected gastric lesions should go parallel and neither should substitute of each other.

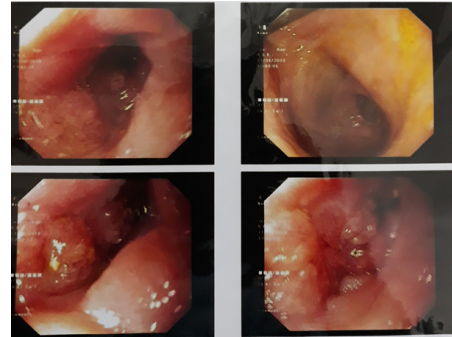


Fig 1:- Upper G.I endoscopy shows growth and ulceration seen in antrum and gastric outlet

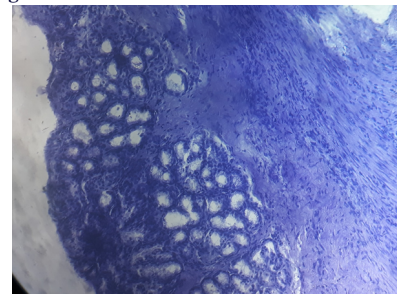


Fig 2:- Normal mucosal glands of stomach along with fibrocollagenous tissue (10x) H&E

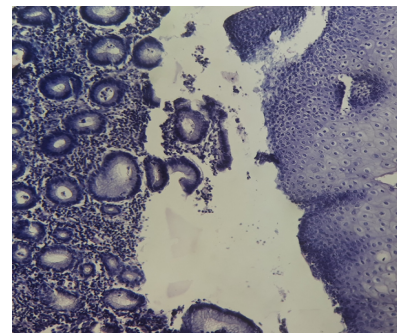


Fig 3 :- Chronic gastritis (10x) H&E

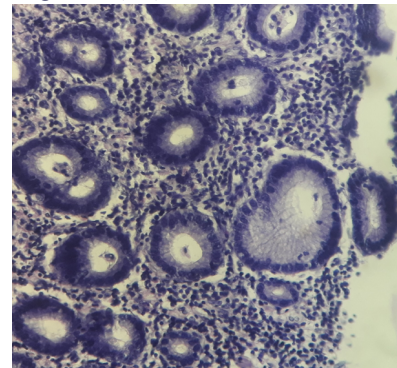


Fig 4 :- Chronic gastritis (40x) H&E

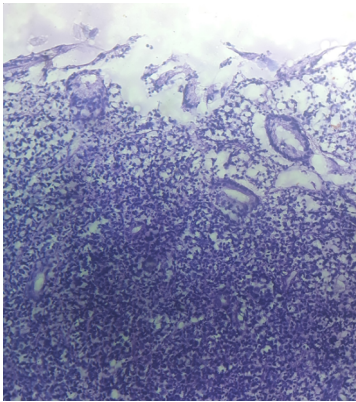


Fig 5:- Poorly differentiated adenocarcinoma (10x) H&E

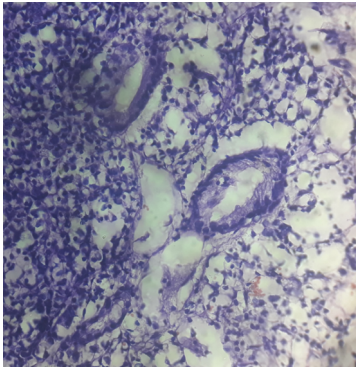


Fig 6:- Poorly differentiated adenocarcinoma (40x) H&E

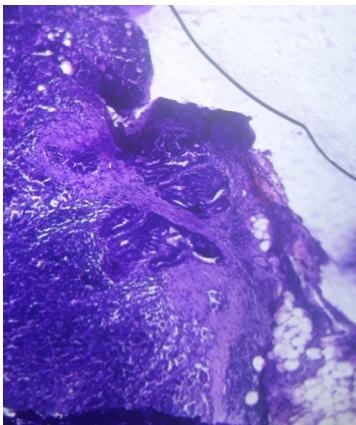


Fig 7:- Adenocarcinoma stomach (10x) H&E

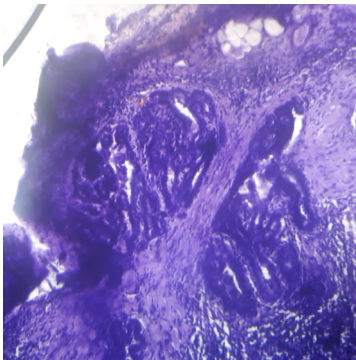


Fig 8 :- carcinoma stomach (40x) H&E

REFERENCES

1. Ofmann JJ, Shaheen NJ, Desai AA, The quality of care in berrett's esophagus: Endoscopist and pathologist practices, *AmJ Gastroenterol.* 2001;96:876-81.
2. McBroom HM, Ramsay AD. The clinicopathological meeting: A means of auditing diagnostic performance. *Am J Surg Pathol.* 1993;17:75-80.
3. Dacosta RS, Wilson BC, Marcon NE. New optical technologies for earlier endoscopic diagnosis of premalignant gastrointestinal lesions. *J Gastroenterol*

4. Hepatol. 2002;17:S18-S105.
5. Hopkins HH. Optical principles of endoscope. In: Berci G, ed *Endoscopy.* 2nd ed. New York: Appleton century grafts, 1976:3-26.
6. Versalovic J. *Helicobacter pylori: Pathology and Diagnostic Strategies.* Am J.Clin. Pathol 2003; 119:403-12.
7. Vartanian RK, Leung JK et al. A novel Alcian yellow- toluidine blue stain for *Helicobacter* species: comparison with standard stains, a cost effectiveness analysis and supplemental utilities. *Mod Pathol* 1998; 11-728.
8. Rao DN, Desai PB, Epidemiological observation of cancer of the esophagus-A review of Indian studies. *IJ of cancer* 1996;33:55-75.
9. Marson BC, Dawson IMP IN: *Gastrointestinal Pathology.* 2nd ed.London: black Well scientific publication;1998.148-51.
10. Dooley C.P. Background and historical considerations of *Helicobacter pylori.* *Gastroenterology Clinics of North America*1993;22:2-4.
11. Blaster M.J. *Helicobacter pylori* and the pathogenesis of gastroduodenal inflammation. *J of Inf Diseases* 1990' 161:626-33.
12. Shennak MM, Tarawneh MS, Upper gastrointestinal diseases in symptomatic Jordanians: A prospective endoscopic study. *Ann Saudi Med* 1997;17(4):4711-14.
13. Paymaster JC, Sanghvi LD, Cancer of gastrointestinal tract in western India. *Cancer* 1968;21:279-87.
14. Mckenna BJ, Appleman HD. Histopathology for the clinician how to interpret biopsy information for gastritis. *Gastroenterol Haptol.*2006;3:165-71.
15. Dyspepsia at Taber's Medical Dictionary.20th ed. Philadelphia: F.a. Davis Company; 2005. Dyspepsia: p-651.
16. Rosai J. Rosai and Ackerman's surgical pathology 10th ed. Milan: Elsevier; 2011 volume 1; chapter 11, gastrointestinal tract; p.615-16.
17. Tally NJ, Vakil NB, Moayyedi P. American Gastroenterological Association technical review: evaluation of dyspepsia. *Gastroenterology* 2005;129:1756-1780.
18. Owen DA. Stomach. In : Mills SE, ed. *Histology for pathologists,* ed.3. Philadelphia: Lippincott Williams and Wilkins;2007:589-602.
19. Levy N, Stermer E, Accuracy of endoscopy in the diagnosis of inflamed gastric and duodenal mucosa; *sr JMed Sci* 1985 jul; 21(7):564-8.
20. Joo YE, Park HK. Prevalence and risk factors of atrophic gastritis and intestinal metaplasia: a nationwide multicentre prospective study in Korea. *Gut liver:* 2013(3):303-10.
21. Cotton PB, Price AB et al. Preliminary evaluation of duodenitis by endoscopy and biopsy, *Br Med J* 1973;3:430-3.
22. Calabrese C et al. Correlation between endoscopic features of gastric antrum, histology and *Helicobacter pylori* infections in adult It al *J Gastro Hepto* 1999; 31(5):359-365.
23. Hecker R, Fitch R. the value of endoscopic and biopsy in the diagnosis of gastric carcinoma. *Med J Aust.*1975 Sep20 ;2(12):472-4.
24. Pallor K, Sarpangala MK. Histopathological diagnosis of gastric biopsies in correlation with endoscopy. A study in a tertiary care center. *Adv lab Med Int* 2012;3(2):22-31.
25. Qizibash AH, Stevenson GW. Early gastric cancer in: *pathology Annals.* New York: Appleton-Century-Crofts;1979:14-24.
26. Lim KC, Tan HK, Rajnakova A, Venkatesh SK. Eosinophilic Gastroenteritis. *Annals Academy of Medicine.* 2011 Aug, 40(8).