ORIGINAL RESEARCH PAPER

Volume-8 | Issue-10 | October - 2019 | PRINT ISSN No. 2277 - 8179 | DOI : 10.36106/ijsr

INTERNATIONAL JOURNAL OF SCIENTIFIC RESEARCH

HISTIOCYTIC SARCOMA OF THE SMALL INTESTINE: A CASE REPORT WITH REVIEW OF THE LITERATURE

Pathology

Keun Joo Ryu, Kyu Sang Song*

MD and PhD, Department of Pathology, School of Medicine, Graduate School, Chungnam, National University *Corresponding Author

ABSTRACT

Histiocytic sarcoma is very rare malignant neoplasm showing morphological and immunophenotypic characteristics of histiocyte. Morphologic diagnosis is challenging due to overlapping histologic features with diverse mimics. Histologic diagnosis is confirmed by expression of one or more histiocytic markers, including CD163, CD68, and lysozyme. We present a bona fida case of extranodal histiocytic sarcoma involving the small intestine in a 67-year-old male. The diagnosis is confirmed by diffuse immunoreactivity of CD163, which is believed to be more specific histiocytic marker than CD68.

KEYWORDS

Histiocytic sarcoma, small intestine, CD163

INTRODUCTION

Histiocytic sarcoma(HS) is a malignant proliferation of cells showing morphological and immunophenotypic features of mature tissue histiocytes(1). It is an exceedingly rare neoplasm, accounting for less than 1% of all hematolymphoid neoplasms, with only limited numbers of reported series of *bona fide* cases(1)(2). Lymph nodes are the most common site of presentation, although a variety of extranodal sites are affected including the gastrointestinal tract, soft tissue and skin(3). HS presents with a wide age distribution and occurs principally in adults with slight male predominance(1)(2)(3).

Morphologic diagnosis of HS is difficult because of its rarity and histologic overlap with diverse mimics. According to WHO, one or more histiocytic markers, among CD163,CD68, and lysozyme, should be expressed, with typical absence of Langerhan cell (CD1a, langerin), follicular dendritic(CD21, CD35), and myeloid markers(CD13, MPO)(1).

Recently, several authors have reported that CD163 may be a more specific than other monocytic/histiocytic markers such as CD68(4)(5)(6).

Since the introduction of CD163, true HSs verified by CD163 immunostain are very few.

Herein, we present a CD163 positive, *bona fide* case of HS involving the small intestine in a 67-year old male patient.

CASE REPORT

A 67-year-old male presented to the hospital due to diarrhea and lower abdominal pain for one month. A peripheral blood count revealed anemia(hemoglobin level; 6.6g/dl). Other laboratory tests including serum tumor markers (CEA and CA 19-9) were all within normal limit. Abdominopelvic CT showed a 10cm sized, heterogeneously enhancing mass with central necrosis in the small intestine. Radiologic diffential diagnosis was suggestive of malignant lymphoma or malignant gastrointestinal stromal tumor. He was underwent the segmental resection of the small intestine(jejunoileum). The specimen was a 65cm long small intestine with a relatively circumscribed mass which measured 9.5x9.0x5.5cm and had a central ulcer. The cut surface was grayish white and showed diffuse hemorrhagic necrosis.

Microscopically, the tumor showed a diffusely discohesive architecture with diffuse hemorrhagic necrosis, involving the intestinal wall. The neoplastic cells were large and polygonal with abundant eosinophilic cytoplasm. The nuclei were round to oval or folded, with vesicular chromatin, and had one or two prominent nucleoli with notable pleomorphism.

Mitotic figures were increased up to 20/10 high power field with a few scattered atypical forms. A small number of lymphoplasma cells were focally observed, but eosinophils were not encountered. Multinucleated giant cells were scattered however, hemophagocytosis was not encountered.

Immunohistochemically, tumor cells were diffusely positive for CD163 and CD68. CD45 was weakly and focally positive and lysozyme negative. Other immunophenotypic panels for differential diagnosis showed all negative reactions. Those were C-kit, alpha SMA, CD5, CD20, CD21, CD30, CD35, MPO, HMB-45, Melan-A, EMA, cytokeratin, S100 protein, CD1a, and langer in. Ki-67 labeling index was approximately 40%. Thus, the final diagnosis of HS was made. One month after diagnosis, PET/CT scan revealed a small hot uptake lesion in the right lower lung and both parotid glands, respectively. A needle biopsy from the lung exhibited similar pathologic features as those of the small intestine. Both parotid lesions were not biopsied. Patient did not want additional treatment such as adjuvant chemotherapy and radiation. This case study was approved by the Institutional Review Board of Chungnam National University Hospital with a waiver of informed consent (IRB No : 2018-03-004).

Figure 1. APCT shows large tumor mass in the small intestine with cavity formation

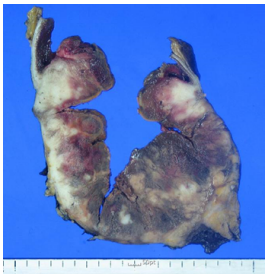

Figure 2. Cut surface of mass is grayish white with diffuse hemorrhagic necrosis

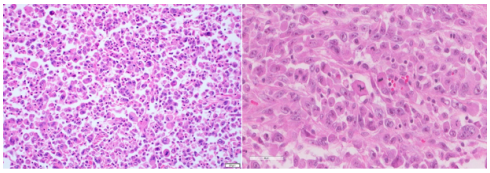

Figure 3. (Left) Photomicrograph showing discohesive pleomorphic tumor cells with abundant eosinophilic cytoplasm. Hematoxylin and eosin, x200. (Right) High power view showing round to oval, occasionally lobulated nuclei with one or two prominent nucleoli, frequent mitosis with atypical form(center), and multinucleated giant cells(right lower corner) Hematoxylin and eosin, x400

Submitted : 27th June, 2019 | Accepted : 04th September, 2019 | Publication : 01st October, 2019

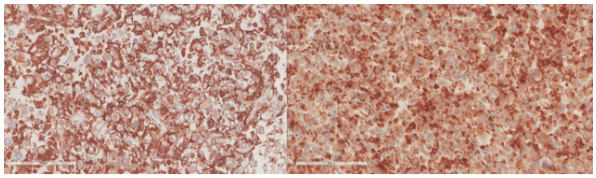

Figure 4. Immunohistochemical stains for CD163(left) and CD68(right) reveal diffuse cytoplasmic staining of tumor cells. x200..

DISCUSSION

Mathe et al. were the first to introduce the term histiocytic sarcoma in 1970 for tumors with histologic similarities to macrophages(7). They described a collection of malignant neoplastic cells with histologic features of large macrophages with abundant eosinophilic cytoplasm.

Before the widespread use of immunohistochemistry many published cases were likely misdiagnosed examples of non-Hodgkin lymphoma. It is now generally recognized that most of such cases described in the past in fact represent examples of diffuse large B-cell lymphoma (DLBCL) and anaplastic large cell lymphoma (ALCL)(8)(9). In this context, Hornick JL et al. insist that it is difficult to interpret reports published in the past(2).

HS is a diagnosis of exclusion. The diagnosis of HS requires the verification of histiocytic lineage and exclusion of malignancies of other lymphohematopoietic lineages with extensive immunophenotypic workup including histiocytic markers such as CD68, lysozyme. However, these markers are not always specific for histiocytic differentiation.

Recently, several authors have reported that CD163, a hemoglobin scavenger receptor, may be a more specific marker of the monocytic/histiocytic lineage(4)(5)(6)(10).CD163 has been studied in a variety of benign and malignant tissues and shows almost exclusive expression in cells of monocyte/macrophage lineage(10). Nguyen et al. also described that CD163 was largely restricted to the monocyte/macrophage lineage and may have significant diagnostic utility in separating specific tumors with monocytic and histiocytic derivation from other entities in their differential diagnosis(5).

According to Vos JA et al. immunoreactivity of CD163 was essential for differential diagnosis between HS and other mimikers(6). They emphasized that CD163 was a sensitive and apparently restricted marker for identifying lesions of histiocytic lineage and was, therefore, important in the diagnosis of HS.

Our case showed cellular pleomorphism, mimicking large cell lymphoid malignancy, and expressed diffuse immunoreactivity for CD163, thus, finally turned out tumor of true histiocytic lineage.After the reports of Nguyen TT(including 3 cases of HS) and Vos JA(5 cases of HS)(5)(6), only 11 cases of true HSs confirmed by immunoreactivity of CD163 were reported in English literature(11)(12)(13)(14)(15)(16)(17)(18). There were three cases in the small intestine(one case involves both stomach and jejunum simultaneously)(11)(13)(14), one in thyroid gland(12), one in stomach(15), five cases with cutaneous involvement(16), and one in central nervous system(17).

Because of its rarity and morphological similiarity to many other disease entities,the differential diagnosis is broad, including reactive histiocytic proliferation, interdigitating dendritic cell sarcoma, Langerhans cell histocytosis and sarcoma, follicular dendritic cell tumor, myeloid cell sarcoma, diffuse large cell lymphoma, anaplastic large cell lymphoma, malignant melanoma, and undifferentiated carcinoma(1)(2)(3)(18).

The etiology and pathogenesis of HS is unknown(1). So far, there are no distinctive molecular findings specific for HS. However, histiocytic sarcoma cases with preceding B-cell lymphoma and exhibiting transdifferentiation can share molecular aberrations with the B-cell lymphoma(18)(19).

The biologic behavior of histiocytic sarcoma is aggressive with a poor response to therapy. Tumor size and stage are believed to be important factors in the prognosis(1)(2)(3)(6)(18).

Recently, Facchetti et al. reported that one-fourth of cases (3 of 12) showed strong and diffuse PD-L1 expression, suggesting that immunotherapy could potentially be helpful(20).

In summary, we present a CD163 positive,*bona fide* case of HS in the small intestine, morphologically mimicking anaplastic large cell lymphoma. Because of its rarity and morphological similiarity to many other entities, the diagnosis of HS is challenging for pathologists. Full knowledge of key morphologic and immunohistochemical features allows for accurate diagnosis. In particular, CD163 is a helpful marker for histiocytic differentiation because of its increased specificity relative to CD68. Further collection of CD163-positive HS is needed to understand the clinicopathological and phenotypic features of this rare tumor.

REFERENCES

(1) Weiss LM, Pileri SA, Chan JKC, Fletcher CDM. Histiocytic sarcoma. In Swerdlow SH, Campo E, Harris NL, et al, editors. WHO classification of tumours of haematopoeitic and lymphoid tissues, revised 4th ed. Lyon, France:IARC Press; 2017;468-470.
(2) Hornick JL, Jaffe ES, Fletcher CD. Extranodal histiocytic sarcoma:clinicopathologic analysis of 14 cases of a rare epithelioid malignancy. Am J Surg Pathol 2004;28:1133-1144.
(3) Takahashi E, Nakamura S. Histiocytic sarcoma: An updated literature review based on the 2008 WHO classification. J Clin Exp Hematop2013;53(1):1-8.
(4) Lau SK, Chu PG, Weiss LM. CD163: a specific marker of macrophages in paraffin-embedded tissue samples. Am J Clin Pathol 2004;122:794-801.
(5) Nguyen TT, Schwartz EJ, West RB, et al. Expression of CD163 (hemoglobin scavenger receptor) in normal tissues, lymphomas, carcinomas, and sarcomas is largely restricted to the monocyte/macrophage lineage. Am J Surg Pathol 2005;29:617–624.
(6) Vos JA, Abbondanzo SL, Barekman CL, et al. Histiocytic sarcoma: a study of five cases including the histiocyte marker CD163. Mod Pathol 2005;18:693–704.
(7) Mathe G, Gerard-Marchant R, Texier JL, et al. The two varieties of lymphoid tissue 'reticulosarcomas', histiocytic and histioblastic types. Br J Cancer 1970;24: 687–695.
(8) Wilson MS, Weiss LM, Gatter KC, et al. Malignant histiocytosis: a reassessment of cases previously reported in 1975 bases on paraffin section immunophenotyping studies. Cancer 1990;66:530–536.
(9) Arai E, SuWPD, RochePC,et al. Cutaneous histiocytic malignancy: immunohistochemical re-examination of cases previously diagnosed as cutaneous "histiocytic lymphoma" and "malignant histiocytosis." J Cutan Pathol 1993;20:115–120.
(10) Walter RB, Bachli EB, Schaer DJ, et al. Expression of the hemoglobin scavenger receptor (CD163/HbSR) as immunophenotypic marker of monocytic lineage in acute myeloid leukemia. Blood 2003;101:3755–3756.
(11) Zhang X, Kryston JJ, Michalak WA, et al. Histiocytic sarcoma in the small intestine: A case report with flow cytometry study and literature review. Pathol Res Pract 2008;204:763-770.
(12) Yu L, Yang SJ. A Case of Primary Histiocytic Sarcoma Arising from Thyroid Gland. Pathol Oncol Res 2010;16:127-132.
(13) Sundersingh S, Majhi U, Seshadhri RA, Tenali GS. Multifocal histiocytic sarcoma of the gastrointestinal tract. Indian J Pathol Microbiol 2012;55(2):233-235.
(14) Miyazaki T, Arihiro S, Mitobe J, et al. The utility of balloon enteroscopy in the diagnosis of histiocytic sarcoma of the small intestine: A case report. Pathol Int 2013;63:120-124.
(15) Lee D, Kim YB, Chung SH, et al. Primary gastric histiocytic sarcoma reminiscent of inflammatory pseudotumor: A case report with review of the literature. Kor J Pathol 2014; 48:258-262.
(16) Margo CM, Kaze N, Sisinger AE. Primary cutaneous histiocytic sarcoma: A report of five cases with primary cutaneous involvement and review of the literature. Ann Diagn Pathol 2018;32:56-62.
(17) Ma S, Schild M, Tran D, et al. Primary central nervous system histiocytic sarcoma: A case report and review of literature. Medicine(Baltimore)2018;97(26):e11271. doi:10.1097/MD.0000000000011271.
(18) Skala SL, Lucas DR, Dewar R. Histiocytic sarcoma: review, discussion of transformation from B-cell lymphoma, and differential diagnosis. Arch Pathol Lab Med 2018;142:1322-1329.
(19) Wang E, Hutchinson CB, Huang Q, et al. Histiocytic sarcoma arising in indolent small B-cell lymphoma: report of two cases with molecular/genetic evidence suggestive of a "transdifferentiation" during the clonal evolution. Leuk Lymphoma 2019;51(5):802-812.
(20) Facchetti F, Pileri SA, Lorenzi L, et al. Histiocytic and dendritic cell neoplasms: what have we learnt by studying 67 cases. Virchows Arch 2017; 471(4):467–489.