



ROLE OF ULTRASONOGRAPHY AND COMPUTED TOMOGRAPHY IN DIAGNOSIS OF PANCREATITIS

Radiodiagnosis

Dr. Jainex Patel* Resident Doctor, Department of Radiodiagnosis & Imaging, New Civil Hospital, Surat.
*Corresponding Author

Dr. Purvi Desai Associate Professor, Department of Radiodiagnosis & Imaging, New Civil Hospital, Surat

ABSTRACT

Acute pancreatitis or acute pancreatic necrosis is a sudden inflammation of the pancreas. It can have severe complications and high mortality despite treatment. Chronic pancreatitis represents the end result of a continuous, prolonged, inflammatory and fibrosing process that affects the pancreas. This results in irreversible morphologic changes and permanent endocrine and exocrine pancreatic dysfunction. USG and CT scan plays crucial role in diagnosing and assessing the severity of pancreatitis.

KEYWORDS

Acute pancreatitis, Chronic pancreatitis, Pancreatic Pseudocyst, Ultrasonography, Computed Tomography

INTRODUCTION:

This study focuses on USG & CT Scan imaging modalities and on their application in the evaluation of inflammatory lesions of the pancreas. It also deals with the relative advantages of one over the other. The various findings as imaged by both these modalities are studied. The cases were examined by CT or ultrasonography and, in some cases, by both modalities to arrive at conclusion. Results obtained from the study are concluded at the end of the paper.

METHODOLOGY:

A total of 55 cases were studied. Out of which 45 had acute pancreatitis and 10 had chronic pancreatitis. In the 45 cases with acute pancreatitis, ultrasound alone was done in 20 cases, CT alone in 4 cases. Both modalities were employed in the remaining 21 patients. All the 10 cases with chronic pancreatitis had an ultrasound study but only one required a CT scan.

CT scans were performed in supine position in a '16-SLICE TOSHIBA AQUILION LIGHTNING' CT machine in suspended inspiration using a kVp of 130 and mAs of 100. The window width was set between 1200-1500.

USG was performed on 'PHILIPS AFFINITY USG MACHINE', using convex probe for anatomy evaluation of pancreas and flat probe for pancreatic echotexture study. Pancreas was evaluated in terms of size, shape, echotexture, density and contrast enhancement pattern. Any intrapancreatic or peripancreatic fluid collection, peripancreatic fat edema and necrosis was studied.

RESULT:

Ultrasonography is non-invasive, quick, inexpensive widely available and a safe tool in the imaging and diagnosis of pancreatitis. It has certain limitation due to bowel gas the pancreas may not be visualized. Extra pancreatic spread of inflammation and vascular complications may not be picked up by Ultrasonography. These limitations are overcome with the use of CT which yields more diagnostic information in the evaluation of both acute and chronic pancreatitis. Ultrasonography is the initial investigation. Enlargement, altered echogenicity, surrounding oedema are suggestive of acute pancreatitis, whereas, calcification, ductal dilatation and atrophy are suggestive of chronic pancreatitis. CT is a confirmative investigation in diagnosis and staging of Acute or Chronic pancreatitis.

DISCUSSION:

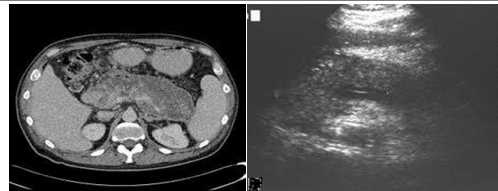
Acute Pancreatitis: Ultrasonography is indicated early in an acute episode of pancreatitis, to help evaluate the presence of gall bladder and / or common bile duct stones. It has limited applications in the early staging of the disease. Abnormal ultrasound findings are seen in 33 to 90% of patients with acute pancreatitis.

The most important contribution on CT is the detection of the primary cause of the inflammatory process so that remedial steps can be taken.

Table 1: Modified CT Severity Index in Acute Pancreatitis

Pancreatic Inflammation	Pancreatic Necrosis	Extrapaneacetic Complications
-------------------------	---------------------	-------------------------------

0: Normal pancreas	0:None	2: One or more of pleural effusion, ascites, vascular complications, parenchymal complications and/or gastrointestinal involvement
2: Intrinsic pancreatic abnormality with or without inflammatory changes in peripancreatic fat	2:<30%	
4: Pancreatic or peripancreatic fluid collection or peripancreatic fat necrosis	4:>30%	
Total score: 0-2: Mild, 4-6: Moderate, 8-10: Severe		

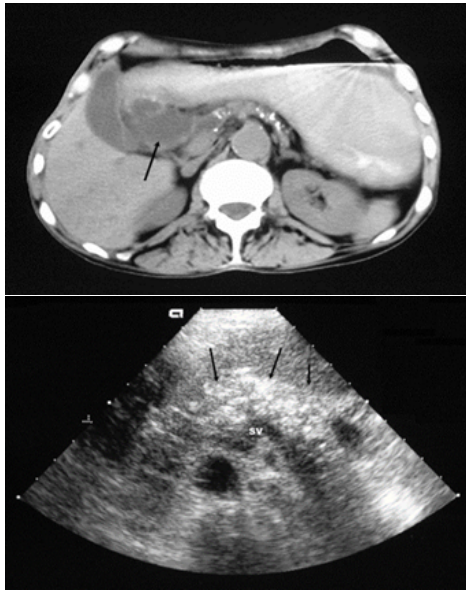


Chronic Pancreatitis:

Serum amylase and lipase levels are usually normal. Elevation of serum bilirubin and alkaline phosphatase levels may indicate cholestasis secondary to chronic inflammation around the common bile duct. Radioimaging: Scattered calcifications throughout the pancreas may be seen. ERCP reveals dilatation or multifocal stenosis of the main pancreatic duct and its lateral side branches, intraductal filling defect (protein plugs) and areas of calcifications, and narrowing of intrapancreatic portion of common bile duct.

Table 2: Cambridge Classification of Chronic Pancreatitis

Pancreatic changes	ERP	CT & USG
Normal	MPD normal, no abnormal lateral side branches (LSB)	MPD not more than 2mm in diameter, normal gland size and shape, homogenous parenchyma
Equivocal	MPD normal, <3 abnormal LSB	Only one of the following signs: MPD 2-4 mm in diameter, gland enlarged (<2 times normal), heterogenous parenchyma
Mild	MPD normal, >3 abnormal LSB	Two or more signs: MPD 2-4 mm in diameter, slight gland enlargement, heterogenous parenchyma, Small cavity (<10 mm)
Moderate	MPD and LSB abnormal.	MPD irregularity, focal acute pancreatitis, Increased echogenicity of MPD walls, Gland contour irregularity
Severe	Any of the above changes plus one or more of the following: Cavity >10 mm in diameter, Intraductal filling defect, Calculi, MPD obstruction or stricture, Severe MPD irregularity, Contiguous organ involvement	



Images 3 & 4: 3 showing plain CT with calcification in chronic pancreatitis with pseudocyst formation. 4 showing echogenic foci in chronic pancreatitis on USG

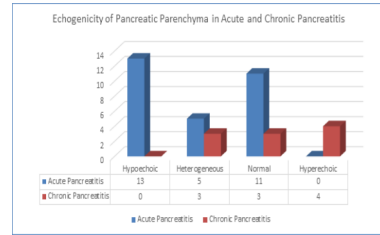


Chart 2: Echogenicity of Pancreatic Parenchyma in Acute and Chronic Pancreatitis

REFERENCES:

1. Alpem M.B., M.A. Sandier, G.M. Keilman, and B.L. Madrazo, 1985 - Chronic pancreatitis: ultrasonic features Radiology, 155:215
2. Chopra S., P Joshi, S.K. Kochhar, G Balarangaiah, - Pictorial assay: CT Spectrum of pancreatitis- An overview md RadiolImag 1997; 7 (2): 9 1-Baithazar E.J, Robinson D.L., Megibon A.J., Ramson J.H.C. - Acute pancreatitis value of CT in establishing prognosis. Radiology 1990; 174: 33 1-336
3. Balthzar E.J RSNA 2002 - Acute pancreatitis: assessment of severity with clinical and CT evaluation Radiology 2002; 223: 603
4. Balthzar E.J, - Staging of acute pancreatitis RadiolClin N Am 2002; 40: 1199-1209
5. Balthzar E.J - Complication of acute pancreatitis clinical and CT evaluation RadiolClinNAm 2002; 40: 1211-1227.
6. Bannister L.H - Alimentary system, chapter 12 in Gray's anatomy.william's P.L et al Ed. Edinurgh: E LBS Churchill Livingstone, 2005; 123 1-1237.
7. Bolondi L, S Li Bassi, S. Galani, L Barbara. —Sonography of chronic pancreatitis RadiolClin North Am 1989; 27 (4): 8 15-833
8. Filly R.A, A.K. Freimants. - Echographic Diagnosis of pancreatitis Lesions ultrasound Scanning Techniques and Diagnostic Findings Radiology 1970; 96: 5 75-5 82
9. Baithazar E.J, Robinson D.L., Megibon A.J., Ramson J.H.C. - Acute pancreatitis value of CT in establishing prognosis. Radiology 1990; 174: 33 1-336

SUMMARY:

Ultrasonography is non-invasive, quick, inexpensive widely available and a safe tool in the imaging and diagnosis of pancreatitis. It has certain limitation due to bowel gas the pancreas may not be visualized. Extra pancreatic spread of inflammation and vascular complications may not be picked up by Ultrasonography. These limitations are overcome with the use of CT which yields more diagnostic information in the evaluation of both acute and chronic pancreatitis.

Alcohol forms a major cause of pancreatitis. Pain abdomen in epigastrium is main complaint in pancreatitis. Ultrasonography is the initial investigation. Enlargement, altered echogenicity, surrounding edema are suggestive of acute pancreatitis, whereas, calcification, ductal dilatation and atrophy are suggestive of chronic pancreatitis.

CT is a confirmative investigation in diagnosis and staging of Acute or Chronic pancreatitis.

CONCLUSION:

Maximum number of cases was between 16 to 62 years of age. Pain abdomen in the epigastrium and periumbilical region radiating to the back, nausea and vomiting were the most frequent presenting complaints. Ultrasonography visualized pancreas on about 70% patients whereas CT visualized pancreas in 100% patients. Alteration in the size and echogenicity were the most common ultrasonography findings. Bulky hypoechoic pancreas was considered diagnostic of acute pancreatitis on ultrasonography. Duct dilatation and calcification were seen in chronic pancreatitis on ultrasonography.

Ultrasonography has a PPV of 100% and Sensitivity of 59% in patients in whom pancreas were visualized. CT visualized pancreas in all patients. Estimation of size and detection of calcification were diagnostic of pancreatitis. Extra pancreatic spread of inflammation was better noted on CT. CT has a PPV of 100% and Sensitivity of 96%.

Thus, it is seen that both Ultrasonography and CT have roles to play in the diagnosis of pancreatitis and both are complementary to each other.

Chart 1: Size Distribution of Pancreas in Acute and Chronic Pancreatitis

