



FUNCTIONAL OUTCOME IN DISTAL TIBIA FRACTURES TREATED BY DISTAL TIBIA LOCKING PLATE BY MIPPO TECHNIQUE- A PROSPECTIVE STUDY

Orthopaedics

Sandeep Bhide	Assistant Professor, Department of Orthopaedics, RD Gardi Medical College, ujjain, Madhya Pradesh.
Ayush Chauhan	Senior resident, Department of Orthopaedics, RD Gardi Medical College, ujjain, Madhya Pradesh.
Sunil Kumar Dhanger*	D.N.B, Department of Orthopaedics, Artemis hospital, Gurgaon, Haryana. *Corresponding Author

ABSTRACT

Introduction: Distal tibial fractures represent a significant challenge to most of the surgeons even today. They constitute 1-10% of all lower extremity fractures. Surgery is the mainstay of treatment for most tibial fractures caused by high energy trauma. Operative treatment leads to early mobilization, avoids shortening and other complications that occur due to prolonged immobilization. Minimally invasive percutaneous plate osteosynthesis (MIPPO) is a technique which reduces iatrogenic soft tissue trauma and damage to bone vascularity, as well as preserves the fracture hematoma which has osteogenic properties.

Material and Methods: In the present study, we operated 25 patients with extra articular tibia fracture with MIPPO technique with distal tibia medial locking plate over period of two years and the results were analyzed.

Results: At the end of the study of 25 patients treated 14(58.3%) patients had excellent outcome, 6(20.8%) had good results, 4(16.7%) had fair outcome and 1(4.1%) had a poor results.

Fractures of 02 (08%) patients united in 16 weeks, 5(20%) patients united in 18 weeks, 10(40%) patients united in 20 weeks and 08 (32%) patients united in 22 weeks. All cases fibula fracture healed without complications.

Conclusion: Extra articular distal tibia fracture can be effectively treated with MIPO technique using medial distal tibial locking plate.

KEYWORDS

Distal tibia fractures, Distal tibia locking plate, Pilon Fractures, closed fractures, Minimally invasive percutaneous plating.

INTRODUCTION:

Distal tibial fractures represent a significant challenge to most of the surgeons even today. They constitute 1-10% of all lower extremity fractures. There still is a debate regarding the management of fractures of the distal tibia. Non-operative treatment may be associated with joint stiffness in up to 40% of cases as well as rotational malunion and shortening in over 30% of cases. Operative treatment is best suited for most tibial fractures caused by high energy trauma. Operative treatment allows early motion, hence avoiding complications associated with prolonged immobilization'. Conventional ORIF can lead to complications like infection, delayed or non-union due to revitalization of bony fragments and more soft tissues trauma. Intramedullary nails lack stability and external fixators, which are usually applied for primary stabilization until soft tissue swelling get subsided, delays the return to work. Recently, there has been growing use of a Locking compression plate for treatment of fractures of the distal part of the tibia. Compared with a conventional plate, a Locking compression plate provides more stability and imparts better protection against primary and secondary losses of reduction and minimizes bone contact. Minimally invasive percutaneous plate osteosynthesis (MIPPO) is a technique which reduces iatrogenic soft tissue trauma and damage to bone vascularity, as well as preserves the fracture hematoma which has osteogenic properties— .This principal is vital in the management of distal tibial fractures, because of peculiar extraosseous-metaphyseal blood supply in the distal region of the tibia. In this study we aim to evaluate the functional outcome, duration of union, advantages and complication following use of MIPO with LCP for meta-diaphyseal fractures of distal tibia.

PATIENTS AND METHODS

This study was conducted at Department of Orthopaedics, RD Gardi Medical College Ujjain between 2016 to 2019. It was a prospective study on 25 patients treated by MIPO (Minimal Invasive Plate Osteosynthesis) for unstable fractures of the distal tibia.

Inclusion criteria

1. Adults (age > 18 years) males or females.
2. Complex extra-articular meta-diaphyseal fractures of the lower third of tibia.

Exclusion criteria

1. Open fractures
2. Intra articular fractures

Out of 25 patients 18 (72%) were male and 7 (28%) were female patients showing increased male preponderance in view of more travelling, working in farms and factories. In our study We had 21 (84%) RTA injuries, 3 (12%) Falls and 1(4%) Fire arm injuries..

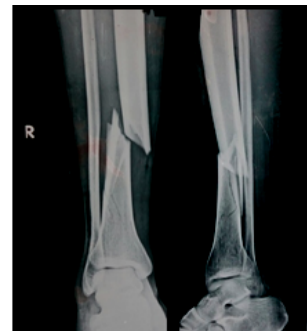On local examination, the injured extremity revealed deformity, swelling and loss of function. Palpation revealed abnormal mobility in both planes and crepitus at the fracture site. Distal neurovascular status was assessed by the posterior tibial artery and dorsalis pedis artery pulsations, nail beds, capillary refilling, local temperature, pallor and paraesthesia.

Antero-posterior and lateral radiographs of the affected leg were taken and the fracture patterns were classified. The limb was then immobilized in an above knee POP slab till definitive surgery with locking compression plate done. All the cases were taken for early primary fixation with locking compression plate.

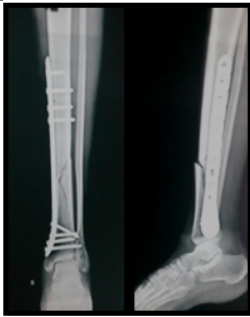RESULTS

The average time to union was 20 weeks in our study. Radiological union of the fracture i.e. characterized by cortex to cortex healing and bridging callus of the fracture in both AP and lateral views of follow up x-rays, was considered as satisfactory union.

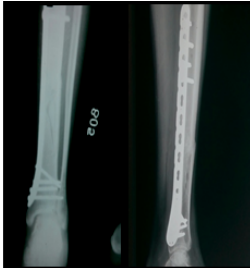
Fractures of 02 (08%) patients united in 16 weeks, 4(16%) patients united in 18 weeks, 8 (32%) patients united in 18 weeks and 11 (44%) patients united in 20 weeks. All cases fibula fracture healed without complications.



PRE-OP X RAYS



IMMEDIATE POST-OP



AT 20 WEEKS AFTER FIXATION

CLINICAL PHOTOGRAPHS

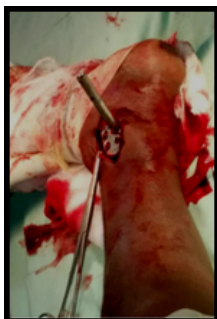
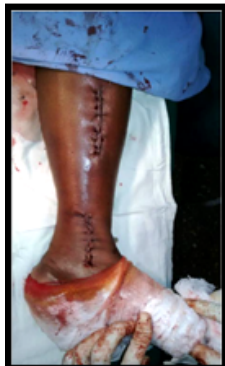
Plate insertion



Wound Closure

DISCUSSION

Fracture of the distal tibia with or without intraarticular extension was among the most difficult fractures to treat effectively because the majority of these fractures are unstable, comminuted with extensive soft tissue damage. The primary goal of treatment is to align the fractures fragments while providing enough stability to allow early motion. Treatment of these fractures with ORIF with conventional plate, Intra medullary nailing resulted in high rates of complication. The ideal method of treatment is one that would achieve excellent articular reduction and stability while minimizing soft tissue compromise and devascularisation of the fracture fragments. With the development of the technique of MIPO with locking compression plate which preserves extraosseous blood supply, respect osteogenic fracture hematoma, biologically friendly and stable fixation method is available for a distal tibial fracture. The status of the soft tissues, the amount of comminution sustained at the time of injury affect the treatment modality, and the long term clinical results. This is achieved with minimal bony and soft tissue devascularisation in order to decrease the complications resulting from the treatment. MIPO technique prevents Iatrogenic injury to the vascular supply of the bone. Unlike conventional plates, LCP is a fracture independent self-stable construct that provides both Angular and axial stability and minimizes the risk of secondary loss of reduction.

I. Age/Sex:

In our study of 25 patients with comminuted distal femur fractures the mean age of the patients was 41 years and there were 18 males (72%) and 07 females (28%).

This is a reflection of the mechanism of injury which was high energy trauma in 70% of our patients of which most of whom were younger. The reason being that, in male patients there was more outdoor activities, so they were more prone to vehicular accident and majority females being house wives were less exposed to road traffic accidents.

Study by **Cory Collinge et al⁽¹¹⁾**, which had patients with average age of 43 years with male preponderance and the study by **Heather A Vallier et al⁽¹²⁾** found the average age of patients was 39 years.

ii. Mode of Injury:

In our study most of the injuries were caused by road traffic accidents affecting mostly males. We had 21 (84%) RTA injuries, 3 (12%) Falls and 1 (4%) Fire arm injuries..

This was comparable to the studies conducted by **Heather A Vallier et al⁽¹³⁾** who had 30% open fractures, **Hazarika et al⁽¹³⁾** who had 40% open fractures.

iii. Fracture pattern

Out of 25 distal tibia fractures in our study, 10 of B2, 8 of B1,3 of C2, and 1 each of A3,B3,C1,C3. Study by Cory collinge et al showed 53% A2, 16% A3, 18% C1 and 13% C2 type fracture. Heather A Vallier et al also had 46% Type A fractures, 14% Type B fractures and 40% Type C fractures.

iv. Time of Union

The average time to union was 20 weeks in our study. Radiological union of the fracture i.e. characterized by cortex to cortex healing and bridging callus of the fracture in both AP and lateral views of follow up x-rays, was considered as satisfactory union.

Cory Collinge et al⁽¹¹⁾ had an average fracture union time of 21 weeks and **Hazarika et al⁽¹³⁾** had an average of 19 weeks.

v. Infection

We had superficial infection in 2 cases (1 superficial and 1 deep) out of 25 patients who completed the study. The patient had superficial infection for 6-8 weeks which delayed bone union and full weight bearing. The infection subsided after debridement, dressing and course of IV antibiotics. But in one case with deep infection we removed the plate after fracture is united.

2 cases having ankle stiffness which resolved after physiotherapy.

Ovadia and Beals⁽¹⁴⁾ reviewed 34 fractures equivalent to Ruedi Type III treated with traditional open reduction and plate fixation. Good to excellent results were achieved in only 47%. Complications were numerous and, although not sub classified according to fracture type,

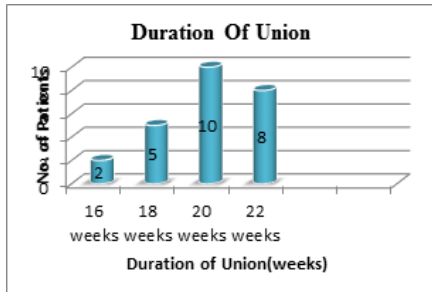
superficial infections or skin loss developed in 9 patients (11%), osteomyelitis developed in 5 patients (6%), 17 patients (12%) required either ankleArthrodesis or Arthroplasty.

vi.The AOFAS Score And Results

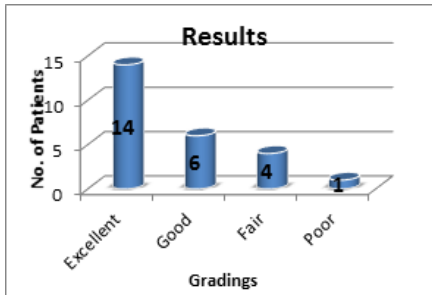
Evaluation according to American orthopaedics foot and ankle society score a mean score of 70 with a range of 43 to 85. our study of 25 patients treated 14(58.3%) patients had excellent outcome, 6(20.8%) had good results, 4(16.7%) had fair outcome and 1(4.1%) had a poor results. Excellent and Good results accounted for 80% of cases and remaining 20% included Fair and Poor cases. Younger patients had better results than older age. The time to union increased with increase with age.

Hazarika et al⁽¹³⁾, in their study of 20 patients of distal tibial fracture treated using locking compression plates through MIPPO technique got 87.5% of good to excellent results. Fractures were classified according to the AO system and performed as scored stage surgery after stabilization with external fixators.

2.DURATION OF FRACTURE UNION:



3.RESULTS



CONCLUSION

At the end of the present study, the following conclusion could be drawn from the Bridge plating of the comminuted fractures of diaphyseal and metaphyseal fractures of tibia using stainless steel locking compression plate.

There is an increase in the complexity of metaphyseal fractures of tibia with increasing road traffic accidents.

As most of the patients sustained these fractures belong to physically highlyactive and productive age group, they need optimal treatment to get back to their previous work capacity as early as possible and avoid long term complications.

These fractures with inherent less soft tissue coverage and added soft tissuotrauma poses a higher risk of postoperative wound dehiscence and infection. Hence they demand tissue friendly surgical procedures as well as adequate fracture fixation.

The anchorage of the locking head screw was found to be excellent when working on metaphyseal bone and even in osteoporotic bone.

While bridging a fracture, care must be taken to select a strong plate of the adequate length of at least 2-3 times the fracture length and leave at least one third to half of the plate holes without filling screws. This prevents the stress concentration and achieves an elastic fixation which is essential for secondary fracture union.

We treated all the fracture in our study with Bridging plate technique using stainless steel locking compression plate and found rapid healing

by secondary fracture union with few complications and hence achieving strong bone union across the fracture site due to inherent benefits of less tissue damage and minimal disturbance of fracture site biology.

REFERENCES:

1. Evaluation of the functional outcome in distal tibia fractures managed by MIPPO technique using distal tibia locking plate,Dr. SK Irfan Ali, Dr. Ravikummar K, Dr. Sharvin Sheth, Dr. Amit Kumar Sinha, Dr. Ankush Karale and Dr. MK Siddalinga Swamy ISSN: 2395-1958 IJOS 2017; 3(2): 441-444 © 2017 IJOS.
2. Agarwal N, Sood A. A study on surgical management of distal tibial fractures by using minimally invasive technique of percutaneous plate osteosynthesis with locking compression plate. Int J Health Sci Res. 2018; 8(10):138-144.
3. Robinson J de D. Orthopaedic Trauma in the Austere Environment: A Practical Guide to Care in the Humanitarian Setting. Springer; 2016. 699 p.
4. Mehta SS, Rees K, Cutler L, Mangwani J. Understanding risks and complications in the management of ankle fractures. Indian J Orthop. 2014;48(5):445-52.
5. Minimally Invasive Plate Osteosynthesis with Locking Compression Plate for Distal Diametaphyseal Tibia Fracture [Request PDF [Internet]]. ResearchGate. [cited 2020 Jul 8]. Available from: https://www.researchgate.net/publication/225050248_Minimally_Invasive_Plate_Osteosynthesis_with_Locking_Compression_Plate_for_Distal_Diametaphyseal_Tibia_Fracture
6. Wu D, Mao F, Yuan B, Ren G, Liu H, Peng C. Minimally Invasive Percutaneous Plate Osteosynthesis (MIPPO) Combined with Onionskin-Like Autologous Bone Grafting: A New Technique for Treatment of Tibial Nonunion. Med Sci Monit Int Med J Exp Clin Res. 2019 Aug 12;25:5997-6006.
7. Bingol I, Yalcin N, Biciçi V, Tulunay T, Yuksel K, Kilicaslan K. Minimally Invasive Percutaneous Tibial Osteosynthesis Does Not Increase Complication Rates in Extra-Articular Distal Tibial Fractures. Open Orthop J. 2015 Mar 31;9:73-7.
8. Kartavya Chaudhari., et al. "A Comparative Study of Surgical Management of Distal Tibial Fractures Treated with Locking Compression Plate by Minimally Invasive Percutaneous Plate Osteosynthesis (MIPPO) and Expert Tibial Nail". EC Orthopaedics 9.9 (2018): 702-714.
9. Akram W, Mahto AK, Alam M. Evaluation of results of minimally invasive plating osteosynthesis (MIPO) technique in the treatment of fractures of distal tibia. Int J Res Orthop 2017;3:7-11.
10. Mipo technique for management of distal third tibia fractures using LCP-precontoured (3.5mm & 4.5mm)Dr. Ravindra and Dr. Paramesh K,ISSN: 2395-1958 IJOS 2016; 2(4): 81-85 © 2016 IJOS.
11. Cory Collinge, Mark Kuper, Kirk Larson, and Robert Protzman. Minimally Invasive Plating of High-Energy Metaphyseal Distal Tibial Fractures. J Orthop Trauma 2007;21:355-361.
12. Heather .A. Vallier, T. Toan le, Asheesh Bedi. Radiographic and clinical comparisons of distal tibia shaft fractures (4-11 cms proximal top/tafond) plating versus intramedullary nailing. J Orthop Trauma 2008;22:307-311.
13. Hazarika S, Chakravarthy J, Cooper J. Minimally invasive locking plate osteosynthesis for fractures of the distal tibia—results in 20patients. Injury. 2006;37(9).
14. Ovadia DN, Beals RK. Fractures of the tibial plafond. J Bone Joint Surg Am. 1986;68(4):543-551.
15. McFerran MA, Smith SW, Bonlas HJ. Complications encountered in the treatment of pilon fractures. J Orthop Trauma 1992; 6: 195-200.
16. Ozakaya U, Parmaksizoglu AS, Gul M, Sokucu S, Kabukcuoglu Y.Minimally invasive treatment of distal tibial fractures