



AN ENIGMA GORLIN GOLTZ SYNDROME: A RARE CASE REPORT

Clinical Research

Dr. Manpreet Singh	Professor and Head, Department of Oral & Maxillofacial Surgery, Kothiwal Dental College & Research Centre, Moradabad-244001, Uttar Pradesh, India
Dr. Ankit Kumar*	Reader, Department of Oral & Maxillofacial Surgery, Kothiwal Dental College & Research Centre, Moradabad-244001, Uttar Pradesh, India *Corresponding Author
Dr. Pranshu Chauhan	Sr. Lecturer, Department of Oral & Maxillofacial Surgery, Kothiwal Dental College & Research Centre, Moradabad-244001, Uttar Pradesh, India
Dr. Sourav Kumar	Post Graduate student, Department of Oral & Maxillofacial Surgery, Kothiwal Dental College & Research Centre, Moradabad-244001, Uttar Pradesh, India
Dr. Musaab Khan	Post Graduate student, Department of Oral & Maxillofacial Surgery, Kothiwal Dental College & Research Centre, Moradabad-244001, Uttar Pradesh, India
Dr. Reshu Rastogi	Post Graduate student, Department of Oral & Maxillofacial Surgery, Kothiwal Dental College & Research Centre, Moradabad-244001, Uttar Pradesh, India.

ABSTRACT

The Gorlin-Goltz syndrome (GGS) (the nevoid basal cell carcinoma syndrome—NBCCS) is a rare autosomal dominant syndrome caused due to mutations in the PTCH (patched) gene found on chromosome arm 9q. The syndrome, characterized by increased predisposition to develop basal cell carcinoma and associated multiorgan anomalies, has a high level of penetrance and variable expressiveness. This case report is of 29 years old male with complaint of pus discharge from upper and lower posterior teeth region since 5 months. On the basis of clinical and radiographic findings provisional diagnosis was made of gorlin -goltz syndrome and was planned for surgical intervention .But the patient deferred the treatment due to financial crisis .patient is recalled after 6 months for follow up.

KEYWORDS

gorlin -goltz syndrome, basal cell carcinoma, multiple odontogenic keratocyst

INTRODUCTION

Nevoid basal cell carcinoma syndrome (NBCCS), also known as Gorlin-Goltz syndrome, is an autosomal dominant disorder characterized by a predisposition to neoplasms and other developmental abnormalities.¹ It is an infrequent multisystemic disease. In 1894, Jarisch and White made the first descriptions of patients with this syndrome, highlighting the presence of multiple basocellular carcinomas. This syndrome existed during Dynastic Egyptian times, as shown by findings compatible with the syndrome in mummies dating back to 1,000 b.c.² The prevalence of NBCCS is about 1 per 60,000.³ This syndrome probably presents itself in all ethnic groups, although a few cases have been published in certain human races, and affects both men and women in the same way.⁴ The tumour suppressor gene called Patched (PTCH), located in the 9q22.3 chromosome, has been identified as cause of NBCCS. ^{3,5} However, mutations in other genes such as Patched 2 (PTCH2), Smoothened (SMO) and Sonic hedgehog (SHH) have been reported in isolated cases of basal cell carcinoma and medulloblastoma.⁶ In the case of NBCCS it is of great importance to make an early diagnosis since the severity of complications, such as malignant skin and brain tumours can be reduced, and maxillofacial deformities related to the jaw cysts can be avoided.⁴ The treatment of NBCCS involves a therapeutic approach to its clinical findings. Furthermore, our case emphasizes the role of the dentist in recognizing these features in order to arrive at an early diagnosis and a multi disciplinary approach in treating the condition.

CASE REPORT:

A male patient 29 years old from Najeebabad Bijour reported to our institute kothiwal dental college and research center department of oral and maxillofacial surgery with chief complaint of pus discharge from upper and lower posterior tooth region since 5 months. Patient's family history revealed that two of his younger brothers also had multiple cysts in jaws. History revealed no deleterious habits was present. On general examination, the patient was apparently healthy. Gait was normal, built was moderate, and all the vital signs were within normal limits. Patient was apparently well 6 months back, then he noticed pus discharge from his maxillary and mandibular posterior tooth region, at

that time he didn't experienced any pain, after 15 days he noticed swelling and experienced pain on mandibular posterior tooth region bilaterally. After which he consulted a nearby dentist who advised radiographic investigation, patient had his OPG done and was informed about presence of multiple cysts. He was referred to a higher center so, he reported to our department for definitive treatment. General examination of the patient revealed palmar and plantar pits, Frontal bossing, pectus excavatum and scoliosis. (Figure 1,2). On extraoral examination diffuse swelling is present on left side of face extending antero-posteriorly corner of lip to posterior border of mandibular ramus superio-inferiorly lateral canthus of left eye to base of the mandible .Swelling was non tender on palpation and firm in consistency .On intraoral examination revealed tooth 22 was congenitally missing with mild buccal vestibule obliteration in mandibular posterior region bilaterally. Midline shift was evident. [Figure 3(a)].On palpation a bony hard swelling was present on buccal and lingual side extending antero-posteriorly 44 region to distal of 48 tooth region. Bilateral expansion of bony hard swelling on left side on anterior border of ramus extending supero-inferiorly lower to upper occlusal plane. Figure 3 (b) Swelling was non fluctuant and non-tender in nature in maxilla no significant findings was present.

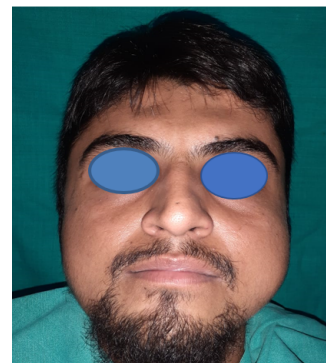

Figure 1. The figure shows frontal bossing and mandibular prognathism.

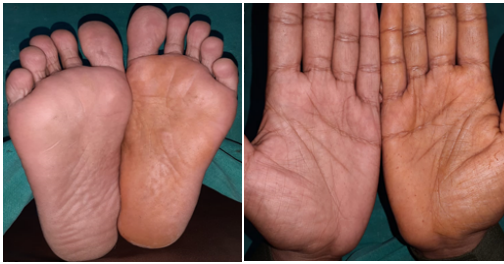

Figure 2(a) Figure shows plantar pits .Figure 2(b) shows palmar pits

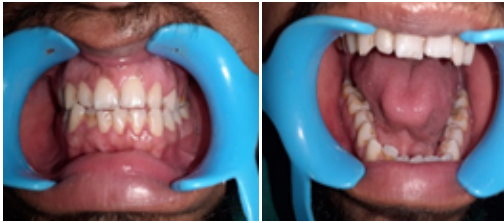

Figure 3. 3(a) Figure shows congenitally missing left upper lateral incisor,3(b) shows buccal and lingual expansion antero-posteriorly 44 region to distal of 48 tooth region.

Radiographic investigations done was x-ray chest, CBCT, OPG, Lumbo-sacral spine x-ray. OPG of the patient revealed multiple cysts, x-ray chest revealed crowding of ribs on left side (figure 4), frontal bossing is evident on lateral cephalogram (figure 5). Aspiration done was positive and it was straw color. (Figure 10)

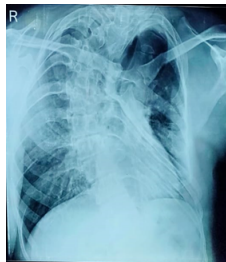

Figure 4. Figure shows crowding of ribs on left side along with bifid ribs on right and left side

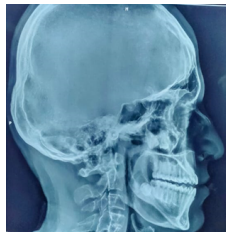

Figure 5. Figure shows frontal bossing

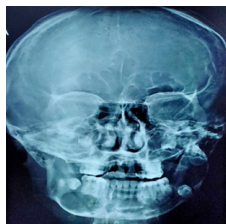

Figure 6. Figure shows multiple cysts of mandible

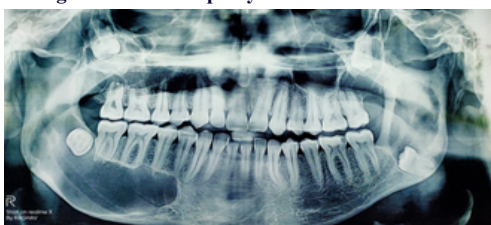


Figure 7 Figure shows the multiple cysts of jaws bilaterally

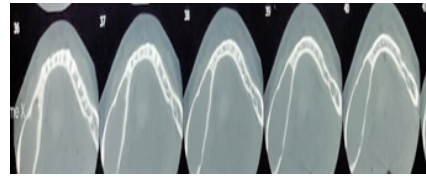


Figure 8. Figure shows bilateral expansion of bone buccally and lingually

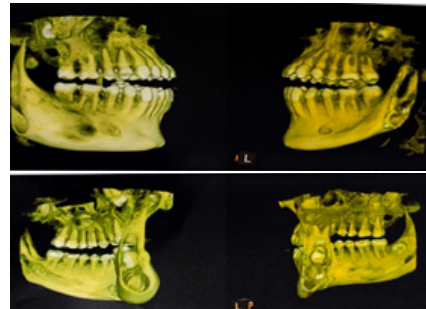
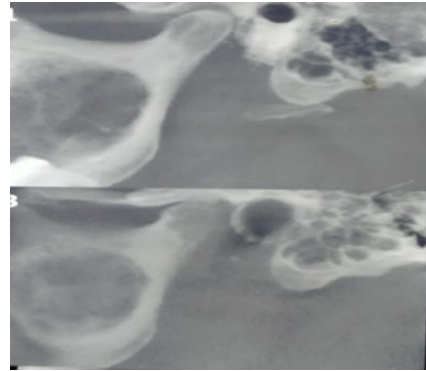


Figure 9. Figure shows radiolucency present in mandibular ramus region

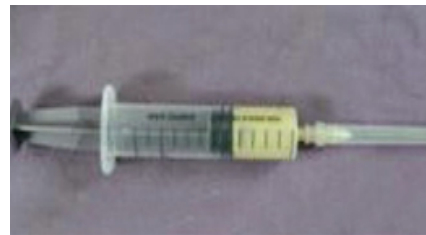

Figure 10. figure shows the positive aspiration with straw colored fluid.

DISCUSSION

The Gorlin-Goltz syndrome is an autosomal dominant inherited syndrome manifested by multiple defects involving the skin, nervous system, eyes, endocrine system, and bones. It is also known as basal cell nevus syndrome, multiple basal cell carcinoma syndrome, Gorlin syndrome, or hereditary cutaneomandibular polyonocosis, multiple nevoid basal cell epithelioma-jaw cysts, or bifid rib syndrome⁷. The diagnostic criteria for nevoid BCC was established by Evans et al.⁸ and modified by Kimonis et al. in 1973^{9,10}. According to them diagnosis of Gorlin-Goltz syndrome can be established when two major or one major and two minor are present which are described below.

Major Criteria are as follows:

- (1) More than 2 BCCs or one under age of 20 year,
- (2) odontogenic keratocyst,
- (3) Three or more palmar pits,
- (4) bilamellar calcification of falx cerebri,
- (5) Bifid, fused, or splayed ribs,
- (6) First-degree relative with NBCCS.

Minor Criteria are as follows:

- (1) Macrocephaly adjusted for height,
- (2) Frontal bossing, cleft lip/palate, and hypertelorism,
- (3) Sprengel deformity, pectus, and syndactyly of digits,
- (4) Bridging of sella turcica, hemivertebrae, and flameshaped

- radiolucencies,
 (5) Ovarian fibroma,
 (6) medulloblastoma^{10,11}.

The present case report showed a male patient presenting, among others, some of these features, such as multiple KCOTs in the maxilla and mandible, rib anomalies, spine bifida, calcification of the falx cerebri, and vertebral anomaly characterized by kyphoscoliosis, which confirmed the diagnosis of NBCCS or Gorlin-Goltz syndrome.

Odontogenic Keratocysts

Woolgar et al.¹² and Dominguez et al.¹³ found significant differences between syndrome keratocysts and single keratocysts. Syndrome keratocysts were found to have a markedly increased number of satellite cysts, solid islands of epithelial proliferation, odontogenic rests within the capsule, and mitotic figures in the epithelial lining of the main cavity. There are immunochemical differences between syndromal and solitary keratocysts. Woolgar et al. noted that syndrome keratocysts tend to occur at a much earlier age than single keratocysts.^{11, 12}

Less than 10% of patients with multiple OKCs have other manifestations of this syndrome; however, it has been suggested that multiple OKCs alone may be the confirmatory of the syndrome

Palmar and plantar pits

The presence of palmar (70%) and/or plantar (50%) pits is a very important diagnostic factor. They are small, with a diameter ranging from 2 to 3 mm and depth from 1 to 3 mm. They are red at the bottom in Caucasians and black in Negroids. From 30% to 65% of cases involve children under 10, but the prevalence in the age group above 20 years is 85%. The number of pits increases with age. They become more visible after the palms have been held in warm water for about 10 minutes.^{14,15,16}

Basal cell carcinoma

Multiple basal cell carcinoma of the skin constitutes the most characteristic feature of the syndrome. The highest incidence rate is observed in people between puberty and age 35, although it was also observed in children ages 3 to 4 years. It is diagnosed in 90% of Caucasians age 40 or older^{14,8} and in 40% of the Negroid population^{16,17,18}. The number of BCC lesions varies from several to thousands¹⁶, their diameter ranges from 1 mm to 10 mm, and they may have various forms from skin-coloured nodules or papules to ulcerating plaques.

They are usually located on the face, back and chest, but they may also be found on skin not exposed to the sun¹⁶. Aggressive forms of basal cell carcinomas, which infiltrate the facial bones, hardly ever occur¹⁹. The above-mentioned lesions are extremely challenging for therapists but, thanks to the combined efforts of various medical specialists such as maxillofacial surgeons, plastic surgeons, laryngologists, oncologists, radiation oncologists, restorative dental specialists and psychologists, the patients have a chance to recover and regain their regular social functions.^{20,21,22}

CONCLUSION

Our case illustrates the need for awareness of the syndrome among dentists in relation to younger age patients with no lesions of the skin. Proper evaluation and characterization of clinical features are essential for the correct diagnosis and management. Gorlin-Goltz syndrome is an entity that often involves the maxillofacial region. Early identification of the syndrome is important for prevention of secondary radiation induced malignancies both intracranial and extracranial. Patient needs multi speciality consultations for counselling of risk prevention, screening of various malignancies and treatment and needs to be on a regular follow up which is easier in an institutional setting.

REFERENCES:

- [1] Yamamoto K, Yoshihashi H, Furuya N, Adachi M, Ito S, Tanaka Y, Masuno M, Chiyo H, Kurosawa K: Further delineation of 9q22 deletion syndrome associated with basal cell nevus (Gorlin) syndrome: Report of two cases and review of the literature. *Congenit Anom* 2009; 49:8-14.
- [2] Satinoff MI, Wells C: Multiple basal cell naevus syndrome in ancient. *Egypt Med Hist* 1969; 13:29-47.
- [3] Gorlin RJ: Nevoid basal cell carcinoma (Gorlin) syndrome: Unanswered issues. *J Lab Clin Med* 1999; 134:551-2.
- [4] Amezcaga AOG, Arregui OG, Nuño SZ, Sagredo AA, Urizar JMA: Gorlin-Goltz syndrome: Clinicopathologic aspects. *Med Oral Patol Oral Cir Bucal* 2008; 13:338-43.
- [5] Yang X, Pfeiffer RM, Goldstein AM: Influence of glutathione-S-transferase (GSTM1, GSTP1, GSTT1) and cytochrome p450 (CYP1A1, CYP2D6) polymorphism on numbers of basal cell carcinomas (BCCs) in families with the naevoid basal cell carcinoma syndrome. *J Med Genet* 2006; 43:e1-e16.
- [6] Cohen MM: Nevoid basal cell carcinoma syndrome: molecular biology and new hypotheses. *Int J Oral Maxillofac Surg* 1999; 28:216-23.
- [7] D. S. Jawa, K. Sircar, R. Somani, N. Grover, S. Jaidka, and S. Singh, "Gorlin-Goltz

- [8] syndrome," *Journal of Oral and Maxillofacial Pathology* 2009; 13(2): 89-92.
- [9] D. G. R. Evans, E. J. Ladusans, S. Rimmer, L. D. Burnell, N. Thakker, and P. A. Farndon, "Complications of the naevoid basal cell carcinoma syndrome: results of a population based study," *Journal of Medical Genetics* 1993; 30(6):460-64.
- [10] V. E. Kimonis, A. M. Goldstein, B. Pastakia et al., "Clinical manifestations in 105 persons With nevoid basal cell carcinoma syndrome," *American Journal of Medical Genetics* 1997; 69: 299-308.
- [11] Kohli, M. Kohli, N. Sharma, S. R. Siddiqui, and S. P. S. Tulsi, "Gorlin-Goltz syndrome," *National Journal of Maxillofacial Surgery* 2010; 1(1):50-2.
- [12] Gorlin RJ, Cohen MM, and R. C. M. Hennkem, *Syndromes of Head and Neck*, Chapter 12, 4th edition, 2001.
- [13] J. A. Woolgar, J.W. Rippin, and R.M. Browne, "A comparative histological study of odontogenic keratocysts in basal cell naevus syndrome and control patients." *Journal of Oral Pathology & Medicine* 1987; 16(2):75-80.
- [14] F. V. Dominguez and A. Keszler, Comparative study of keratocysts, associated and non-associated with nevoid basal cell carcinoma syndrome. *Journal of Oral Pathology & Medicine* 1988; 17(1): 39-42.
- [15] Walter AW: Gorlin Syndrome. www.emedicine.com/PED/topic890.htm
- [16] www.gorlingroup.co.uk
- [17] Muzio L: Nevoid Basal Cell Carcinoma Syndrome (Gorlin Syndrome). *Orphanet J Rare Dis*, 2008; 3: 32-48.
- [18] Kulkarni P, Brashear R, Chuang T: Nevoid basal cell carcinoma syndrome in a person with dark skin. *J Am Acad Dermatol*, 2003; 49: 332-35.
- [19] Hall J, Johnston KA, McPhillips JP et al: Nevoid basal cell carcinoma syndrome in a black child. *J Am Acad Dermatol*, 1998; 38: 363-65
- [20] Ortega Garcia de Amezcaga A, Garcia Arregui O, Zepeda Nuño S et al: Gorlin-Goltz syndrome: clinicopathologic aspects. *Med Oral Patol Oral Cir Bucal*, 2008; 13: 338-43.
- [21] Manfredi M, Vescovi P, Bonanini M, Porter S: Nevoid basal cell carcinoma syndrome: a review of the literature. *Int J Oral and Maxillofac Surg*, 2004; 33: 117-24.
- [22] Honavar SG, Shields JA, Shields CL et al: Basal cell carcinoma of the eyelid associated with Gorlin-Goltz syndrome. *Ophthalmology*, 2001; 108: 1115-23
- [23] Nagy K, Kiss E, Erdei C et al: Complex care by multiple medical and dental specialists of a patient with aggressive Gorlin-Goltz syndrome. *Postgrad Med J*, 2008; 84: 330-32