ORIGINAL RESEARCH PAPER

Volume-9 | Issue-2 | February-2020 | PRINT ISSN No. 2277 - 8179 | DOI : 10.36106/ijsr

INTERNATIONAL JOURNAL OF SCIENTIFIC RESEARCH

MAXILLARY SINUS LIFT: DIRECT VS. INDIRECT APPROACH IN POSTERIOR MAXILLA- A CASE REPORT

Periodontology

B. Tejaswini*	Post graduate, Department of Periodontics, St joseph dental college, Andhra Pradesh, India *Corresponding Author
Pavuluri Aravind Kumar	Professor, Department of Periodontics, St joseph dental college, Andhra Pradesh, India
Mandalapu Narendra Babu	Professor, Department of Periodontics, St joseph dental college, Andhra Pradesh, India
Kalapala Raviraj	Senior lecturer, Department of Periodontics, St joseph dental college, Andhra Pradesh, India

ABSTRACT

The posterior maxilla presents several challenges to the implantologist. An excellent treatment modality that had been into the modern era of dentistry is implant dentistry. The application of implant dentistry could jeopardize the patients presented with deficient alveolar ridges. The most often encountered magnified problem in the posterior maxilla is ridge resorption and sinus pneumatization. This anatomic deficiency can be restored by a procedure called maxillary sinus floor lift. The purpose of this case report is to bring forward such a technique which prevents perforation of sinus lining during implant placement by doing the sinus lift with a direct and indirect approach and to compare both the sinus lift approaches.

KEYWORDS

Maxillary sinus floor lift up, implant, indirect approach, direct approach, posterior maxilla.

INTRODUCTION

The use of dental implants can replace the form and functions of missing teeth. A sinus lift is a well-accepted technique used to treat the loss of vertical bone height (VBH) in the posterior maxilla performed in two ways: A lateral window technique and a sinus floor elevation technique by osteotome and placing bone-graft material in the maxillary sinus to increase the height and width of the available bone. In this case report, we performed a lateral (direct) sinus lift procedure and compared it with the osteotome (indirect) technique[1].

CASE REPORT

A 35 year - an old female complains of missing maxillary molar teeth. The available bone height in the right maxillary molar region on radiographic examination found to be 6mm from the maxillary sinus lining, and the left maxillary molar region found to be 5.5mm from the maxillary sinus lining. After a thorough oral and radiographic examination, it was decided to lift the sinus lining through direct and indirect approaches in the maxillary left and right back tooth region and simultaneously placing the implant[2].

SURGICAL PROCEDURE

Implants placement done simultaneously following the sinus elevation procedure (either direct or indirect sinus approach).

INDIRECT SINUS APPROACH:

A pilot drill was drilled in the marked implant site. Drills with increasing diameters were used. The height was maintained 2 mm short of the sinus floor. By the insertion of correct caliber osteotome, the indirect sinus lift was done, and successively higher instrument diameters were used. Prf was placed, and then osseograft was inserted. Then the implant was placed immediately, cover screw and sutures were placed[3]. [Fig:1-3]

Figure 1: Incision Given

Figure 2: Indirect Sinus Lifting Done, Sequential Drilling Was Done For Preparation Of Osteotomy Site And Prf Placed At Osteotomy Site

Figure 3: Implant Placement Was Done

DIRECT SINUS APPROACH

The buccal bone window was created on the anterolateral wall of the maxillary sinus behind the canine fossa. The bony wall gently elevated with sinus membrane elevators. A pilot drill was drilled, and drills with increasing diameters were used. Prf and the osseous graft placed in the prepared osteotomy site. Then implants were placed into the prepared site, and cover screw and sutures were placed[3].[Fig:4-7]

Figure 4: Incision Given

Figure 5: Direct Sinus Lift Done

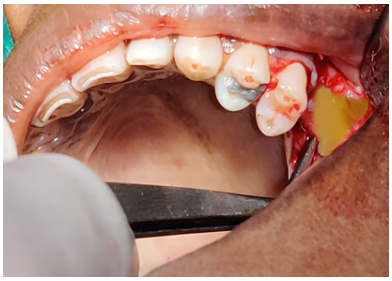

Figure 6: Osteotomy Site Was Prepared With Sequential Drills And Prf Placement Done

Figure 7: Post Operative Photograph Showing Final Prosthesis

RESULTS

On comparing the bone height gained in direct and indirect sinus approach, the average bone height increased in the direct sinus approach was more. Stability was equal in both direct and indirect sinus approaches. Osseointegration was more in direct sinus lift.

DISCUSSION

Placement of implants is of more concern in the posterior maxilla because of the presence of maxillary sinus. In this case report for an indirect approach for lifting the sinus lining by the use of a dental implant, the sinus floor was fractured first with the use of bone graft and osteotome. Unlike self threaded implants, these implants require tapping, and because of this property, they were used for lifting the sinus membrane[4].

For the direct approach, a mucoperiosteal flap was elevated. The piezosurgical technique was used to overcome window perforation of the sinus membrane. This technique prevents perforation of the "Schniderian Membrane" and cause minimal postoperative complications[4].

Oscillation frequency used in piezosurgery acts on mineralized tissue; therefore, the cutting tip becomes inactive when it comes in contact with soft tissue. Hence, soft tissue damage is not noticed. The prepared osteotomy was widened to 4.5 mm, protecting the raised sinus lining. Since, the crestal width of bone in was 5.5 mm, an implant of 10mm length and 4.2mm diameter implant was placed. The piezo-surgical technique for intervention, which is a comparatively safer approach to the maxillary sinus, was tried, allowing sinus membrane integrity to be maintained[5].

CONCLUSION

This case report shows successful management of sinus lift procedure with definitive bone gain and osseointegration[6] of dental implants. However, further studies are required to substantiate the use of different types of techniques in such procedures.

REFERENCES:

1. Pal, U. S., Sharma, N. K., Singh, R. K., Mahammad, S., Mehrotra, D., Singh, N., & Mandhyan, D. (2012). Direct vs. indirect sinus lift procedure: A comparison. National journal of maxillofacial surgery, 3(1), 31.
2. Agnihotri, A., & Agnihotri, D. (2012). Maxillary sinus lift up: An indirect approach of implant placement in posterior maxilla. Int J Oral Implant Clin Res, 3(2), 102-104.
3. Daniel, D., & Rao, S. G. (2012). Evaluation of increase in bone height following maxillary sinus augmentation using direct and indirect technique. Journal of Dental Implants, 2(1), 26.
4. Purushotham, S., Raveendran, A. M., Kripalani, B. K., & D'Souza, M. L. (2016). Direct sinus lift and immediate implant placement using piezosurgical approach-A case report. Journal of Clinical and Diagnostic Research: JCDR, 10(1), ZD20.
5. Mohinder panwar, dushyant malik, manab kosala, Jacqueline Jacinta dias.(2017). Direct maxillary sinus lift with simultaneous implant placement: a clinical and radiological evaluation. Indian journal of applied research, vol 7, issue 12
6. Agamy, E. M. T. M., & Niedermeier, W. (2010). Indirect sinus floor elevation for osseointegrated prostheses. A 10-year prospective study. Journal of Oral Implantology, 36(2), 113-121.