



## TALIPES CALCANEAL VALGUS FOOT WITH CHRONIC OSTEOMYELITIS- A CASE STUDY ON PRIMARY ANKLE ARTHRODESIS

### Orthopaedics

**Dr. Radhesh R Menon\***

Junior Resident, Department of Orthopaedics, K S Hegde Medical Academy, Deralakatte, Mangalore. \*Corresponding Author

**Dr. Haridas S**

Senior Resident, Department of Orthopaedics, K S Hegde Medical Academy, Deralakatte, Mangalore

### ABSTRACT

**Aim-** To provide the functional ability to the deformed ankle joint and foot.

**Methods-** 10-year-old male came with deformity of the left ankle and foot following the history of snakebite injury five months back. The patient was managed conservatively at the time of injury and later progressed to develop chronic osteomyelitis of the distal tibia, talus and calcaneum. Patient on presentation had a talipes-calcaneo-valgus deformity, with discharging sinus. The patient underwent deformity correction by distal tibia osteotomy, bone grafting and tibiotalar calcaneal arthrodesis with Steinman pin. The soft tissue defect closed with primary reverse sural artery flap. Postoperatively, the patient underwent multiple debridement procedures, and defect finally closed with a split skin graft. The patient now does not have any discharge from the foot, Steinman pins removed. The arthrodesis is uniting with no persistent visible deformity and soft tissue defect.

**Results-** Achieved primary ankle arthrodesis with closure and no progression of the deformity

**Conclusion-** The goals of surgery were deformity correction, reduced bracing, and ability to wear regular shoes and to maintain function.

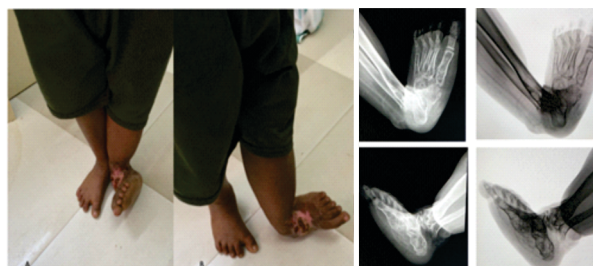### KEYWORDS

### INTRODUCTION

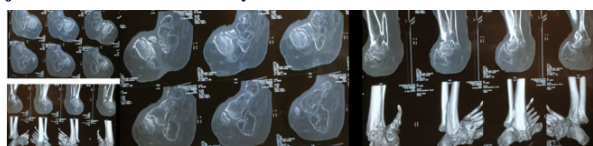
A complex foot deformity is a multiplanar deformity with or without foot shortening. Such deformities are caused by trauma, poliomyelitis, osteomyelitis, burn contractures, neuromuscular diseases or follow resistant congenital contractures like clubfoot. The main objectives of deformity correction: a plantigrade foot that fits in a normal shoe, a stable foot that allows better gait, a pain-free and a better-looking foot and the ability to perform activities of daily living.<sup>1</sup>

### Case History

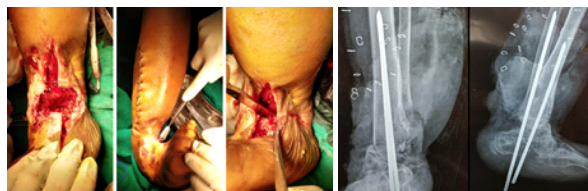10-year-old male came with deformity of the left ankle and foot following the history of snakebite injury five months back. The patient was managed conservatively at the time of injury and later progressed to develop chronic osteomyelitis of the distal tibia, talus and calcaneum. Patient on presentation had a talipes-calcaneo-valgus deformity, with discharging sinus (Figure 1, 2). The patient underwent deformity correction by supra malleolar osteotomy, bone grafting and tibiotalar calcaneal arthrodesis with Steinman pin (Figure 3). The soft tissue defect closed with primary reverse sural artery flap. Postoperatively, the patient underwent multiple debridement procedures, and defect finally closed with a split skin graft. The patient after 2 month follow-up does not have any discharge from the foot, Steinman pins removed. The arthrodesis is uniting with no persistent visible deformity and soft tissue defect (Figure 4). Thus, primary arthrodesis helped achieve the objectives of deformity correction.



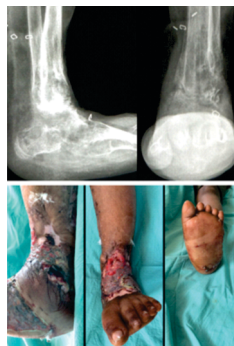**Figure 1- A & B showing calcaneo valgus deformity with a chronic discharging sinus on the dorsum of the foot. Xray of the foot & ankle showing severe osteopenia, with destruction of the ankle joint and tibiaofibular ankylosis**



**Figure 2- CT images showing the severe extent of the damage**



**Figure 3- Anteromedial approach to ankle joint, supra malleolar osteotomy done and arthrodesis done with Steinman pin**



**Figure 4- 2 months post op showing healing soft tissue with uniting arthrodesis & non progression of deformity**

### CONCLUSION

Complex multiplanar foot and ankle deformities are a challenge to the orthopaedic surgeon. These deformities affect gait and can cause compensatory changes in other joints leading to knee, hip and low back problems. The deformities prevent normal shoe wear which necessitates the need for specially designed foot and ankle orthoses. The abnormal contact pressures cause skin problems from callosities to skin ulcerations, which in turn can be complicated by infection and osteomyelitis. These problems add to the psychological distress experienced by these patients especially in case of growing children. In this case study, in the silhouette of chronic osteomyelitis, severe osteopenia and soft tissue contracture, primary arthrodesis of the tibio-talo-calcaneal joint helped achieve a plantigrade foot which cosmetically acceptable.

### REFERENCES-

1. Shalaby, H. & Hefny, H. Strat, Correction of complex foot deformities using the V-osteotomy and the Ilizarov technique, Traum Limb Recon (2007) 2: 21. <https://doi.org/10.1007/s11751-007-0015-7>