



A COMPARITIVE STUDY OF CONSERVATIVE VERSUS OPERATIVE MANAGEMENT OF STABLE TIBIA SHAFT FRACTURES IN ADULTS.

Orthopaedics

Dr. Muni Srikanth	Associate Professor Department of Orthopaedics Alluri Sitarama Raju Academy of Medical Sciences Eluru, West Godavari District Andhra Pradesh 534005, India
Dr. Sethu Madhav Chebrolu	Assistant Professor Department of Orthopaedics, Alluri Sitarama Raju Academy of Medical Sciences Eluru, West Godavari District Andhra Pradesh 534005, India
Dr. Rohit Inuganti*	Assistant Professor Department of Orthopaedics, Alluri Sitarama Raju Academy of Medical Sciences Eluru, West Godavari District Andhra Pradesh 534005, India *Corresponding Author
Dr. Yesoph Mungara	Postgraduate Department of Orthopaedics Alluri Sitarama Raju Academy of Medical Sciences Eluru, West Godavari District Andhra Pradesh 534005, India

ABSTRACT

Purpose: To study the short term functional outcome in treatment of stable tibia shaft fractures with casting versus nailing.

METHODS: A retrospective type of study conducted in ASRAM Hospital, Eluru from January 2018 to December 2019. A total number of 32 cases who met inclusion criteria were selected and taken into the study group. 16 patients were treated with closed reduction and Cast immobilization thereafter were assessed radiologically every month for fracture union. 16 patients were treated with intramedullary nail and were assessed clinically and radiologically at 6 weeks, 3 Months, 6 Months to assess the fracture union. Malalignment and malunion was measured with x rays. Knee, ankle, foot range of motion were measured with goniometry. Functional outcome was compared according to Johner and Wruhs criteria.

Results: Partial weight-bearing was begun at a mean of 12.4 weeks (SD 3.1) in Conservative group and by 9.8 weeks (SD 2.4) in nailing group, the difference being highly significant statistically (P VALUE < 0.0049). Time-to-Full weight-bearing was at a mean of 19.8 weeks (SD 2.9) in the Conservative group and 15.6 weeks (SD 1.3) in nailing group, the difference of which was very highly significant statistically (P < 0.0001). The full range of both knee joint and ankle joint movements were achieved much early in the nailing group (2.7 wks. & 2.5 wks) than in the Conservative group (15.8 wks. & 20.6 wks). The mean time-to- Bone union in the Conservative group was 25.8 weeks (SD 1.77), Compared to 20.7 weeks (SD 1.44) in the nailing group. The difference was very highly significant statistically (P < 0.0001). Varus or valgus angulations occurred in 5 patients of the Conservative group and 2 patients of nailing group. Anterior or posterior angulations occurred in 4 patients of Conservative group and 1 patient in nailing Group. In the Conservative group 2 delayed union cases, 1 Non union case, 1 case of significant displacement in cast was observed during follow up which were treated by Interlocking nailing. In the nailing group, 1 patient had a superficial infection, and 1 patient had delayed union. 4 of the patients (25 %) in the nailing group developed anterior knee pain. The functional outcome at 6 months follow up was better in the nailing group in which 87.5% of the fractures had an excellent-good outcome and none of the patients had poor outcomes. Compared to nailing group, functional outcome in the Conservative group was excellent-good in only 50% of the patients, 37.5% had a fair outcome and 12.5% had poor outcomes.

Conclusion: The treatment of stable fracture shaft of tibia surgically with interlocking nail appears to be an optimal mode of treatment than treatment with cast with better short term functional outcome.

KEYWORDS

Tibial shaft fracture, Casting, Intramedullary nail.

INTRODUCTION:

Being subcutaneous bone, the tibia shaft represents the most common site of long bone fractures. Males are more commonly affected than females. In Males the fracture occurs commonly between the ages of 10 and 20. In Women the fracture occurs commonly between the ages of 30 and 40. Males have the highest incidence of 21.5/100,000/year. Women have a frequency of 12.3/100,000/year¹.

Conservative treatment of tibia shaft fractures works on principle of conventional 3 Point moulding and Sarmiento casting to maintain fracture alignment². Conventional 3 point moulding requires Stable bony column to maintain length and an intact Soft-tissue hinge, usually intact periosteum, to be placed under tension, to maintain the alignment. Sarmiento casting utilises total contact patellar tendon Bearing cast Works by compressive forces acting through intact soft tissue sleeve to Maintain fracture alignment and it does not require intact periosteal hinge and can be Used in unstable bony column³. Sarmiento define acceptable limits for Cast/functional brace treatment of adult tibia shaft fractures as 5 degrees of coronal angulations, 10 to 15 degrees of sagittal angulations, <50% displacement, and 10 to 15 mm of shortening.

Operative treatment is indicated in the inability to achieve and maintain acceptable alignment by nonoperative means until union occurs. High velocity injuries with significant soft tissue damage, open fractures, displaced tibia shaft fracture with intact fibula, floating knee, comminuted and unstable fractures.

There are few studies comparing casting treatment with nailing in

treatment of stable Tibia shaft fractures. So our comparative study was conducted to study the short term functional outcome in treatment of stable tibia shaft fractures with casting versus nailing.

PATIENTS & METHODS:

Our Institutional Review Board approved the protocol for this project. A written informed consent was obtained from all the patients. The present study was a retrospective type of study conducted in ASRAM Hospital, Eluru, from January 2018 to December 2019. Demographic, medical history, imaging, and follow-up data were extracted from the medical records. The total tibia fractures were 198 out of which the total numbers of tibia shaft fractures were 92. A total number of 32 cases who met the inclusion criteria after excluding the patients, who come under exclusion criteria, were selected for detailed study. No fixed criteria were used to further divide the patients into two groups. 16 patients were treated with Closed Reduction and Cast Immobilization and 16 were treated with intramedullary interlocking nail and were followed for an average period of 6 months.

INCLUSION CRITERIA:

Patients of age above 16 years with diaphyseal fractures of the tibia. Closed, undisplaced, simple, transverse fractures of tibia shaft at least 5 cm distal to tibia tubercle and 5 cm above tibia plafond.

EXCLUSION CRITERIA:

Segmental loss of bone, diaphyseal fractures extending into ankle and knee joint, comminuted fractures, Pathological fractures, fractures with neurovascular damage, polytrauma patients, and open fractures.

Protocol for Conservative Management:

Under General Anaesthesia a long leg plaster of Paris cast was applied with proper moulding, after confirming the reduction under Image Intensifier. Rotation and lateral alignment were determined by comparison to the opposite extremity. If the radiographs showed acceptable position, the patient was mobilized non-weight bearing on axillary crutches, explained cast care and discharged for follow up in the clinic. If after reduction the x-rays revealed unsatisfactory reduction because of angulations, then cast wedging was used. However, more than 2 attempts to obtain and maintain a satisfactory reduction were considered as an indication for surgical stabilization. Open wedging was preferred to closed⁴. Operative treatment was considered if wedging of more than 10° was required. Patients were called after 3 weeks and above-knee plaster was removed. The fracture was assessed clinically for reduced abnormal mobility and radiological for callus formation. If there were signs of poor healing clinico-radiologically, then above knee plaster cast extended for another 4 weeks. If the stickiness of fracture was good enough, a PTB cast was applied and was allowed partial weight-bearing with walker or crutches thereafter the patients were assessed radio logically and clinically every month till fracture was united.

Protocol for intramedullary nailing:

All the patients were operated under general anaesthesia on a radiolucent fracture table in a supine position with tourniquet. Patellar tendon splitting approach, AO nail used after reaming medullary canal 1 mm more than the nail diameter (measured at isthmus in lateral view x rays leg) and with static interlocking. Patient mobilised weight bearing as tolerated once pain subsided postoperatively. Quadriceps exercises with knee and ankle movements were taught to patient .Patients were assessed clinically and radio logically at, 6 weeks, 3 months, and 6 months to assess the fracture union.

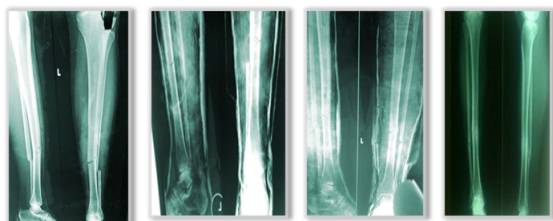
Functional outcome were graded according to Johner and wruhs criteria⁵.

Table No: 1 Showing Johner And Wruhs Criteria For Assessment Of Results

CRITERIA	EXCELLENT	GOOD	FAIR	POOR
NONUNION, OSTEITIS AMPUTATION	None	none	none	yes
DNVD	None	minimal	moderate	Severe
VARUS/VALGUS	None	20-50	60-100	>100
ANTEVERSION/ RECURVATION	00-50	60-100	110-200	>200
ROTATION	00-50	60-100	110-200	>200
SHORTENING	0-5mm	6-10mm	11-20mm	>20mm
KNEE MOBILITY	Normal	>80%	>75%	<75%
ANKLE MOBILITY	Normal	>75%	>50%	<50%
SUBTALAR JOINT	>75%	>50%	>50%	<50%
PAIN	None	occasional	moderate	Severe
GAIT	Normal	normal	insignificant limp	significant limp
STRENUOUS ACTIVITY	Possible	limited	severely limited	impossible

STATISTICAL ANALYSIS:

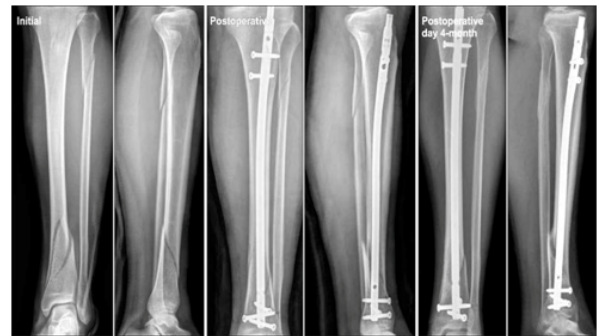Data was entered in Microsoft Excel 2019 software and analysed using MS Excel 2019 and descriptive statistical tools like Mean, Standard Deviation & T-test for testing two means were used to find out the “P” value



Initial Injury After Casting PTB Cast at 8 wks 6 Months follow up

Figure 1. Closed reduction and Casting.

Figure 2. Intramedullary Nailing



4 Months follow up

OBSERVATION AND RESULTS:

In our study total 32 patients were included which consists of 16 patients treated Conservatively and 16 patients treated with intramedullary interlocking nail .There were 25 male (13 in conservative group and 12 in surgical group) and 7 female (3 in conservative group and 4 in surgical group).In present study it is seen tibia shaft fractures are more common in males than in females. The majority of patients were in 20 to 50 years of age in both the groups. Road traffic accidents were the major cause of injury in both study groups. The site of fracture involved in both groups is as follows in table 2.

Table 2. Site of fracture involved.

Site of Fracture	Conservative	Intramedullary Interlocking nail
Proximal	3 (6.4%)	2 (3.2%)
Middle	9 (31.1%)	11 (37.2%)
Distal	4 (12.5%)	3 (9.6%)
Total	16 (50%)	16 (50%)

Partial weight-bearing was begun at a mean of 12.4 weeks (SD 3.1) in Conservative group and by 9.8 weeks (SD 2.4) in nailing group, the difference being highly significant statistically [T=3.037, & 2-Tailed P VALUE=0.0049 VHS].

Time-to-Full weight-bearing was at a mean of 19.8 weeks (SD 2.9) in the Conservative group and 15.6 weeks (SD 1.3) in nailing group, the difference of which was very highly significant statistically [T=5.24, P<0.0001 VHS].

Time taken for full knee and ankle range of motion in weeks is as below in table 3.

Table 3

STUDY GROUP	KNEE	ANKLE
Conservative group	15.8 weeks (SD=1.91)	20.6 weeks (SD=6.30)
Nailing group	2.7 weeks (SD=0.79)	2.5weeks (SD=0.63)

KNEE: T =20.38, P<0.0001 VHS; ANKLE: T=11.32, P<0.0001 VHS

The full range of both knee joint and ankle joint movements were achieved much early in the nailing group (2.7 wks.& 2.5 wks.) than in the Conservative group (15.8 wks.& 20.6wks), where the movements were not possible because of the cast. However, after the removal of the cast the full range of movements were achieved within an average of 3-4 weeks.

The mean time-to- Bone union in the Conservative group was 25.8 weeks (SD 1.77), Compared to 20.7 weeks (SD 1.44) in the nail group The difference was very highly significant statistically. [T=8.77,P<0.0001 VHS]

COMPLICATIONS:

Varus or valgusangulations occurred in 5 patients of the Conservative group and 2 patients of nailing group. Anterior or posterior angulations occurred in 4 patients of Conservative group and 1 patient in nailing Group. All the deformities in both the groups were within the acceptable range. Shortening ranging from 5-20mm was observed only in the Conservative group. The incidence of complications was higher in the Conservative group, but was not significant statistically.

In the Conservative group 2 delayed union cases , 1 Non union case, 1 case of significant displacement in cast was observed during follow up which were treated by Interlocking nailing.

In the nailing group, 1 patient had a superficial infection, which subsided subsequently with oral antibiotics and 1 patient had delayed union, which was treated by autologous bone grafting. None of the patients developed compartment syndrome, deep infection or implant failure. 4 of the patients (25 %) in the nailing group developed anterior knee pain.

The functional outcome at 6 months follow up according to Johner & Wruhs criteria was better in the nailing group in which 87.5% of the fractures had an excellent-good outcome and none of the patients had poor outcomes. Compared to nailing group, functional outcome in the Conservative group was excellent-good in only 50% of the patients, 37.5% had a fair outcome and 12.5% had poor outcomes.

DISCUSSION:

To compare the results after Intramedullary nailing and cast in treatment of tibia shaft fractures is difficult. To justify such a comparison, both groups must contain comparable fractures. Displaced, unstable fractures cannot be treated with a cast or brace alone, which means that they should be excluded from this group. Therefore, only stable fractures would be left in the cast group, which are no longer comparable with fractures in the nail group. Hence in this study, all fractures that were included were amenable equally for plaster cast treatment and Intramedullarynailing to obtain comparable groups of conservatively and operatively treated fractures.

The goal of our study is also to compare the results of treatment of stable fracture shaft of the tibia by either surgical or conservative methods, i.e., by either plaster cast or locked Intramedullary nailing in respect to early functional recovery and rehabilitation period and in a process to compare the merits and drawbacks of these two categories.

In Alhoet al. series, the tibia shaft fractures treated conservatively consolidated radiologically in the median of 17 weeks and those treated with nail required 14 weeks to consolidate⁶.In Hooper et al series tibia shaft fractures treated conservatively required 18.31 median weeks to unite and those treated with closed nailing required 15.71 median weeks⁷.In our study, the mean time taken for the bony union was 20.67 weeks in fractures treated with interlocking nailing, whereas the fractures treated with closed reduction and cast application united at a mean of 25.75 weeks. Thus in comparison to the above studies, the time required for the bony union in fractures treated surgically by locked IM nailing was less than in the fractures treated by the conservative method.

Alho et al. study, full weight-bearing was possible after median 90 days (90-270 days) in the conservatively treated group and in the nailed group after median 46 days (46-120 days)⁶. In our study, the full weight-bearing was possible by 15.6 weeks on an average in patients treated with nail. Patients treated with the cast were able to bear full weight at a mean of 19.8 weeks. In our study at 6 months of follow up surgically treated patients with nail had early recovery with shorter healing time and early return to work than casting patients.

In our study duration of stay in hospital, No of OPD visit , average x rays taken during follow up are more in surgically treated nailing patients than conservative treated casting patients. These results are comparable to study done by Hooper et al.

The varus deformity of 5-10 degrees in Gary J. Hooper et al. series was present in 18.18% of patients treated conservatively and none in patients treated surgically⁷. In the present study, 5-10 degrees varus was present in 37.5 % of patients treated conservatively and 12.5% of patients treated surgically. It is evident from these figures that varus deformity is more prominent in patients treated conservatively than in patients treated surgically by nail.

In Gary J. Hooper et al. series, anterior/posterior angulation was present in 3.03% of patients treated conservatively and none in the surgical group⁷. In our series, the figures were 25 % and 6.25 % respectively. Thus, it proves that anterior/posterior angulation is more common in patients treated conservatively than in patients treated surgically by nail.

In our study Shortening was observed more commonly in conservatively treated tibia shaft fractures than nailing patients.

Table 4. showing various deformities in both groups

Deformities (in no.)	Functional cast		Intramedullary nailing	
	Gary.J.H. et al	Our series	Gary.J.H.et. al	Our series
Varus/valgus	5-7.5	3	0	1
	7.5-10	3	0	1
	>10	3	0	0
Anterior/posterior angulation	5-7.5	0	3	0
	7.5-10	1	0	0
	>10	2	0	0
Shortening.	0.5 -1cm	9	5	1
	1-2cm	5	1	1
	>2cm	11	0	0

Anterior knee pain is common in tibia shaft fractures treated by nail. Katsoulis et al in⁸. Their study reported mean incidence of anterior knee pain was 47.4 % ranging from 10 % to 86 %. It was indicated anterior knee pain was due to prominent nail and transtendinous approach. In our study 4 patients (25 %) with nailing, anterior knee pain was found, which partly responded to rest, physiotherapy and analgesics.

Our functional outcome assessment is compared with Antti Alho et al study and was compared in Table 5 below. In the present study the excellent and good results together are 50% in casting method of treatment and 87.5% in the surgically treated nailing group.

Table No. 5 showing a comparison of functional results with Antti Alho series

Grading	CAST TREATMENT				INTRAMEDULLARY NAILING			
	Antti Alho		OUR STUDY		Antti Alho		OUR STUDY	
	NO	%	NO	%	NO	%	NO	%
Excellent	16	45.71	6	37.5	26	60.4	9	56.25
Good	6	17.14	2	12.5	12	27.9	5	31.25
Fair	11	31.42	6	37.5	5	11.6	1	6.25
Poor	2	5.71	2	12.5	0	0	1	6.25
Total	35	100	16	100	43	100	16	100

Thus, in our comparative study, short term results of treatment of stable fracture tibia surgically with interlocking nail appears to have better functional outcome than conservative treatment with a functional cast. However limitation of our study being long term follow up is required.

Better functional outcome was reported in studies conducted by Hooper et al, Bone et al , Alho et al in intramedullary nailing of tibia shaft fractures over casting however their study included tibia shaft fractures that were displaced, unstable and open^{6,7}. In a study by Bone et al revealed shorter time to union and shorter recovery in intramedullary nail compared to casting in tibia shaft fractures in short term, however there is no difference in functional outcome of nail versus casting in tibia shaft fractures after a follow up of 4.3 years⁹.

CONCLUSION:

On the basis of the present study, the incidence of delayed union, non-union, displacement and restricted range of motion of ankle and knee joints are common when these fractures are treated with a cast.

Closed reduction and cast treatment still have a place in the treatment of stable fracture shaft of the tibia in those patients who are not fit for surgery. It is less expensive, requires less hospital stay, with no infection. It can be advocated in the rural population and in poor patients provided patient is Cooperative to attend O.P.D for frequent follow-up and X-ray monitoring and accepts few degrees of malunion.

Treatment of Closed stable Tibia shaft fractures with Intramedullary Interlocking nail provides faster healing, more reliable alignment, earlier return to work and low incidence of severe complications and better functional results than cast treatment in short term follow up¹⁰.

In conclusion, the treatment of stable fracture shaft of tibia surgically with interlocking nail appears to be a suboptimal mode of treatment than treatment with cast.

REFERENCES:

1. Peter Larsen, Rasmus Elsoe, Sandra Hope Hansen, Thomas Graven-Nielsen, Uffe Laessoe, Sten Rasmussen. Incidence and epidemiology of tibial shaft fractures. *Injury, Int. J. Care Injured* 46 (2015) 746–750.
2. Joe Eric Gordon and June C. O'Donnell. Tibia Fractures: What Should be Fixed?. *J Pediatr Orthop* 2012;32:S52–S61.
3. Sarmiento A. A functional below-the-knee brace for tibial fractures. A report on its use in one hundred thirty-five cases. *J Bone Joint Surg Am.* 1970;52:295–311.
4. Christine A. Ho. Tibia Shaft Fractures in Adolescents: How and when can they be Managed Successfully with Cast Treatment?. *J Pediatr Orthop* 2016;36:S15–S18.
5. Johnner R and Wruhs O. Classification of tibial shaft fractures and correlation with results after rigid internal fixation. *Clin Orthop Related Research.* 1983; 178: 7-25.
6. Anttilo Alho, Jan. G. Benterud, Hans Erik Høgevoid, Arne Ekeland, Knut Stromsoe. Comparison of Functional Bracing and Locked Intramedullary Nailing in the Treatment of Displaced Tibial Shaft Fractures. *Clin Orthop Relat Res.* 1992; 277: 243-250.
7. Gary J. Hooper, Richard G Keddell, Jan D. Penny. Conservative management or closed nailing for tibial shaft fractures. *J Bone Joint Surg* Jan 1991; Vol-73- B, No 1:83.
8. Katsoulis E, Court-Brown C, Giannoudis PV. Incidence and aetiology of anterior knee pain after intramedullary nailing of the femur and tibia. *J Bone Joint Surg Br;* 2006,88:576–580.
9. Bone LB, Sucato D, Stegemann PM, Rohrbacher BJ. Displaced isolated fractures of the tibial shaft treated with either a cast or intramedullary nailing. An outcome analysis of matched pairs of patients. *J Bone Joint Surg Am;* 1997, 79:1336–1341.
10. William T. Obremskey, Norele Cutrera, Christopher M. Kidd. A prospective multicenter study of intramedullary nailing versus casting of stable tibial shaft fractures. *J Orthopaed Traumatol* (2017) 18:69–76.