



## PROSTHETIC REHABILITATION OF A POST EVISCERATION PATIENT WITH AN OCULAR PROSTHESIS: A CASE REPORT

### Prosthodontics

**Dr. Bhagyashree S. Dange\*** MDS Prosthodontics, Senior lecturer, Dr. D.Y.Patil Dental College and Hospital, Pimpri, Pune. \*Corresponding Author

### ABSTRACT

The loss of an eye is an emotional and psychological setback to the patient. An ocular prosthesis is created to restore the lost anatomical structure and to correct the cosmetic defect. All hope to bring such patients back to their accustomed and comfortable life-style rests on a cosmetically acceptable prosthesis. The goals of treatment with ocular prostheses are to restore facial aesthetics and self-esteem to anophthalmic patients. Fabricated in acrylic resin, artificial eyes should be aesthetically pleasing, scratch-resistant and adequately polished. This article describes a clinical report of rehabilitation of post evisceration patient due to glaucoma of right eye with custom made artificial prosthesis using stock eye shell that can create aesthetically pleasing results.

### KEYWORDS

Custom Made, Ocular Prosthesis, Evisceration, Stock Eye Shell

### INTRODUCTION-

It is the God given right of human being to appear human.<sup>1</sup> The face is a person's visiting card. We can hide everything but we can't hide our face and the facial expressions. Eyes are generally the first feature of the face that we notice and the presence of a pair of eyes is quite essential to maintain the balance and the aesthetics of the face. Loss of eye has a crippling and sub-conscious effect on the psychology of the patient.<sup>2</sup> The indication for the surgical removal of an eye are non-operable trauma like explosives, fights, infectious diseases, tumour or cancer, blindness, pain in the eye, the need for histological confirmation of a suspected diagnosis, possible prevention of sympathetic ophthalmic and cosmetic reasons.<sup>3</sup> Surgical procedures adapted for the removal of an eye are classified into three categories: evisceration, enucleation and exenteration.<sup>4,5</sup> Patients requiring treatment with custom ocular prosthesis are those who have lost ocular structure through orbital evisceration or enucleation. Evisceration is the removal of the contents of the globe, but leaving the sclera and on occasion the cornea in place.<sup>6</sup>

The need for an artificial eye can sometimes be fulfilled by stock prosthesis that comes in standard sizes, shapes, and colours. Stock ocular eye requires no special skills or materials for fabrication. They are inexpensive and less time consuming. However, in majority of cases of enucleation, custom ocular prosthesis has many advantages such as improved adaptation to underlying tissues, increased mobility of the prosthesis, and acceptable aesthetics due to better match of the size and colour of the iris and sclera.<sup>7</sup> Nevertheless, a custom prosthesis is more expensive than a stock prosthesis, and several steps are required for its fabrication.<sup>8</sup> The following clinical report of treatment for a patient demonstrates a custom-made ocular prosthesis for geriatric patient with a special emphasis on iris painting to create aesthetically pleasing results.

### CASE REPORT-

A 58 year old Male patient reported to the Department Of Prosthodontics and Maxillofacial Prosthetics with chief complaint of disfigurement as a result missing right eye due to severe case of glaucoma about 5 years back.( Fig.1) Patient revealed no relevant medical history. Ocular examination revealed a healthy intraocular tissue bed and adequate depth between the upper and lower fornices. The conjunctiva covering the posterior wall of the ocular defect showed synchronous movements. A custom made acrylic resin ocular prosthesis was planned, and the treatment procedure explained to the patient. There were no signs of any adhesion or dehiscence of conjunctiva and tissue bed was free of inflammation to start with the impression procedure for fabrication of ocular prosthesis.

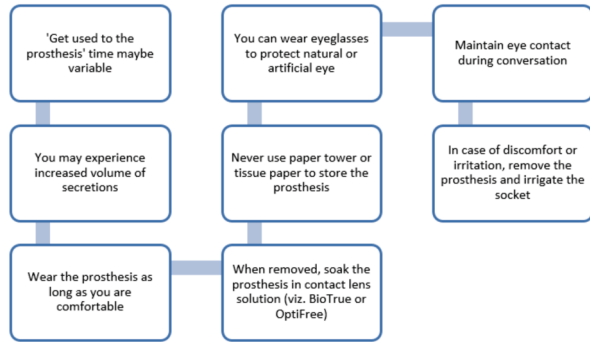
### Prosthesis Fabrication-

- 1) Petroleum jelly was applied to the eyebrows for the easy removal of the impression material after it sets.
- 2) During the impression procedure, the patient was seated in an upright position with the head supported by the head rest. This position allows the natural positioning of the palpebrae and surrounding tissue relative to the force of gravity.

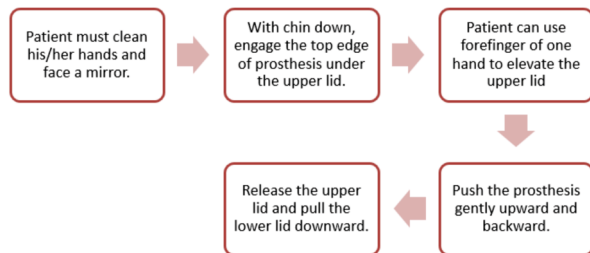
- 3) A 20 guage orthodontic wire was bent in order to form a circular loop to facilitate retention of impression material.
- 4) A primary impression of the anophthalmic socket was made using an impression method suggested by Allen and Webster.<sup>9</sup> Using a syringe, the irreversible hydrocolloid (Tropicalgin, Zhermack, Italy) was injected into the socket using disposable 5 ml syringe. Before this material achieves its final set, the pre-fabricated orthodontic wire loop was inserted into it. After the final set of the material, the impression was removed and examined for any deficiencies. (Fig. 2)
- 5) The impression was poured in Type III dental stone (Ultradock; Kalabhai, India) in two sections.
- 6) A clear self-cure acrylic (DPI, Chennai, India) custom tray was fabricated which will fit into the hub of disposable 5 ml syringe for making final impression. In the custom tray, 3-4 vent holes were made using straight fissure bur for allowing excess material to flow. Before making the final impression, the tray was inserted into the ocular cavity and was evaluated for the fit. The patient was asked to perform various ocular movements to ensure that there were no interferences. (Fig. 3)
- 7) Elastomeric impression material of light body consistency (Variotime, Kulzer International, India) was mixed and loaded in the syringe, and sufficient material was injected to fill the concavity of the tray slowly to avoid incorporation of air bubble. The tray was then reinserted and reoriented in the defect; sufficient material was injected to elevate the lid contour similar to the normal side. During this procedure patient was asked to perform ocular movements and close his eyes. Closure of the eyelids facilitates recording of palpebral contours for the prosthesis along with tissue surface of the defect and ocular movements provides recording of limiting tissues of the defect in their functional form.
- 8) Set impression was removed from the defect by applying slight oblique outward pressure or holding the material flash on outer surface with tweezers, (Fig. 4) and was poured in type IV die stone (Kalrock, Kalabhai, India) by using split cast technique to create mould cavity.
- 9) Molten modelling wax (MAARC, Vasai, Thane) was poured into stone mould to create a wax conformer or wax pattern of the prosthesis. The wax conformer was retrieved and the sharp edges were removed. It was then adjusted for the satisfactory fit, contours, and comfort at the wax conformer try in appointment. (Fig. 5)
- 10) Then, the dimensions of normal left eye were calibrated (Fig.6) and were transferred to a customised mould (Fig. 7) so that a stock iris disk can be cut out from a stock eye and attached to the wax conformer. The soft tissue contours and location of the iris were satisfactory. (Fig. 8)
- 11) The wax pattern was acrylized using heat cure clear acrylic resin (DPI, Chennai, India) and the prosthesis was finished and polished. Further characterization was done by attaching artificial veins to simulate that of the natural eye. External staining was also done using acrylic colours (Camlin, Mumbai, India).<sup>10</sup> The prosthesis was covered with a thin layer of wax and further acrylized. (Fig. 9)

12) Finally, the prosthesis was recovered from the flask, finished, polished and placed in the eye socket. (Fig.10)

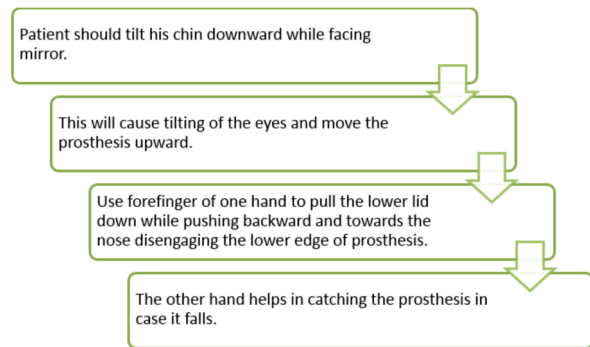
Post- insertion instructions given to the patient:<sup>11</sup>



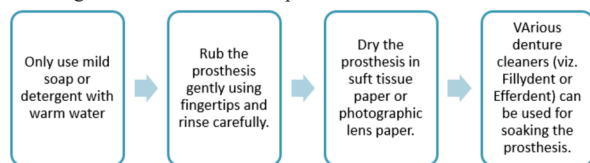
Replacement of the prosthesis-<sup>11</sup>



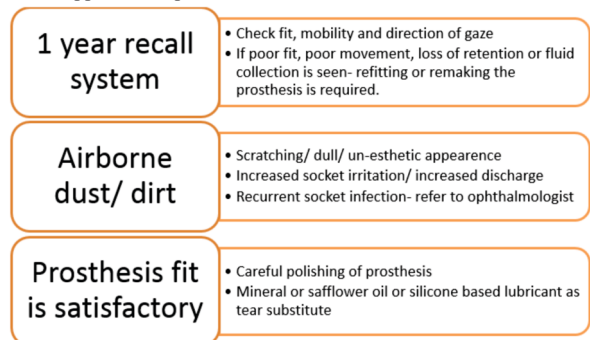
Removal of the prosthesis-<sup>11</sup>



Cleaning and Maintenance of the prosthesis-<sup>11</sup>



Recall appointment protocol-<sup>11</sup>



DISCUSSION-

Eye defects constitute an important maxillofacial deficiency, which requires prosthetic replacement.<sup>12</sup> So many methods and techniques have been used in fitting and fabricating ocular prosthesis. Empirically fitting a stock eye, modification of stock eye by making an impression of the ocular defect,<sup>13</sup> and fabrication of a custom ocular prosthesis<sup>14</sup> are

the most commonly used techniques. The fabrication of a custom acrylic eye provides more aesthetic and precise results because an impression establishes the defect contours and the iris and the sclera are custom fabricated. Moreover, a custom-made ocular prosthesis replicates the orientation, natural colour, contour, and size of the pupil and iris, providing realism and symmetry to the patient's face. In addition, it improves the fit of the prosthesis by gaining the intimate tissue adaptation.<sup>8</sup> Custom staining and characterization improves aesthetics and recording of defect tissues in a functional state, prosthesis moves according to ocular movements and permits competency of eyelids in closure.<sup>15</sup>

CONCLUSION-

Restoration of ocular defects often indicated not only to prevent supporting tissue changes, but also to avoid distress to the patient. A thorough knowledge of the regional anatomy and recent developments in the field is prudent.<sup>15</sup> The prosthetic rehabilitation of anophthalmic socket is a challenging process. In addition to aesthetics, comfort of the prosthesis wearer should be given prime importance.<sup>16</sup> Custom made ocular prosthesis prove to a low cost alternative to traditional stock glass or acrylic shell prosthesis. It has a greater biocompatibility also rendering it as a better treatment option in evisceration patients. Ocular rehabilitation restores the compromised aesthetics, maintains the normal physiology of the ocular area, and increases the social life and self-esteem of the patient.

REFERENCES-

- Chalian VA, Drane JB, Standish SM. Maxillofacial Prosthetics- Multi-disciplinary Practice. Waverly Press 1972.
- Rajiv Kumar Gupta ,T. V. Padmanabhan. J Indian Prosthodont Soc (Apr-June 2012) 12(2):108–112.
- Raflø GT (1995) Enucleation and evisceration. In: Tasmun W, Ja-eger E (eds) Duane's clinical ophthalmology, vol 5, Rev edn. Lippincott-Raven, Philadelphia, pp 1–25
- Perman KI, Baylis HI (1988) Evisceration, enucleation, and exenteration. Otolaryngol Clin North Am 21:171–182
- Shenoy KK, Venkat Ratna NP (2007) Ocular impression: an overview. J Indian Prosthodont soc 7(1):5–7
- Taylor TD (2000) Clinical maxillofacial prosthetics, 3rd edn. Quintessence Publishing Co. Inc, Chicago, pp 265–276
- Sidharth Jain, Sumit Makkar , Sharad Gupta, Akshay Bhargava. J Indian Prosthodont Soc (July-Sept 2010) 10(3):190–193.
- Mathew FM, Smith MR, Suttion JA et al (2000) The ocular impression: a review of the literature and presentation of an alternate technique. J Prosthodont 9:210–216.
- Allen Lee, Webster HE. Modified Impression Method of Artificial Eye Fitting. American Journal of Ophthalmology 1969; 67:2:189-218.
- Firtell DN, Anderson CR, Donnan ML (1975) Vein application technique for ocular prostheses. J Prosthet Dent 34:192
- Parr GR, Goldman BM, Rahn AO. Postinsertion care of ocular prosthesis. Jomal of Prosthetic Dentistry 1983;49:2:220-224
- Shivji AR, Bhat S, Shetty P: Prosthodontic management of an ocular defect—a case report. JIPS 2001;1:33-35
- Taicher S, Steinberg HM, Tubiana I, Sela M (1985) Modified stock eye ocular prosthesis. J Prosthet Dent 54:95–98
- Benson P (1977) The fitting and fabrication of a custom resin artificial eye. J Prosthet Dent 38:532–538.
- Tripuraneni SC, Vadapalli SB, Ravikiran P, Nirupama N. An innovative impression technique for fabrication of a custom made ocular prosthesis. Indian J Ophthalmol 2015;63:545-7.
- Kavlekar AA, Aras MA, Chitre V. An innovative and simple approach to fabricate a hollow ocular prosthesis with functional lubricant reservoir: A solution to artificial eye comfort. J Indian Prosthodont Soc 2017;17:196-202.