



## CEREBRAL COLLATERAL CIRCULATION IN ACUTE STROKE WITH OCCLUSIVE INTERNAL CAROTID ARTERY DISEASE- CASE REPORT

### Neurology

**Dr Rahul Pathak\*** DM Neurology, FINS, Interventional Neurologist, Ramkrishna Care Hospital (RKCH), Raipur. \*Corresponding Author

**Dr Komal Pathak** Ophthalmologist, Udayachal Charitable Eye Hospital, Rajnandgaon.

**Dr Lokesh Chandra Sen** Resident doctor- RKCH, Raipur.

### ABSTRACT

- Acute brain infarction due to carotid artery occlusion has been associated with poor outcome in the absence of cerebral collaterals. The incipient development of collaterals does not guarantee their persistence while available data are strongly indicative that good collateral flow is key in cerebral perfusion and in reducing infarct size, this knowledge has resulted in only limited therapeutic applications.

### KEYWORDS

acute stroke, cerebral collaterals, internal carotid artery occlusion, external carotid artery (ECA), internal carotid artery (ICA).

### INTRODUCTION -

Cerebral collateral circulation has been reported to alter the risk of stroke in many studies. The circle of Willis constitutes the main network of collateral circulation and is immediately available to maintain perfusion in case of acute large artery occlusion, while other collateral networks are also available but optimal functioning may develop over time (1). In patients with occlusion of the internal carotid artery (ICA), the collateral circulation plays a pivotal role in the pathophysiology of cerebral ischaemia (2). Inadequate collateral blood flow distal to the ICA occlusion may be due to poor function of collateral pathways. In ICA occlusion, the circle of Willis, including the anterior and posterior communicating arteries, is the major collateral pathway that can compensate for decreased cerebral perfusion pressure rapidly. While collateral pathways through the ophthalmic artery and leptomeningeal vessels may be recruited when there is inadequate collateral flow through the circle of Willis (2). Thus, inadequate function of willisian collaterals, which may lead to the recruitment of ophthalmic or leptomeningeal collaterals, may cause haemodynamic impairment.

We report a case of middle age male with left middle cerebral artery acute ischemic stroke with complete occlusion of left internal carotid artery with robust collaterals and his clinical aspect.

### Case Report-

A 58 yr male was admitted to emergency department with sudden onset of headache, giddiness, right sided weakness and speech difficulty since 2 hour. Patient was chronic alcoholic, and hypertensive. On admission patient's conscious level was equal to a GCS (E4V5M6) score of 15 with power of right upper and lower limb 3/5. Blood pressure was 110/80 mmHg. A 12-lead ECG was unremarkable. Initial brain non-contrast CT scan showed subtle hypodensity in left medial basal ganglia without any evidence of hemorrhage (Fig1). The patient was diagnosed as an acute ischemic stroke and there were no other contraindications, making the patient eligible for thrombolysis. The patient was given rt-PA (Alteplase: 0.6mg/kg) intravenously according to Japanese guideline for thrombolysis in patients with acute ischemic stroke.

CT Angiography was done and showed nonenhancement of left internal carotid artery from the bifurcation of common carotid artery to supraclinoid segment (Fig2 and 5). Bilateral common carotid artery, right sided carotid bifurcation, right internal and external carotid and bilateral vertebral arteries had normal flow (Fig2). Left middle cerebral artery (MCA) was supplied by right ICA through anterior communicating artery (ACOM) (Fig3, 4 and 5(a) and 5(b)). Transthoracic echocardiography revealed mild diastolic dysfunction with an ejection fraction of 60%. Post thrombolysis CT head showed no haemorrhage (Fig6). Patient was managed with antiplatelets, anticoagulant, lipid lowering drugs and other supportive management. On progressive days, weakness was improved significantly and patient was discharged after 1 week with power 5/5.

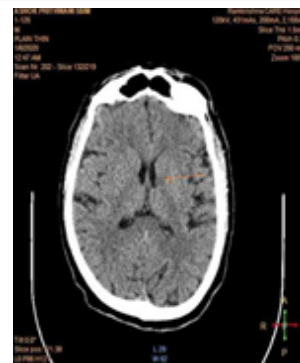

Fig-1 Hypodensity In Left Medial Basal Ganglia

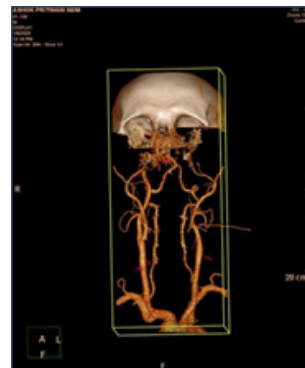


Fig2-3d CTA Showing Complete Occlusion Of Left ICA From Origin.

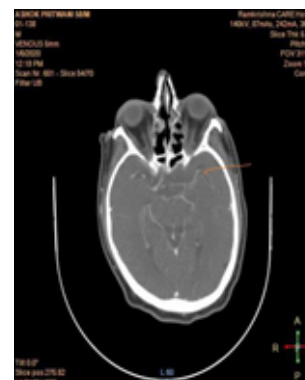

Fig3-partial Recanalization Of Left Middle Cerebral Artery Through Anterior Communicating Artery Postthrombolysis

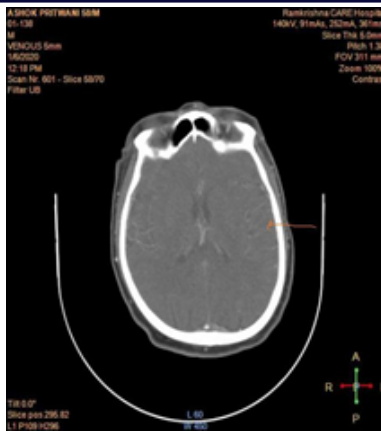

Fig-4 Normal Filling Of Left Cortical Branches Distally

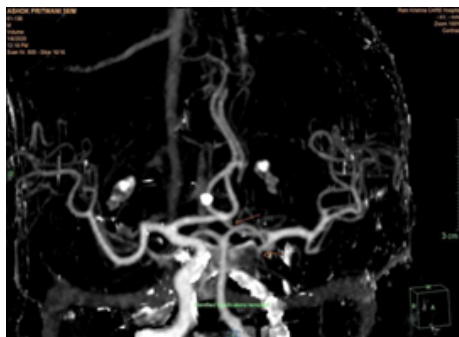


Fig-5(a) Fluoroscopic Angiography Shows Willisian Collateral Supplying Left Middle Cerebral Artery Distally While Complete Occlusion Of Left ICA Upto Supraclinoid Segment (arrow).

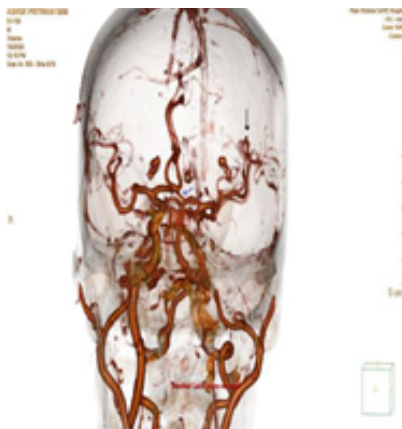

Fig-5(b)-3d CTA Shows Willisian Collateral Supplying Left Middle Cerebral Artery And Distal Cortical Branches (black Arrow) through Anterior Communicating Artery (ACOM) (blue Arrow).

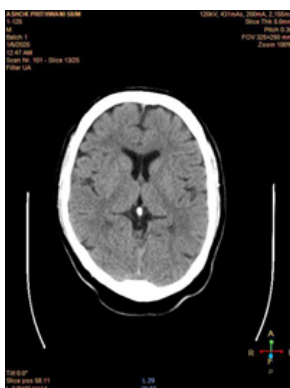

Fig-6 CT Head -post Thrombolysis (day1)

**DISCUSSION -**

Recent advances in imaging techniques have allowed for prompt evaluation of cerebral perfusion, and indirectly, the status of collateral circulation and provide valuable anatomical and functional information(1). However evaluation of the cerebral collateral circulation may not alter the treatment for most patients with occlusive carotid artery disease, but it may serve a prognostic role and in a selected group of patients and may provide additional information for risk stratification and therapeutic decisions(2).

The protective role of the cerebral collateral circulation depends on several factors including anatomical variations, systemic arterial pressure, age and the rate of development of occlusion and collaterals from the external carotid artery to the petrous segment of the internal carotid artery. After occlusion of a large artery, the subsequent drop in perfusion pressure distally generates a pressure gradient between neighboring arterial fields, resulting in changes in flow direction and rate; collateral flow changes occur almost immediately, within 1-4 seconds(1).

Cerebral collateral circulation has been reported to alter the stroke risk(3). Distal fragmentation of a thrombus within the parent vessel may occlude distal branches supplying retrograde collateral flow from cortical arteries. Hemodynamic fluctuation may influence the endurance of collaterals and possibly impairment of cerebral blood flow(3). The efficacy of collateral vessels likely depends on age, duration of ischemia, and associated comorbidities (3). The presence of collaterals on cerebral angiography has been associated with a lower risk of hemispheric stroke and transient cerebral ischemia in patients with carotid stenosis(4).

Apart from circle of willis, ophthalmic and leptomeningeal collaterals, other cerebral collateral may include - 1) ipsilateral vertebral artery – occipital artery – ECA – ICA, 2) ipsilateral thyrocervical trunk or costocervical trunk – ascending cervical artery or deep cervical artery – occipital artery – ECA – ICA, 3) contralateral ECA – contralateral superior thyroid artery – ipsilateral superior thyroid artery – ipsilateral ECA – ICA, and 4) ipsilateral thyrocervical trunk – inferior thyroid artery – superior thyroid artery – ECA – ICA(5).

With the progressive degrees of carotid stenosis presence of collateral circulation was found to increase ; next to nil collaterals were seen in patients with no stenosis, whereas collaterals were seen in more than 50% of patients with the most severe stenosis(6). Rate of development of carotid occlusion may also play pivotal role in development of persistent collaterals.

**CONCLUSION**

In those developing carotid independence intervention is not needed while with largely carotid dependence intervention could be feasible and justified. Different collateral circulation pathways, and to analyse how compensation affects patients' neurological symptoms, benefits from invasive and noninvasive treatment and prognosis need further research. Presence of primary collaterals in acute stroke with complete internal carotid artery occlusion remains to be a good prognostic factor along with thrombolysis.

**Disclosure Statement-** The authors have no conflicts of interest, nor have received any funding or sponsorship arrangements related to this research. developing carotid independence, no further intervention is needed, whereas in the less fit group who remain largely dependent on the remaining carotid artery, surgical intervention could be justified.,

**Funding Sources Statement -** The authors did not receive any funding support or sponsorships during the conduct of this research

**REFERENCES -**

- 1) Cerebral Collateral Circulation in Carotid Artery Disease José R. Romero\*, Aleksandra Pikula, Thanh N. Nguyen, Yih Lin Nien, Alexander Norbash and Viken L. Babikian - *Current Cardiology Reviews*, 2009, 5, 279-288
- 2) Pattern of collaterals, type of infarcts, and haemodynamic impairment in carotid artery occlusion - H Yamauchi, T Kudoh, K Sugimoto, M Takahashi, Y Kishibe, H Okazawa - *J Neurol Neurosurg Psychiatry* 2004;75:1697-1701 doi:10.1136/jnnp.2004.040261
- 3) Angiographically Defined Collateral Circulation and Risk of Stroke in Patients With Severe Carotid Artery Stenosis - Robert D. Henderson, FRACP; Michael Eliasziw, PhD; Allan J. Fox, MD; Peter M. Rothwell, MD; Henry J.M. Barnett, MD; for the North American Symptomatic Carotid Endarterectomy Trial (NASCET) Group - *Stroke*. 2000;31:128-132.
- 4) Collateral Circulation - David S. Liebeskind, MD - *Stroke*. 2003;34:2279-2284.
- 5) Four collateral circulation pathways were observed after common carotid artery occlusion - Jianan Wang, Chengrong Zheng, Bei Hou, Aihua Huang, Xiongwei Zhang and Bin Du - Wang et al. *BMC Neurology* (2019) 19:201 https://doi.org/10.1186/s12883-019-1425-0
- 6) The clinical role of the cerebral collateral circulation in carotid occlusion- John W. Norris, MD, FRCP, Adam Krajewski, MD, and Natan M. Bornstein, MD, Toronto, Ontario, Canada - *J Vasc Med Biol* 1990;12:113-8.