



## EVALUATION OF THE ROLE OF 3 TESLA MRI AND ECHOCARDIOGRAPHY IN ASSESSING FUNCTIONAL LEFT VENTRICULAR PARAMETERS IN PATIENTS WITH CHRONIC ISCHEMIC CARDIOMYOPATHY

### Cardiology

<b>Dr. Smit Shrivastava*</b>	Professor and Head, Department of Cardiology, Advanced Cardiac Institute, Pt JNM Medical College, Raipur, Chhattisgarh, India. *Corresponding Author
<b>Dr. Satya Bhuvan Singh Netam</b>	Professor and Head, Department of Radiology, Pt JNM Medical College, Raipur, Chhattisgarh, India.
<b>Dr. Chandan Wilson Fernandes</b>	Resident Medical Officer, Department of Radiology, Pt JNM Medical College, Raipur, Chhattisgarh, India.

### ABSTRACT

**Background:** Multiple imaging modalities are available to assess dysfunctional yet viable myocardium; these include Echocardiography, Single Photon Emission Computed Tomography (SPECT) Imaging, Positron Emission Tomography (PET) and Cardiac Magnetic Resonance Imaging (CMRI). The aim of this study is to evaluate the role of 3T CMRI and Echocardiography in the evaluation of patients with Ischemic Cardiomyopathy for left ventricular function at both regional and global levels including the calculation of ejection fraction and segmental wall motion abnormalities based on the 17-segment model of the American Heart Association (AHA).

**Material And Methods:** This was a Hospital Based Cross Sectional Observational Study, conducted in Department of Cardiology and Department of Radiology, Advanced Cardiac Institute, PT JNM Medical College and Dr. B R A M Hospital between July 2017 to September 2018 in 24 patients with known Ischemic Cardiomyopathy, assessed by Echocardiography and 3T CMRI for Left Ventricular Functions.

**Results:** The study showed that the mean LVEF by CMRI was 34.08% and the mean LVEF by Echocardiography was 33.27% with a mean difference of 2.89%, standard deviation of bias was 0.856 and 95% limits of agreement were 1.212-4.568. A poor to fair level of agreement was noted using Cohen's Kappa ( $\kappa$ ) is 0.375, Standard Error (SE) of  $\kappa$  is 0.035, P value of  $< 0.0005$ . The results showed that CMRI had a sensitivity of 94.7%, specificity of 44.1%, Positive Predictive value (PPV) of 65.5% and Negative Predictive value (NPV) of 88.2%. The Echocardiography had a sensitivity of 80%, specificity of 32.4%, with a PPV of 52.8% and a NPV of 63.2%. CMRI has an Excellent Negative Predictive Value of 88.2% which means that 88.2% of the Vascular Territories without SWMA on CMRI did not have a scar.

**Conclusions:** CMRI and Echocardiography are comparable for assessing Global Left Ventricular functions. There is only a fair degree of agreement between CMRI and Echocardiography for analysis of segmental wall motion abnormalities. CMRI may be more accurate in ruling out a scarred myocardium as compared to Echocardiography, owing to High Negative Predictive value.

### KEYWORDS

Ischaemic Cardiomyopathy, Cardiac Magnetic Resonance Imaging, Echocardiography, Left Ventricular Function, Regional Wall Motion Abnormality.

### BACKGROUND

Ischemic Cardiomyopathy has been used to describe significantly impaired left ventricular function (left ventricular ejection fraction [LVEF]  $\leq 35$  to 40 percent) due to Non-Viable or Hibernating Myocardium that results from Coronary Artery Disease.<sup>1</sup> Multiple Imaging Modalities are available to assess dysfunctional yet viable myocardium; these include Echocardiography, Single Photon Emission Computed Tomography (SPECT) Imaging, Positron Emission Tomography (PET) and Cardiac Magnetic Resonance Imaging (CMRI).<sup>2</sup> Transthoracic Echocardiography remains the First-Line Imaging Modality for assessing Cardiomyopathy at present.<sup>3</sup> Cardiac Magnetic Resonance Imaging (CMRI) is helpful in identifying ischaemia as the Aetiology Of Cardiomyopathy in patients who present with de novo heart failure without a clinical or Electrocardiographic suggestion of an Ischaemic event.<sup>4</sup> The aim of this study is to evaluate the role of 3T CMRI and Echocardiography in the evaluation of patients with Ischemic Cardiomyopathy for Left Ventricular Function at both regional and global levels including the calculation of ejection fraction and segmental wall motion abnormalities based on the 17 segment model of the American Heart Association (AHA).

### MATERIAL AND METHODS

#### Study Design

Cross sectional observational study

This study was initiated after obtaining Institutional Ethics Committee approval for the protocol. This was a Hospital Based Cross Sectional Observational Study, conducted in Department of Cardiology and Department of Radiology, Advanced Cardiac Institute, PT JNM Medical College and Dr. B R A M Hospital between July 2017 to September 2018 in 24 patients with known Ischemic Cardiomyopathy based on Clinical Symptoms And Documented LV Dysfunction, defined as an LV Ejection Fraction less than or equal to 45% by Echocardiography or History Of Coronary Artery Bypass Grafting (CABG), Percutaneous Coronary Intervention (PCI) or Myocardial Infarction (MI). The patients unwilling to take part in the study, or with acute Myocardial Infarction and those with contraindications to CMRI

were excluded from the study.

#### Imaging Protocols

Echocardiography  
Echocardiography Imaging was performed on Philips EPIQ 7 Echocardiography Machine (Koninklijke Philips N.V). Images were obtained in standard long and short axis, 4- and 2-chamber views. Two to three cardiac cycles were obtained for the assessment of segmental wall motion at apex, mid cavity and base of the left ventricle. LVEF was calculated by the biplane method of discs (modified Simpson method) using area tracings of the LV cavity via 4- and 2-chamber planimetry of the left ventricle.

Regional evaluation of LV function was determined based on Qualitative Visual Assessment of Wall Thickening and Endocardial Motion of each Myocardial Segment visualized in multiple views utilizing the American Society of Echocardiography Seventeen Segment Model Of The Heart, and the use of a Semiquantitative Wall Motion Score (1-normal or hyperkinetic, 2-hypokinetic [reduced thickening], 3-akinetic [absent or negligible thickening], and 4-dyskinetic [systolic thinning or stretching]) assigned to each segment for calculation of LV wall motion score index as the average of the scores of all visualized segments.<sup>5</sup>

#### Cardiac MRI

The study was performed on a SIEMENS MAGNETOM SKYRA 3T MR SYSTEM (Siemens Healthcare, Germany). Localizer sequences in three orthogonal planes were taken followed by standard cardiac 2-chamber and 4-chamber views as well as short axis (SA) cine images in steady state free precession (SSFP). All images were acquired using a phased-array 16 channel body coil during single breath-holds (end expiratory of about 9–13 s) with ECG gating. The Late Gadolinium Enhancement (LGE) images were obtained 10 min after the injection of the contrast material using an Inversion Recovery (IR) sequence. Imaging of left ventricle was from base to the Apex and the Acquisition was performed in SA view and additionally in a four-chamber view. Images were acquired during end-expiration breath holding period.

**RESULTS****Global LVEF**

The baseline characteristics of the study population was dominated by males, subject in 5th decade of life, hypertension and diabetes prevalence and post revascularization.

**Table 1 The Baseline Characteristics Of The Study Population**

Baseline Characteristics	Percent (n)	Total n=24
Age	<50 years	37.5 (9)
	51-60 Years	25.0 (6)
	>60 Years	37.5 (9)
Gender	Male	62.5 (15)
	Female	37.5 (9)
Hypertension	Present	70.8 (17)
	Absent	29.2 (7)
Diabetes	Present	62.5 (15)
	Absent	37.5 (9)
Smoking	Present	54.2 (13)
	Absent	45.8 (11)
Revascularization (PCI/CABG)	Present	62.5 (15)
	Absent	37.5 (9)

Among the 24 patients, the mean LVEF by CMRI was 34.08% and the mean LVEF by Echocardiography was 33.27%. The mean of the difference between the Ejection Fractions by Echocardiography and CMRI was 2.892% with a Standard Deviation (SD) of 0.856 with a 95% confidence interval of 1.214 to 4.569%.

**Table 2 The Mean LVEF By Echocardiography & The Mean LVEF By CMRI**

Measure	Value
LVEF by echocardiography (%)	33.27
LVEF by CMRI (%)	34.08
Difference of the Mean	2.89
SD	0.856
95% Limits of Agreement	1.214 – 4.569
<b>LVEF is expressed as mean (SD).</b>	
<b>Bias=average of differences.</b>	
<b>95% Limits of Agreement= bias plus or minus 1.96 times SD.</b>	

Table 2. The was 34.08% and the mean LVEF by Echocardiography was 33.27%. The mean of the difference between mean LVEF by CMRI the Ejection Fractions by Echocardiography and CMRI was 2.892% with a Standard Deviation (SD) of 0.856 with a 95% Confidence Interval of 1.214 to 4.569%.

The agreement from the Bland-Altman plot between Echo cardiography and CMRI for the estimation of ejection fraction (LVEF) was noted. Among the 24 patients, the mean LVEF by CMRI was 34.08% and the mean LVEF by Echocardiography was 33.27% with a mean difference of 2.89%. SD of bias was of 0.856 and 95% limits of agreement were 1.212-4.568.

**Table 4 Per-segment Agreement Between Echocardiography And CMRI**

			ECHOCARDIOGRAPHY				Total
			Normal	Hypokinesia	Akinesia	Dyskinesia	
MRI	Normal	Count	134	36	13	6	189
		% of Total	32.8%	8.8%	3.2%	1.5%	46.3%
	Hypokinesia	Count	27	73	16	2	118
		% of Total	6.6%	17.9%	3.9%	.5%	28.9%
	Akinesia	Count	13	30	28	3	74
		% of Total	3.2%	7.4%	6.9%	.7%	18.1%
	Dyskinesia	Count	11	1	10	5	27
		% of Total	2.7%	.2%	2.5%	1.2%	6.6%
Total		Count	185	140	67	16	408
		% of Total	45.3%	34.3%	16.4%	3.9%	100.0%

Table 4. Per-segment agreement between Echocardiography and CMRI in the detection of segmental wall motion abnormality in the 408 segments examined in 24 patients.

A kappa value of 0.375 shows that there is a poor to fair positive strength of agreement in SWMA analysis by CMRI and echocardiography. Furthermore, since  $p = 0.000$  (i.e.,  $p < 0.0005$ ), kappa ( $\kappa$ ) coefficient is statistically significantly different from zero.

The results showed that CMRI had a sensitivity of 94.7%, specificity of

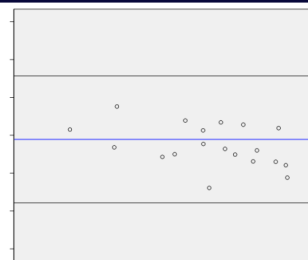
**Figure 1 Bland–altman Plot For Agreement Between Echocardiography And CMRI**

Figure 1. Bland–Altman plot for agreement between Echocardiography and CMRI as regards estimation of ejection fraction.

The Intraclass correlation coefficient results also showed that the estimated reliability between LVEF by echocardiography and LVEF by CMRI is 0.929 with 95% CI (0.845-0.968). It shows that there is an excellent reliability between LVEF by echocardiography and LVEF by CMRI ( $p < 0.001$ ).

Table3 Intraclass Correlation Coefficient							
	Intraclass Correlation	95% Confidence Interval		F Test with True Value 0			
		Lower Bound	Upper Bound	Value	df1	df2	Sig
Single Measures	0.929	0.845	0.968	27.181	23	24	0.000
Average Measures	0.963	0.916	0.984	27.181	23	24	0.000

**Table 3. Intraclass correlation coefficient showing excellent reliability for LVEF estimated by Echocardiography and CMRI.****Segmental Wall Motion Abnormality (SWMA)**

Using the 17-segment model of the American Heart Association, segmental wall motion abnormality was assessed in all the 24 patients using both Echocardiography and CMRI. SWMA was graded on a scale of 1 to 4 (1- Normal, 2- Hypokinesia, 3- Akinesia and 4- Dyskinesia). Per-segment agreement between Echocardiography and CMRI as regards the detection of segmental wall motion abnormality in the 408 segments was examined in 24 patients. A poor level of agreement was noted using Cohen's Kappa ( $\kappa$ ) is 0.375, standard error (SE) of  $\kappa$  is 0.035, P value of  $< 0.0005$ . Concordant segments between CMRI and Echocardiography were as follows: 134 segments (32.8%) of 408 segments showing no wall motion abnormality by the two modalities, 73 segments (17.9%) showing hypokinesia, 28 segments (6.9%) showing akinesia, and 5 segments (1.2%) showing dyskinesia.

44.1%, Positive Predictive Value (PPV) of 65.5% and Negative Predictive Value (NPV) of 88.2%. The Echocardiography had a sensitivity of 80%, specificity of 32.4%, with a PPV of 52.8% and a NPV of 63.2%. CMRI has an excellent Negative Predictive Value of 88.2% which means that 88.2% of the Vascular Territories without SWMA on CMRI did not have a scar.

Table 5 Cohen's Kappa Co-efficient( $\kappa$ )				
Kappa Value	Asymp. Std. Error <sup>a</sup>	Approx. T <sup>b</sup>	Approx. Sig.	

Measure of agreement	0.375	0.035	11.350	0.000
No of segments examined = 408				

**Table 6 The Sensitivity, Specificity, PPV and NPV of CMRI And Echocardiography In The Prediction Of Presence Of Scar On The Basis of SWMA.**

Parameters	Sensitivity	Specificity	Positive Predictive Value	Negative Predictive Value
MRI	94.7%	44.1%	65.5%	88.2%
95% Confidence Interval	82.25%-99.36%	27.19%-62.11%	58.2%-72.05%	64.88%-96.82%
Echocardiography	80%	32.4%	52.8%	63.2%
95% Confidence Interval	63.06%-91.56%	18.01%-49.79%	45.89%-59.66%	43.28%-79.39%

## DISCUSSION

Patients with Ischemic Cardiomyopathy have many treatment options that are tailored according to every patient. These include Revascularization (CABG or PCI), Medical Therapy or recent techniques including Cell Transplantation or Even Cardiac Transplant. So, viability assessment is crucial to identify patients who have dysfunctional yet viable myocardium from those having a non-viable myocardium. Multiple imaging modalities are available to assess dysfunctional yet viable myocardium; these include Echocardiography, Single Photon Emission Computed Tomography (SPECT) Imaging, Positron Emission Tomography (PET) and CMRI. The most important predictors of myocardial viability are regional contractility at rest. The aim of different treatment strategies is to preserve the contractile function of heart. Myocardial function can be assessed by CMRI and Echocardiography. The latter is the most widely used technique for evaluating LV function. Its advantages include easy performance as a bedside rapid screening tool, no exposure of the patients to radiation and its cheap cost.<sup>6</sup> However, its disadvantages are difficulties in defining endocardial contours in patients with limited image quality with Poor Echocardiography Imaging Window especially seen in patients having Advanced Pulmonary Disease, High Body Mass Index, and those who have undergone Thoracic Surgery.

In our study, the mean LVEF by CMRI was 34.08% and the mean LVEF by Echocardiography was 33.27% with a mean difference of 2.89%, Standard Deviation of bias was of 0.856 and 95% limits of agreement were 1.212-4.568. In a study by Yang, the mean difference of ejection fractions by CMRI Echocardiography was 2.892% with a Standard Deviation of 0.856.<sup>7</sup> Hoffmann in their study found that the mean difference between LVEF defined by Echocardiography Images and LVEF by CMRI was below 5%.<sup>8</sup> In the study done by Dewey, the LVEF comparison of non-contrast 2D Echocardiography with CMRI was fairly accurate for assessment with limits of agreement of 21.2% which is far higher than our study.<sup>6</sup> Gardner found that LVEF correlated moderately well between CMRI and Echocardiography, in agreement with the conclusions from our study.<sup>9</sup> Grover stated that CMRI is highly superior to 2D-echocardiography, when examining global LV function and is better for follow-up without cumulative radiation exposure.<sup>10</sup> Its accuracy in the evaluation of Left Ventricular Function makes it the reference standard for all imaging modalities.

In our study, the detected SMWA on CMRI by territory for Prediction of Scar Tissue by CMRI for the assessment of contractile reserve in collectively the three Vascular Territories in the 24 patients showed 55 territories of 72 territories with SWMA, whereas 36 of them showed scar by LGE and 19 showed no scar. 17 segments showed no SWMA whereas only 2 of them showed scar by CMRI. So, sensitivity of 94.7% with 95% CI of 82.25-99.36% and NPV of 88.2% with 95% CI of 64.88%-96.82% were obtained. Yang also compared 2D-echocardiography with gradient-echocardiography CMRI for the evaluation of SWMA in patients with good and poor echocardiography image quality.<sup>7</sup> The authors found good agreement ( $r = 0.79$ ) regarding SWMA depiction between echocardiography and CMRI in patients with good echocardiography image quality while the patients with poor echocardiography image quality, MR imaging was superior for the visualization of wall segments. Ozben found that combining LGE and segmental wall motion assessment by CINE CMRI yields better information about contractile reserve.<sup>11</sup> In another study by Gerber, it was found that segments showing transmural hyper enhancement had no significant inotropic reserve when assessed with low-dose

dobutamine-tagged CMRI, and non-transmural hyper enhancement showed contractile reserve, consistent with residual viability.<sup>12</sup> In our study, we detected SMWA by echocardiography for the prediction of scar tissue by CMRI showing 53 territories of 72 territories with SWMA whereas 28 of them showed scar by LGE and 25 showed no scar and 19 segments showed no SWMA whereas only 7 of them showed scar by CMRI. So, sensitivity of 80% with 95% CI of 63.06-91.56% and NPV of 63.2% with 95% CI of 43.28-79.39% were obtained. So, generally the evaluation of SWMA by Echocardiography at rest in combination with LGE CMRI can define the contractile reserve with improved accuracy.

## Limitations Of The Study

The sample size of the study was relatively small. A study conducted over a larger population and for a longer period of time would have consequently yielded more accurate information.

## CONCLUSIONS

CMRI and echocardiography are comparable for assessing global left ventricular functions. The echocardiography offers easy performance as a bedside rapid screening tool without radiation exposure and at less cost. CMRI was proved to be superior to Echocardiography in functional and segmental evaluations. LGE can provide information about myocardial viability as well as in evaluating the transmural extent of myocardial scar.

On comparing the results of CMRI and Echocardiography Regarding Global LV Functional (LVEF), high concordance between the two modalities was noted with mean difference of 2.892%. However, as regards to the analysis of segmental wall motion abnormalities by cine CMRI and Echocardiography, there is only a fair degree of agreement between CMRI and Echocardiography. With a High Negative Predictive value of 88.2%, the territories with Normal Wall Motion on CMRI have a higher likelihood of not having a Myocardial Scar. The Negative Predictive Value for Echocardiography is only 63.2%. CMRI may therefore, be more accurate in ruling out a Scarred Myocardium as compared to Echocardiography.

A combination of Echocardiography and CMRI can complement in evaluating the Cardiac Contractile reserve as global and segmental function for easy, rapid and cheap versus accurate yet expensive modality as needed.

## REFERENCES:

- Felker G, Shaw LK, O'Connor CM. A standardized definition of ischemic cardiomyopathy for use in clinical research. *Journal of the American College of Cardiology* [Internet]. 2002Jan.1 [cited 2019Sep.12];39(2):210-8. Available from: 10.1016/s0735-1097(01)01738-7
- Schinkel AFL. Clinical assessment of myocardial hibernation. *Heart* [Internet]. 2005Jan.1 [cited 2019Sep.12];91(1):111-7. Available from: 10.1136/hrt.2004.0042085
- Mebazaa A, Yilmaz MB, Levy P, Ponikowski P, Peacock WF, Laribi S, Ristic AD, Lambrinou E, Masip J, Riley JP. Recommendations on pre-hospital & early hospital management of acute heart failure: a consensus paper from the Heart Failure Association of the European Society of Cardiology, the European Society of Emergency Medicine and the Society of Academic Emergency. *Eur J Heart Fail* [Internet]. 2015Jan.1 [cited 2019Sep.12];17(6):544-58. Available from: 10.1002/ehf.289
- Valle-Munoz A, Estornell-Erill J, Soriano-Navarro CJ, Nadal-Barange M, Martinez-Alzamora N, Pomar-Domingo F, Corbi-Pascual M, Paya-Serrano R, Ridocci-Soriano F. Late gadolinium enhancement-cardiovascular magnetic resonance identifies coronary artery disease as the aetiology of left ventricular dysfunction in acute new-onset congestive heart failure. *European Journal of Echocardiography* [Internet]. 2009Jan.1 [cited 2019Sep.12];10(8):968-74. Available from: 10.1093/ejehocard/jep115
- Lang RM, Badano LP, Mor-Avi V, Afkalo J, Armstrong A, Ernande L, Flachskampf FFA, Foster E, Goldstein SA, Kuznetsova T. Recommendations for Cardiac Chamber Quantification by Echocardiography in Adults: An Update from the American Society of Echocardiography and the European Association of Cardiovascular Imaging. *Eur Heart J Cardiovasc Imaging* [Internet]. 2015Jan.1 [cited 2019Sep.12];16(3):233-71. Available from: 10.1093/ehjci/jev014
- Dewey M, Müller M, Eddicks S, Schnapf D, Teige F, Rutsch W, Borges AC, Hamm B. Evaluation of Global and Regional Left Ventricular Function With 16-Slice Computed Tomography, Biplane Cineventriculography, and Two-Dimensional Transthoracic Echocardiography. *Journal of the American College of Cardiology* [Internet]. 2006Jan.1 [cited 2019Sep.12];48(10):2034-4. Available from: 10.1016/j.jacc.2006.04.104
- Yang PC, Kerr AB, Liu AC, Liang DH, Hardy C, Meyer CH, Macovski A, Pauly JM, Hu BS. New real-time interactive cardiac magnetic resonance imaging system complements echocardiography. *Journal of the American College of Cardiology* [Internet]. 1998Jan.1 [cited 2019Sep.12];32(7):2049-56. Available from: 10.1016/s0735-1097(98)00462-8
- Hoffmann R, von Bardeleben S, ten Cate F, Borges AC, Kasprzak J, Firsche C, Lafitte S, Al-Saadi N, Kuntz-Hehner S, Engelhardt M. Assessment of systolic left ventricular function: a multi-centre comparison of cineventriculography, cardiac magnetic resonance imaging, unenhanced and contrast-enhanced echocardiography. [Internet]. 2005Jan.1 [cited 2019Sep.12];26(6):607-16. Available from: 10.1093/eurheartj/ehi083
- Gardner BI, Bingham SE, Allen MR, Blatter DD, Anderson JL. Cardiac magnetic resonance versus transthoracic echocardiography for the assessment of cardiac volumes and regional function after myocardial infarction: an intrasubject comparison using simultaneous intrasubject recordings. *Cardiovasc Ultrasound* [Internet]. 2009Jan.1 [cited 2019Sep.12];7(1). Available from: 10.1186/1476-7120-7-38
- Grover S, Srinivasan G, Selvanayagam JB. Evaluation of Myocardial Viability With

- Cardiac Magnetic Resonance Imaging. Progress in Cardiovascular Diseases [Internet]. 2011Jan.1 [cited 2019Sep.12];54(3):204-1. Available from: 10.1016/ j.pcad.2011.06.004
11. Özben B, Çiğin AA, Mutlu B. Assessment of myocardial viability with cardiac magnetic resonance imaging. The Anatolian Journal of Cardiology (Anadolu Kardiyo Derg 2008; 8: Özel Sayı 2; 71-6). The Anatolian Journal of Cardiology [Internet]. 2019Sep.12 [cited 2019Sep.12];8(60):71-6. Available from: Makale metnine [www.anakarder.com web sayfasından](http://www.anakarder.com/web/sayfasından) ulaflılabılır.
  12. Gerber BL, Rochitte CE, Bluemke DA, Melin JA, Crosille P, Becker LC, Lima JA. Relation Between Gd-DTPA Contrast Enhancement and Regional Inotropic Response in the Periphery and Center of Myocardial Infarction. Circulation [Internet]. 2001Jan.1 [cited 2019Sep.12];104(9):998-1004. Available from: 10.1161/hc3401.095113