ORIGINAL RESEARCH PAPER

Volume - 9 | Issue - 11 | November - 2020 | PRINT ISSN No. 2277 - 8179 | DOI : 10.36106/ijsr

INTERNATIONAL JOURNAL OF SCIENTIFIC RESEARCH

PERIODONTAL CONSIDERATIONS IN DENTAL IMPLANTS – A REVIEW ARTICLE.

Periodontology

Uma Sudhakar	Professor and Head, Department of periodontology, Thai moogambigai dental college and hospital.
Lalitha T Arunachalam	Professor, Department of periodontology, Thai moogambigai dental college and hospital.
Evangeline Dorothy	Junior resident, Department of periodontology, Thai moogambigai dental college and hospital.
S. Lakshmi Priya	Junior resident, Department of periodontology, Thai moogambigai dental college and hospital.
K. Monisha Shrinidhi*	Junior resident, Department of periodontology, Thai moogambigai dental college and hospital. *Corresponding Author

ABSTRACT

The health or quality of the soft tissue surrounding an implant could even be influenced by many factors. The presence of keratinizing mucosa surrounding an implant is assumed to be a positive believe maintaining soft-tissue health. Dental implants is used to considered to be one of several treatment options which can be used to replace missing teeth. sort of implant-supported treatment is used successfully to exchange one tooth and multiple teeth, and also for a completely edentulous jaw. albeit, because the number of patients who have dental implants is increasing, dental personnel are more likely to determine patients with implant-supported restorations or prostheses. Nevertheless, dental implants may fail as a result of mechanical complications, like screw loosening or because of biological causes like peri-implant diseases. There are many Controversy in the presence or non-presence of minimal zone of keratinized tissue around the implant, likewise the exists of thick zone of keratinized tissue around the implant gives a proper prosthetic environment and help in enhancing the oral hygiene maintenance and esthetic blending. The aim of this case series was to increase the zone of keratinized soft tissue around dental implants supporting overdentures. Dental implants need various biomechanical considerations from natural teeth. Also, with one of the standards for long-term implant success being "occlusion".

KEYWORDS

osseointegration, bone density, natural tooth vs implant, keratinized gingiva, supportive periodontal therapy.

INTRODUCTION

Nowadays implant plays an essential role in aesthetic rehabilitation. Prosthodontics, oral maxillofacial surgery, restorative endodontics play a vital role in placing the implant but the success rate of implant is based on periodontal status of the patient. The various factors influencing the implant placement are patient, esthetics, surgical, mechanical, periodontal and restorative. The most important periodontal factor that must be considered before implant placement are oral hygiene, smoking, traumatized occlusion and underline systemic disease. The development of periimplantitis can occur if implant is placed in a periodontally compromised patient leading to failure of implant. Microflora also plays an important role in implant placement in patients with periodontitis. The primary factor for implant success is integration of implant surface to bone which is given by concept of osseointegration given by DR.PER INGVAR BRANEMARK IN 1969 [1]. The bone healing around the implant site gives stability and rigidity of the implant. Likewise, the soft tissue modification which is done before placement of implant helps in predictability of the treatment. The aim of this paper is to give discussion about various periodontal aspects of implant therapy.

OSSEOINTEGRATION

Osseointegration is the important factor for long time success of the implant and its function. It is combination of Greek and Latin words where osteon is a Greek word means bone and integrate a Latin word means make a whole. "It is defined as direct contact between the bone and metallic implant without interposed soft tissue" by branemark in the year 1969 [1], which later modified in the year 1977 [2], "as direct structure and functional connection between ordered living bone, and the surface the load carrying implant" [5].

THEORIES ON BONE IMPLANT INTERFACE [5]

1.**fibro osseous integration** by LINKOW (1970), JAMES (1975), WEISS (1986) says that collagen fibers play a similar role as sharpey's fibers in natural dentition. American academy of implant dentistry defines the fibro osseous integration as "tissue to implant contact with healthy dense collagenous tissue between the implant and bone" [2].

2. **Osseointegration** by BRANEMARK (1985) Branemark says that implant should be set free from functional loads for at least one year which leads to form new bone around the immobilized implant [1].

In 1987, at the microscopic level MEFFERT in 1987 subdivided osseointegration into adaptive osseointegration wherein osseous tissue approximating the surface of implant without apparent soft tissue interface and bio integration where there is a direct biochemical bone surface attachment [3].

OSSEOINTEGRATION MECHANISM [2]

The wound healing process after placement of implant into endosteal location can be divided into three phases

1. First phase – inflammatory phase. Here both vascular events and cellular events take place.
2. Proliferative phase - There new vascular ingrowth occurs around the tissue know as neovascularization. Mesenchymal cell differentiates into fibroblast, osteoblast and chondroblast. fibro cartilaginous callus develops into bone callus (woven bone)
3. Maturation phase - Woven bone is laid down in peri implant site. Complete remodeling of bone take place, which leaves the zone of lamellar bone around the basal bone.

BONE DENSITY CLASSIFICATION

Table 1:MISCH CE, KIRWS LT in 1999 classified bone based on houns field unit [6]

Bone	Houns field unit	Density	Location	Bone to implant contact	Percentage of density	Compression strength
D1	>1250 HU	Dense cortical bone	Anterior mandible	75-80%	100%	22.5mPa
D2	850-1250 HU	Thick dense to porous cortical bone	Anterior and posterior mandible	65-75%	100%	7.5mPa
D3	350-850 HU	Thin porous cortical	Anterior maxilla	40-50%	50%	3.5mPa

		bone				
D4	150-350 HU	Fine trabecular bone	Posterior maxilla		25%	
D5	<150 HU	Immature, non-mineralized bone		30%		

OSTEOGENESIS [2]

The formation of bone over the implant surface. It occurs by two ways

1. Contact osteogenesis- formation of new bone over the implant surface
2. Distance osteogenesis - formation of new bone over the old bone which already exist in the peri implant site

SUCCESSFUL IMPLANT OSSEOINTEGRATION

The successful outcome of any implant procedure is dependent on

1. Biocompatibility of the Implant material
2. Macroscopic and microscopic nature of the implant surface
3. The status of the implant bed in both healthy (non-infected) and a morphologic (bone quality) context
4. The surgical technique
5. The undisturbed healing phase
6. The subsequent prosthetic design and long-term loading phase.

ALBERKTSSON SUCCESS CRITERIA (1986) FOR SUCCESS OSTEOINTEGRATION [2]

1.The individual unattached implant should be immobile when clinically tested.

2. No radiographic evidence of radiolucency.

3. The vertical bone loss around the fixtures should be less than 0.2 mm per year after first year of implant loading.

4. The implant should not show any signs of pain, infection, neuropathies, paresthesia and sinus drainage.

NATURAL TOOTH VS IMPLANT

Implant is not the same as the natural tooth. Implant doesn't have pulp canal and periodontal ligament. Implant doesn't get decayed. Its mandatory to check whether to save the natural teeth endodontically or to extract the tooth.

Table 2: Difference Between Natural Tooth And Implant

Para meter	Natural tooth	Implant
Composition	Calcium and phosphorus(hydroxyapatite)	Primarily titanium and titanium-based alloys
Gingival sulcus depth	Shallow	Depends on abutment length and restoration margin
Crest of bone	1-2mm apical to cemento enamel junction	According to implant design
Nerve supply	Present	Absent
Connection	Cementum, bone, periodontium	Osseo integration, bone functional ankylosis ligament
Connective tissue	Thirteen groups: perpendicular to tooth surface Decreased collagen, increased fibroblast	Two groups: parallel and circular fibers Increased collagen and decreased fibroblast
Biological width	2.04-2.91 mm	3.08 mm
Probing depth	3mm in heath	2.5-5.0mm
Bleeding on probing	More reliable	Less reliable
Adaptive characteristics	Width of ligament can alter to allow mobility with increased occlusal force	No adaptive capacity to allow mobility; orthodontic movement impossible
Physical characteristics	Physiologic mobility caused by viscoelastic properties of ligament	Rigid connection to bone, as if ankylosed
Junctional epithelium connectivity issue	On enamel perpendicular to tooth surface	On titanium parallel and circular fibers; no attachment to implant or bone
Junctional epithelium	Lamina lucida and lucida, lamina dense zone.	Lamina densa and sublamina lucida zones

SOFT TISSUE AROUND IMPLANTS

The long-term success of osseointegration of dental implants depends on the peri implant soft tissues which plays an vital role in dissipation of external forces, prevention of downward growth of epithelium and also reducing the risk of infection. The peri implant mucosa derives its vasculature from supra periosteal vessels.

PERI IMPLANT MUCOSA

Peri implant mucosa is analogous to the natural gingiva and the former can be divided into epithelium and connective tissue, epithelial tissues in implant migrate more apico -coronally on an average 1mm longer than its natural counterpart. When compared to natural teeth, the connective tissue around implants have more collagen and less vascular supply hence less amount of fibroblast. The connective tissue in peri implant area is divided into outer and inner zone , the outer zone is located near the junctional epithelium , comprising type 1 and type 3 collagen. The inner supracrustal connective tissue is composed of type 1 collagen and it attributes to the mechanical resistance and stability of peri implant mucosa. Moon etal [7] analyzed under electronic microscope , the zone of the connective tissue is confined to 200ug wide zone facing the implant .It also revealed that the adhesion is bilayered, one inner layer , about 40 microgram wide, which harbors large amount of fibroblast (32%) in volume being intimate with the surface of implant , while the outer layer about 160 microgram consisting of major portion of collagen (83%).

KERATINISED GINGIVA

Gingival vasculature is derived from super periosteal blood vessels and its anastomosis with the vessels from the periodontal ligaments and alveolar vasculature. Bengazi et al reported that in the case of presence of keratinized gingiva, the long-term stability of implants over period of 6-24 months were maintained after restoration and there was also regression of the peri implant recession [8]. In animal experiments, warrer et al reported that if plaque can accumulate over the surface of the implant and in areas lacking keratinized gingiva, the recession of gingiva and loss of osseointegration predominates [9]. To assess the rationality of this assumption , clinical trial were conducted to evaluate whether a band of KG is necessary to maintain health in 1972 , Lang and Loe published the first controlled clinical trial that gives the relationship between width of KG and gingival health ,they affirmed that 80% of tooth surfaces with greater than or equal to 2mm of KG were healthy , keratinized gingiva of less than 2mm manifested signs of clinical inflammation and it was concluded that minimum of 2mm of keratinized gingiva is necessary for maintaining adequate gingival health [10]. The adhesion of the gingiva and peri implant mucosa are consistently challenged by the oral environment, including the steady exposure to microorganisms in the biofilm present on the tooth and implant surface.

BIOLOGICAL WIDTH

The distance between the margin of peri implant mucosa and underlying bone crest, the formation of biological width is a physiologic response in the oral cavity. Several studies have suggested that biological width around implant consist of sulcular and junctional epithelium with underlying connective tissue. When the implant is installed, within the first six weeks the biological width is generated and it serves as a protective barrier against bacterial invasion and food engorgement. Some animal studies revealed that migration of leukocytes through junctional epithelium towards bacterial plaque, indicating the possible defense mechanism of biological width [11]. Stability of the biological width depends on the type of the implant and crestal bone, which influence the healthy peri implant tissues and aids in long term success of the implant therapy. Some authors believed that the post restorative crestal bone remodeling is a result of the localized inflammation within the tissues located at the implant abutment interface in the process of forming the biological width [12]. A biological width dimension around two-piece implants is larger than that of the one-piece implants and natural teeth as the presence of micro gap influences marginal bone level and the biological width of the surrounding soft tissue.

HOW TO EXAMINE PERIIMPLANT TISSUE

PROBING DEPTH EVALUATION

The probing pocket depth is considered as a reliable clinical parameter in the evaluation of peri implant tissue health. Periodontal probing is

the best diagnostic tool to gather information regarding the health status and attachment level of periodontal tissues. The method includes the assessment of both probing depth and bleeding on gentle probing, and bleeding indicates the presence of inflammatory cell infiltrate. The distance between the probe tip and the bone is 1mm in both peri implant and periodontal tissues [13].

While interpreting probing measurements around implants following explanations should be considered. Desirable probing depth around dental implants are 2.5mm to 4mm but deeper assessments can be associated with healthy peri implant mucosa. Probing evaluation may be greater around implants than teeth, because there are no connective tissues fibers inserting into implants and connective tissue adhesion adjacent to implant do not impede probe penetration similar to the connective tissue attachment to teeth. A gentle periodontal probing force should be used to evaluate bleeding on probing. It is recommended that baseline probing depth should be recorded after the initial gingival healing around the perimucosal aspect of the implant, during implant maintenance. If follow up probing shows an increase from the baseline probing depth, it indicates the loss of alveolar bone support.

PERIODONTAL CONSIDERATIONS BEFORE IMPLANT PLACEMENT: -

KERATINIZED TISSUE THICKNESS: -

The inadequate zone of keratinized gingiva would facilitate plaque accumulation because of improper pocket closure resulting from the movability of the marginal tissue. In many observational studies they have suggested that the width should be at least 2mm of keratinized mucosa of which 1mm is to be attached gingiva. The traditional literature on grafting procedure has always been focused on development of alveolar hard tissue dimensions to allow implant placement in restoratively driven positions, without adequate stress on the available keratinized tissue around implants. Keratinized tissue extends from the gingival margin to the mucogingival junction. Several techniques have been advocated to increase keratinized tissue surrounding implants including, free gingival grafts, connective tissue grafts, pedicle grafts, apically positioned flaps [14].

QUALITY AND QUANTITY OF BONE: -

The term bone quality is commonly used in implant treatment and in reports on implant success and failure. Bone density and bone quality are not synonymous. Bone quality encompasses factors other than bone density such as skeletal size, and the architecture and three-dimensional orientations of the trabeculae, and matrix properties.

OCCLUSION: -

The most ideal occlusal concept advocated for implant supported restorations is that of mutually protected articulation. The posterior and anterior groups of teeth mutually protect each other. In protrusion, only the anterior teeth are controlled by the incisal properties and there is uniform disocclusion seen in the posterior region whereas in centric occlusion there is intercuspation of the posterior teeth and the anterior teeth are free of any contact. In cases where a healthy canine is present, only the canine disoccludes the rest of the posterior teeth in lateral excursions. The concepts and ideas designed for natural teeth are applied to implants also and as Osseo integrated implants lack specific defense mechanisms, poorly restored occlusion on Osseo integrated implants can result in deleterious effects to the prosthesis and supporting alveolar bone. In case of a full-arch fixed prosthesis, if the opposing arch is a complete denture, balanced occlusion is recommended. Group function or mutually protected occlusion with shallow anterior guidance is recommended in case of opposing natural dentition or a full arch fixed prosthesis [15].

ORAL HYGIENE: -

Basically, maintenance of dental implants includes the professional cleaning by the dentist and oral home care by the patient itself. Good oral hygiene on the patient's part is mandatory. Twice daily cleaning of implants to remove plaque accumulation should be accomplished using soft toothbrush. There are many flosses, interproximal cleaners, and water irrigation systems which are commercially available and safe for use around implants. Floss choice should be based on the clinical indication. Dental Tapes are available in different "widths" and are used to clean the exposed abutment. When recommending interdental brushes, it should be wide enough to fill the space, flexible, and passes through to the other side. In the case of the implant supported bridge, a 360- flossing motion may not be possible due to prosthesis design and/or the patient's ability. A simple side to side sweeping motion may be demonstrated in its place. When threads or roughened areas of the implant are exposed, floss that can shred and remain in the peri- mucosal tissue is discouraged.

PROFESSIONAL CLEANING INSTRUMENTATION: -

Instruments made of metal, such as stainless steel, should be limited to natural teeth and not to be used to probe or scale implants as the hard metal can scratch, contaminate, or cause a galvanic reaction at the implant. Recently, automated or electric toothbrushes have been advocated for daily home care. These devices may be rotary, circular, or sonic in design. The key to their effectiveness is proper diligent daily use by the patient.

SPT (SUPPORTIVE PERIODONTAL THERAPY)

SPT (also known as maintenance therapy, supportive periodontal care or supportive periodontal treatment) follows the same principles employed in the treatment of active disease. It begins once patients are deemed periodontally stable, which is determined six to eight weeks after completion of active treatment.[16]

The aims of SPT are well established: minimize the recurrence of disease through periodic preventive interventions, and maintain the attachment apparatus in the most stable condition possible. The aims of SPT are achieved through:

1. Maintenance using conventional or plastic instrumentation.
2. Polishing using rubber cups or air.
3. Instrumentation with fine abrasives

Supportive periodontal therapy is to be an effective method of periodontal maintenance when placing implants in patients.

There is a reliable evidence that a regular follow up system rendering appropriate supportive care is of utmost importance for peri-implant health and stability.

Undeniably, when there is no supportive care which represents a higher risk for peri-implant disease development while the compliance with a recommended and calculated maintenance care interval results in decreased risk for disease development.

A lack of compliance of SPT was correlated with a higher incidence of marginal peri-implant bone loss at follow-up as well as an increase incidence of implant failure.[17]

PERI IMPLANT DISEASE AND MANAGEMENT

Peri implant disease can be either peri implant mucositis which is defined as reversible inflammation of the soft tissues surrounding an implant in function with no loss of supporting bone. The clinical signs are bleeding and or suppuration on probing and increased probing depths (4-5mm) (fig1) or peri implantitis: defined as inflammatory process affecting the tissues around an Osseo integrated implant in function leads to supportive bone loss (fig2). The clinical signs are deep probing depth greater than 5mm, bleeding and or suppuration on probing. loss of supporting bone resulting from periimplantitis usually forms a circumferential crater like defect [18].

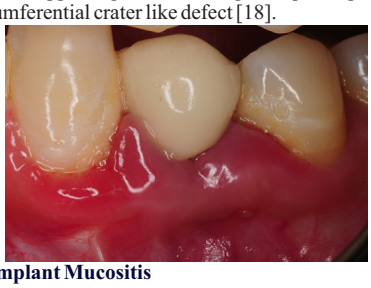

Fig 1: Peri implant Mucositis

Fig 2:PERIIMPLANTITIS

High levels and proportions of periodontal pathogens, mainly gram-negative anaerobic bacteria including Porphyromonas gingivalis, Tanerella forsythia and Treponema denticola, have been identified [19]. Deep pockets harboring high number and large proportions of periodontal pathogens act a reservoir for recolonization and establishment of a microflora which is not conductive to health. The management of peri implant disease is undoubtedly a challenge. In case of mucositis therapy, there are many studied methods of implant decontamination including traditional subgingival instrumentation alone or synergistically with laser therapy, photo dynamic therapy, air - abrasive technique and chemotherapy using tetracycline, citric acid, chlorhexidine or saline irrigation [20]. In case of peri implantitis, the goal of surgical therapy is to achieve access given the limitation of a closed non-surgical approach. Surgical options [21] include open flap debridement with or without reconstructive therapy (bone graft and membrane), ressective surgery (osseous defect removal), implantoplasty (removal of implant threads) or explantation (implant removal).

CONCLUSION

Dental implants play a successful role in treatment. of complete or partial edentulous patients. osseointegration plays a vital role in longevity of implants. keratinized gingiva is an essential factor in preventing gingival recession and loss of osseointegration. Biological width should be considered to prevent bacterial invasion and food engorgement. periodontal probing is the best diagnostic tool in assessing healthy state of peri implant tissues. In case of peri implant disease, we have various treatment modalities that includes laser therapy, photo dynamic therapy, air abrasive technique and chemotherapy surgically we can do open flap debridement with or without regenerative therapy (bone graft and membrane), ressective surgery (osseous defect removal), implantoplasty (removal of implant threads). In terminal stage of failure of implants, we can do explantation (implant removal). To maintain long term success, we have to consider both soft and hard tissues interface, implant maintenance is very essential. long term follows up of patients along with supportive periodontal therapy will ensure the success of therapy.

REFERENCES:

1. Implant dentistry: Periodontal and restorative factors in a multidisciplinary approach Year: 2014 |Volume: 4|Issue: 1/Page: 3-7.
2. IOSR Journal of Dental and Medical Sciences (IOSR-JDMS) e-ISSN: 2279-0853, p-ISSN: 2279-0861.Volume 16, Issue 1 Ver. I (January. 2017), PP 45-48
3. Pocketdentistry/introduction-to-understanding-the-basics-of-teeth-vs-dental-implants-similarities-and-differences
4. tsao and wang periodontal consideration in implant therapy int chin j dent 2003 3:13-30
5. Osseointegration in Dental Implants: A Literature Review Volume: 4 | Issue: 7 | July 2014 | ISSN - 2249-555X
6. Arriving at a definitive bone quality Received on: 26-02-2018; Revised on: 27-04-2018; Accepted on: 25-05-2018
7. Moon IS, Berglundh T, Abrahamsson I, Linder E, Lindhe J. The barrier between the keratinized mucosa and the dental implant. An experimental study in the dog. *J Clin Periodontol*. 1999;26: 658–663.
8. Bengazi F, Wennstrom JL, Lekholm U. Recession of the soft tissue margin at oral implants, a 2-year longitudinal prospective study. Clin Oral Implants Res 1996;7:303-10.
9. Warrer K, Buser D, Lang NP, Karring T. Plaque-induced peri- implantitis in the presence or absence of keratinized mucosa. An experimental study in monkeys. Clin Oral Implants Res 1995;6:131-8.
10. Lang NP, Löe H. The relationship between the width of keratinized gingiva and gingival health. *J Periodontol*. 1972;43(10):623-627.
11. Kawahara H, Hashimoto K. Morpholologic studies on the biologic seal of titanium dental implants Int J Oral Maxillofac Implants 1998;13:465-73.
12. EricssonJ,PerssonLG.Differenttypesofimplantassociatedreactions in periodontal soft tissues J Clin Periodontol 1995;22:255-61.
13. Greenstein, G. (1984) The role of bleeding upon probing in the diagnosis of periodontal disease. A literature review. Journal of Periodontology 55: 684–688.
14. Enhancing the zone of keratinized tissue around implants./ Sarita Joshi Narayan, Pranav Kumar Singh, Shammas Mohammed, R. K. V. Patel.The Journal of Indian Prosthodontic Society | Apr-Jun 2015 | Vol 15 | Issue 2.
15. Implant Maintenance: A Clinical Update./ Minkle Gulati, Vivek Govila, Vishal Anand, and Bhargavi Anand. International Scholarly Research Notices.
16. Supportive periodontal therapy (SPT) for maintaining the dentition in adults treated for periodontitis Carolina Manresa, Elena C Sanz-Miralles, Joshua Twigg, Manuel Bravo.
17. Dental Implant Therapy in Patients with a History of Periodontitis: A Literature Review and Clinical Considerations./ Michael Courtney, DMD, MA; David Cottrell, DMD; and Srinivas Ayilavarapu, BDS, CAGS, DSc.Compendium Jul/Aug 2012 Volume 33, Issue 7.
18. Albrektsson T, Isidor F. Consensus report of session IV. In: Lang N, Karring T, eds. Proceedings of the 1st European Workshop on Periodontology. Switzerland: Quintessence, 1994:365.
19. Mombelli A, Marxer M, Gaberthuel T, Grunder U, Lang NP. The microbiota of osseointegrated implants in patients with a history of periodontal disease. J Clin Periodontol 1995;22:124–130.
20. Renvert S, Roos-Jansaker A, et al. Non-surgical treatment of peri-implant mucositis and peri-implantitis: a literature review. J Clin Periodontol. 2008;35(8 Suppl):305-315.
21. Lauren E. Anderson; Peri-Implant Disease: Diagnosis, Treatment, and Prevention Protocol;volume 10,issue 9;September 2014