



## COMPARISON OF FINAL OUTCOME OF DISTAL RADIUS FRACTURE TREATED WITH PLASTER CAST APPLICATION VERSES K WIRE AND EXTERNAL FIXATOR.

### Orthopaedics

**Ejajahmed R. Ansari**

Assistant Professor, Department of Orthopaedics, L.G. Hospital, Ahmedabad

**Hitesh L Panchal \***

Assistant Professor, Department of Orthopaedics, L.G. Hospital, Ahmedabad  
\*Corresponding Author

**Vipul S. Leuva**

Assistant Professor, Department of Orthopaedics, L.G. Hospital, Ahmedabad

### KEYWORDS

#### INTRODUCTION:

The fracture of distal radius was common in elderly with low function demand who sustained a low energy trauma. But the incidence of this fracture is increased in all age groups due to increasing number of elderly population along with increasing number of road traffic accidents and other high energy trauma.

There are numerous treatment modalities available for the treatment of this fracture i. e. closed reduction and plaster cast, k wire fixation and external fixator, open reduction and internal fixation with volar or dorsal plating.

One must consider the following factors before finalizing the treatment modality for each patient, these include the patient's age, lifestyle, associated injuries, co-morbidities, functional demands, dominance of hand, type of fracture, alignment of fracture, condition of soft tissues, weather the fracture is open or closed and economic constraints of the patient.

Here in this study we try to compare the final outcome of non operative (plaster cast fixation after closed reduction) and k wire plus external fixation modality of treatment for distal end of radius fracture.

#### MATERIAL AND METHODS:

We included 30 patients in this study for the period of 2015 to 2018 at our institute. 15 patients were treated with plaster cast and 15 were treated with percutaneous k wire and external fixator.

close fracture of distal radius with normal distal neuro vascular status, medically fit, above 18 years of age and fracture not more than one week old was the inclusion criteria.

#### Treatment modalities:

Following admission, all the patients were evaluated for having any other injury as well as injured limb neurovascular status. Primary emergency medical treatment was given to all the patients. Radiographs of injured wrist with forearm in neutral position were taken both in Posteroanterior view and Lateral view.

#### Closed reduction and plaster cast application:

Closed reduction done with traction by surgeon and counter traction by assistant. Plaster was applied in wrist palmer flexion and slight ulnar deviation. Reduction was checked under image intensifier.

Criteria for Inadequate Reduction after closed Reduction; Articular step off > 2 mm, Dorsal tilt >10°, Radial shortening > 5 mm, Ulnar inclination <15°.

Follow up was done every weekly for 3 weeks. Plaster cast was removed after 4 to 5 weeks and physiotherapy was started. Radiograph were taken for final followup and final functional outcome was measured at 6 month using Gartland and Werley scoring system.

#### Percutaneous k wire fixation and external fixator:

Patient was given regional or general anaesthesia and after proper aseptic precaution reduction done with traction and counter traction by assistant and after confirming reduction under image intensifier fracture was fixed with percutaneous k wires in cross configuration,

one or two from radial styloid and one from lunate fossa fragment of radius. Satisfactory reduction was augmented by external fixator with two shanz pins in radius shaft and two in second meta carpal bone.

Finger mobilization was promoted from next day of surgery. Regular follow up was done every weekly for 3 weeks. External fixator and wires was removed after 4-5 weeks after confirming union radiologically.

Functional outcome was measured using gartland and Werley scoring system at 6 month follow up.

#### Assessment of outcome:

Functional and radiological outcome was measured at 6 months follow up.

#### Radiological outcome:

The mean radial height in the casting group was 8mm while the mean in the k-wiring group was 10mm.

The mean radial inclination in the Cast application group was 14 degrees and that in the k-wiring group was 18 degrees.

The mean volar tilt in Cast application group was 4 degrees and that in the k-wiring group was 6.5 degrees.

#### Functional outcome:

Mean range of movements in degrees of both groups are listed below.

	Palmer flexion	Dorsi flexion	supination	pronation	Ulnar deviation	Radial deviation
Cast group	60	56	62	60	20	15
K wire plus external fixator group	63	60	68	63	21	16

As per our observation, both the group have almost equal range of motion. Although k wire and external fixator group have slight better movement but it is statistically not significant.

Functional scoring done using gartland and Werley scoring system. Cast application group had 8 excellent, 3 good, 3 fair and 1 poor outcome. The fixator group had 9 excellent, 4 good, 3 fair, 1 poor result.

Complications include two patients having CRPS in external fixator group. Three had pin track infections treated with wound care and antibiotics. Three patients in cast group develop CRPS and two patients lost reduction on follow up.

#### DISCUSSION:

Distal radius fractures are common in all age groups. The choice of the appropriate treatment for distal radius fractures depends on the type of the fracture and the patients and also the experience of the surgeon. Many fractures can be treated nonoperatively with alignment that is not ideal, but that may provide function that is adequate for a less-demand elderly patient.

Howard et al. compared the results of patients younger than 75 years

old. They found better functional and anatomical results with the EF group. Similar results were found by Kongsholm et al<sup>3</sup>. Christensen et al<sup>4</sup> found better results in the EF group.

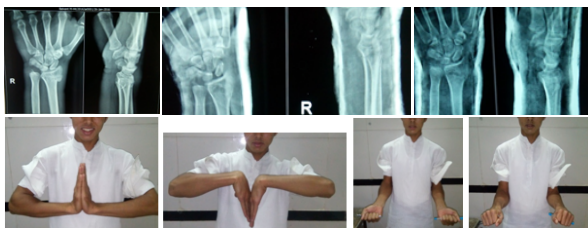
Several studies have suggested that there is a direct relationship between the anatomical result and the functional outcome, but most older patients with lower functional demands do relatively well in spite of obvious deformity<sup>6,7</sup>.

In our study, radiological parameters are superior in external fixator group. Using Gartland and Werley scoring system 86 percent of patients having excellent to good outcome in external fixator group and on the other hand 76 percent having excellent to good functional outcome.

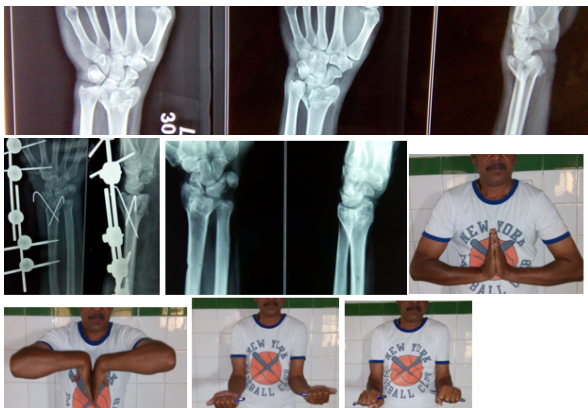Fractures of the distal radius are well treated with either cast immobilization or external fixator and k wires. Both methods have advantages and disadvantages. The current study shows that EF has better radiological outcome as compared to cast group. Over all functional outcome is slightly better in external fixator group.

Limitation of study is small sample size and long term follow up.

### 1. Plaster cast after closed reduction.



### 2. Percutaneous k wire and external fixator .



### REFERENCES

1. Azzopardi T, Coulton T. A prospective randomized study of immobilization in cast versus supplementary percutaneous pinning. *J Bone Joint Surg.* 2005;87:837.
2. Howard PW, Stewart HD, Hind RE, Burke FD. External fixation or plaster for severely displaced comminuted Colles' fractures? A prospective study of anatomical and functional results. *J Bone Joint Surg* 1989;71B:68-73.
3. Kongsholm J, Olerud C. Plaster cast versus external fixation for unstable intraarticular Colles' fractures. *Clin Orthop Relat Res* 1989; 241:57-65.
4. Christensen OM, Christiansen TC, Krashennikoff M, Lind B, Holmich LR, Hansen FF, et al. Plaster cast compared with bridging external fixation for distal radius fractures of the Colles' type. *Int Orthop* 2001;24:358-360.
5. John J, Gartland JR, Charles W. Werley. Evaluation of Headed Colles Fractures. *J Bone Joint Surg Am.* 1951;33(4):895-907.
6. Young BT, Rayan GM. Outcome following nonoperative treatment of displaced distal radius fractures in low-demand patients older than 60 years. *J Hand Surg [Am]* 2000;25:19-28.
7. Cooney WP 3rd, Lindscheid R, Dobyns J. External pin fixation for unstable Colles' fracture. *J Bone Joint Surg [Br]* 1979;61-B:840-5.
8. Young CF, Nanu AM, Checketts RG. Seven-year outcome following Colles' type distal radial fracture. A comparison of two treatment methods. *J Hand Surg Br.* 2003;28:422-6.
9. McQueen M, Caspers J. Colles fracture: does the anatomical result affect the final function? *J Bone Joint Surg [Br]* 1988;70-B:649-51.