



## ISLANDED PEDICLED PERFORATOR FLAPS FOR VARIOUS SOFT TISSUE DEFECTS: OUR EXPERIENCE IN A GOVERNMENT MEDICAL COLLEGE

### Plastic Surgery

**Dr. Subhashis Karmakar\*** Associate Professor, Department of General Surgery, R.G.Kar Medical College and hospital Kolkata. \*Corresponding Author

**Dr. Deepanjan Dey** Plastic Surgeon

**Dr. Prabir Kumar Jash** Professor, Department of Plastic Surgery, Medical College, Kolkata

**Dr. Santanu Suba** Associate Professor, Department of Plastic Surgery, AIIMS, Bhubaneswar

### ABSTRACT

Soft tissue defects requiring flap coverage are resurfaced by peninsular flaps, musculocutaneous flaps or distant free flaps. In a Government Hospital; Medical College, Kolkata; we face a huge patient load and hence we planned to do pedicled perforator based flaps to reduce operative time over free flaps. Additionally, islanding in a single stage will avoid unaesthetic dog ears and bulges of local peninsular flaps and reduce the prolonged duration of hospital stay. We aimed to do islanded, pedicled perforator flaps and assess the operative time for reconstruction, the complications and the post-operative hospital stay. We conducted this prospective interventional study over one year. Out of 35 patients, in 15 patients, we rotated the flaps on perforators as propeller flaps. In 20 patients we dissected up to and included the source vessel of the perforators to gain additional length. The mean operative time for reconstruction was 1 hour 45 minutes. There was wound dehiscence and broad donor site scar in one patient each (3%). Overall complication rate was 14%. The post-operative hospital stay ranged from 3-14 days with a mean of 4.75 days. We concluded that islanded perforator flaps can be done fast-- increasing the number of patients operated daily. The overall hospital stay in the post-operative period is reduced. Dog-ears and bulges near pedicle are avoided giving a better aesthetic outcome.

### KEYWORDS

Propeller flaps, Perforator flaps, Peninsular flaps

#### INTRODUCTION:

Resurfacing of soft tissue defects comprises a major portion of the reconstructive work we do in our Department. We have utilized various non-microsurgical procedures like loco-regional random pattern skin flaps, peninsular fasciocutaneous flaps and musculocutaneous flaps. These flaps though are easier to execute, provide poor aesthetic results with dog-ears and unsightly bulges near the pedicle. Staged procedures like cross-leg flaps have further issues of increased patient morbidity and prolonged hospital stay. At the other end of the spectrum, the free flaps have their own disadvantages requiring additional operative time in microvascular anastomosis thereby reducing the number of patients that are operated on a given day. Prolonged duration of anesthesia in these cases also adds to the morbidity in certain patient groups.

With evolving knowledge of anatomy and physiology, we have refined random pattern flaps with obscure vascularity to present day flaps tailored over precise perforators to reduce donor site morbidity with improved aesthetics.

It was Koshima et al.<sup>1</sup> who first described a thin skin flap based on a single paraumbilical perforator from the deep inferior epigastric artery keeping the rectus abdominis muscle intact.

Hyakusoku et al.<sup>2</sup> in 1991 described an adipocutaneous flap designed as a propeller, blood supplied through a random subcutaneous pedicle and rotated 90 degrees.

The term 'propeller flap' was first time used by Hallock<sup>3</sup> and the definition was provided by an Advisory Panel of the First Tokyo Meeting on Perforator and Propeller Flaps in 2009<sup>4</sup>.

Modification of the perforator flap to include a segment of the source vessel to increase the reach has been described by Phillip N. Blondeel et al.<sup>5</sup> The present general consensus<sup>6</sup> is the existence of three different types of perforators: the direct cutaneous, septocutaneous and the musculocutaneous.

Hence, to overcome the limitations of the loco-regional flaps and the free flaps, we adopted a middle path utilizing islanded pedicled perforator flaps. These flaps would be superior both to the loco-regional flaps in terms of aesthetics and hospital stay and to the free flaps in terms of operative time.

#### AIMS AND OBJECTIVES:

We aimed to cover various soft tissue defects with islanded pedicled perforator flaps and assess the outcomes in terms of:

1. Operative time for reconstruction
2. Complications and donor site morbidity
3. Post-operative hospital stay

#### MATERIALS AND METHODS :

We conducted this prospective interventional study in The Department of Plastic and Reconstructive Surgery, Medical College, Kolkata. The duration was one year from May, 2018 to May, 2019. The study population comprised of the patients admitted in Plastic Surgery department or referred from other departments in our hospital. We included all consecutive patients with soft tissue defects indicated for flap coverage who consented for the surgery (convenience sampling method).

We excluded patients less than 5 years and more than 80 years and those with comorbidities like uncontrolled Diabetes Mellitus and diagnosed vascular disease to minimize confounding by other variables. Patients unfit for surgery and anaesthesia and those who did not give consent were also excluded.

For simplification, we defined the perforator flaps as fasciocutaneous flaps, islanded on a perforator vessel. It could be a septocutaneous, a musculocutaneous or a direct cutaneous perforator. We named the flap on the closest axial source vessel that the perforator arose from.

A total of 35 patients were studied. In 15 patients, we covered the soft tissue defects with islanded, pedicled perforator flaps from the immediate vicinity of the defects as propeller flaps rotated by up to 180°. In the other 20 patients, we dissected out a length of the source vessel along with the perforator to gain length to reach regional defects. We reduced the size of the defects by approximating the surrounding skin to the wound bed whenever possible. To the final defect size, we added 1 cm to the length and 0.5 cm to the breadth to get the flap size<sup>7</sup>.

In each case, we used a hand held Doppler device to mark out perforators closest to the defects. We made a template of the defect and designed a flap by planning in reverse over the marked perforator as the pivot point for rotation (Fig. 4 A). Under tourniquet, we placed the exploring incision in such a manner that an alternative flap could also be designed if needed<sup>8, 9</sup> (Fig. 4 B). With loupe magnification, we

dissected subfascial for identification of the marked perforator and ensured the reliability by the caliber of the perforator being at least 1 mm<sup>10</sup> and observing pulsations on release of tourniquet later on. We dissected out the perforator for at least 3 cm<sup>10</sup> (Fig. 4 C).

In case of a regional defect, we traced the perforator to its source vessel through the septum or by splitting muscles when required (Fig. 7 C,D). We sutured the split muscles with absorbable sutures to restore anatomy as much as possible. We ligated the source vessel beyond the origin of the perforator and included the vessel along with the perforator shifting the pivot closer to the defect. We preserved a cuff of muscle or subcutaneous fat around the pedicle whenever possible to prevent adverse effects like vasospasm or shearing that could happen

in a long segment of a skeletonised vessel<sup>11</sup>.

We committed the flap in an islanded fashion and elevated from distal towards proximal. We released the tourniquet and let the flap perfuse for 10 mins<sup>12</sup>. The propeller flaps were rotated into the defect in a clockwise or anticlockwise manner whichever arc was shorter (Fig. 4D). The source vessel flaps were either tunneled into the defects through the subcutaneous tissue or taken through an open route with the pedicle subsequently buried beneath primary skin closure (Fig. 7 D, E). We inset the flaps with a corrugated drain underneath. We closed the donor sites either primarily or by skin grafting. We monitored the flap in the post-operative period to look for ischemia or venous congestion. We followed up the patients after discharge in the Out Patients Department at least for 3 months.

**Table 1: Propeller flaps**

Sl no	Region	Lesion (size in cm)	Defect (size in cm)	Flap (size in cm)	Donor site closure	Operative time for reconstruction	Complications	Hospital stay post-op (days)
1	Back	DFSP, 7*11	10*14	Lumbar APF, 7*12	Primary	1 hr 10 mins	Broad donor site scar	3
2	Back	Decubitus ulcer sacrum, 4*9	5*10	Superior Gluteal APF, 5*10	Primary	1 hr 40 mins	None	3
3	Shoulder	SCC Rt shoulder, 6*8	8*10	Circumflex scapular APF, 9*11	Primary	55 mins	Hematoma under flap, 2 <sup>o</sup> suture	6
4	Shoulder	DFSP Lt shoulder, 5*7	9*13	Circumflex scapular APF, 10*14	Primary	1 hr	None	3
5	Upper limb	PBC Lt axilla	15*20	Thoracodorsal APF, 15*20	Primary	2 hrs 15 mins	None	4
6	Upper limb	PBC Lt elbow	10*14	Proximal Radial APF, 8*6 with STSG	STSG	1 hr 55 mins	None	5
7	Lower limb	Soft tissue sarcoma Lt upper thigh, 15*8	17*10	Lateral circumflex femoral APF, 15*8	Primary	2 hrs 10 mins	None	4
8	Lower limb	PBC Lt popliteal fossa with non-healing ulcer	16*10	Medial Sural APF, 11*7 with STSG	Primary	1 hr 40 mins	None	5
9	Lower limb	Post-traumatic mid third leg defect with exposed tibia	4*8	Posterior Tibial APF, 4*10	Primary	1 hr 10 mins	None	3
10	Lower limb	SCC Rt leg, 7*10	9*12	Peroneal APF, 9*12	STSG	1 hr 55mins	None	5
11	Lower limb	PBC Lt lower leg, anterior ankle, dorsum of foot	4*25	Peroneal APF, 4*11 with STSG	STSG	2 hrs	None	5
12	Lower limb	Post-traumatic wound Lt anterior ankle	6*12	Peroneal APF, 6*12	STSG	2 hrs	None	5
13	Lower limb	Post-traumatic wound Lt posterior heel	3*10	Peroneal APF, 3*12	STSG	1 hr 50 mins	None	5
14	Lower limb	Benign skin lesion Lt anterior ankle	5*8	Peroneal APF, 5*10	STSG	1 hr 20 mins	None	5
15	Lower limb	PBC Lt dorsum of foot	2*6	First Dorsal Metatarsal APF, 2*6	STSG	1 hr	None	5

(contd.)

**Table 2: Source vessel perforator flaps**

Sl no	Region	Lesion (size in cm)	Defect (size in cm)	Flap (size in cm)	Donor site closure	Operative time for reconstruction	Complications	Hospital stay post-op (days)
1	Head and neck	Post electric burn scalp wound, 5*9	13*10	Dorsal Scapular APF, 8*12	Primary	2 hrs 10 mins	None	3
2	Head and neck	Verrucous carcinoma buccal mucosa, 4*6	6*8	Submental APF, 6*8	Primary	2 hrs	None	5
3	Upper limb	Hidradenitis Suppurativa Lt axilla, 4*6	9*12	Thoracodorsal APF, 9*12	Primary	2 hrs 5 mins	None	4
4	Upper limb	Lt arm non healing ulcer, 8*14	8*14	Thoracodorsal APF, 7*15	Primary	1 hr 55 mins	None	3
5	Upper limb	PBC Rt elbow, 4*6	10*13	Ulnar collateral APF, 6*12 with STSG	STSG	2 hrs	None	5
6	Upper limb	PBC Lt elbow, 4*5	5*10	Radial collateral APF, 5*10	Primary	2 hrs 5 mins	None	3
7	Upper limb	Post-traumatic wound over Rt elbow, 8*10	8*10	Posterior Interosseous APF, 6*10	STSG	2 hrs	None	5
8	Upper limb	Benign soft tissue tumor, Rt dorsum of hand, 4*9	5*10	Posterior Interosseous APF, 5*10	STSG	2 hrs 10 mins	Marginal necrosis	8
9	Upper limb	Post-traumatic wound, dorsum of Rt hand, 10* 15	10*16	Radial APF, 10*16	STSG	1 hr 40 mins	None	6

10	Shoulder	DFSP Lt shoulder, 6*10	10*14	Circumflex scapular APF, 10*15	Primary	1 hr 30 mins	None	3
11	Shoulder	SCC Rt shoulder, 12*16	14*20	Circumflex scapular APF, 13*20	Primary	1 hr 15 mins	None	3
12	Abdomen	Desmoid tumor Right iliac fossa, 6*18	8*20	Lateral circumflex femoral APF, 6*15	Primary	2 hrs 30 mins	None	4
13	Abdomen	Ectopiavesicae, 5*6	6*12	Lateral circumflex femoral APF, 6*10	Primary	2 hrs 10 mins	None	5
14	Groin	Post traumatic wound Lt groin, 9*15	9*15	Lateral circumflex femoral APF, 9*15	Primary	2 hrs 15 mins	None	4
15	Groin	Lt groin malignant ulcer, 5*12	8*16	Lateral circumflex femoral APF, 6*14	Primary	2 hrs 20 mins	Flap loss	14
16	Lower limb	Squamous cell carcinoma Lt knee, 5*9	7*11	Lateral Genicular APF, 7*11	Primary	1 hr 20 mins	None	3
17	Lower limb	Post- traumatic wound Rt knee, 5*10	5*10	Lateral Genicular APF, 5*10	Primary	1 hr 10 mins	Partial flap loss	10
18	Lower limb	Post- traumatic wound Lt knee, 2*3	4*6	Medial Sural APF, 4*6	Primary	1 hr 40 mins	None	3
19	Lower limb	Post –traumatic wound Lt medial malleolus, 4*6	4*8	Anterior Tibial APF, 4*8	STSG	2 hrs	None	6
20	Lower limb	Post –traumatic Rt medial malleolar wound, 3*4	3*4	MedialisPedis APF, 3*3	STSG	1 hr 15 mins	None	5

(Contd.)

**Abbreviations :** 2<sup>o</sup>-Secondary, APF-Artery perforator flap, cm-Centimeter, DFSP-Dermatofibrosarcoma protuberance, Lt- Left, PBC- Post burn contracture, Post-op-Post-operative, Rt-Right, SCC-Squamous cell carcinoma, Sl.no- Serial number, STSG-Split thickness skin graft

**RESULTS:**

With the propeller flaps, we covered defects over the back, shoulder, the upper and the lower limbs. With source vessel-perforator flaps, we covered defects in the head and neck region, the shoulder, the abdomen, the groin, the upper and the lower limbs.

Overall, the etiology of the defects were post-traumatic, malignancy, post burn contracture release, post-infective non healing wounds and one case of a congenital defect (ectopiavesicae).

The ages of the patients ranged from 16 to 71 years.

The overall mean defect size was 101.15 sq cm and the mean flap size was 85.67 sq cm. In 4 patients (11.43%) with large defects spanning joints, the perforator flaps were used to cover only over the joints and remaining part of the defects were skin grafted. None of the flaps in the limbs exceeded one third the limb length.

In all the flaps, we found the perforators at the site of the Doppler markings. In one patient where a lateral circumflex femoral artery based perforator flap was designed, we found the perforator to arise about 5 cm proximally from the source vessel i.e. the descending branch of the lateral circumflex femoral artery, perforate the fascia and travel for 5 cm suprafascially to terminate at the site of the audible Doppler marking. In one patient with a mid-third leg defect where a peroneal artery perforator flap was planned, exploring incision revealed multiple closely spaced small caliber perforators. None of these perforators seemed adequate to support the required flap independently and so the procedure was converted to a lateral hemisoleus flap.

In 13 patients (37.14%) we covered the donor site with a split thickness skin graft. Rest of the 22 patients (62.86%) had primary closure of the donor site.

The operative time for reconstruction in our study ranged from 55 mins to 2hrs and 30 mins. The operative time was more in cases where a part of the defect or the donor site needed a skin graft coverage. The mean operative time in case of the source vessel perforator flaps was more than that of the propeller flaps. The need for vessels dissection which in most cases was intramuscular added to the duration of the surgeries in those cases.

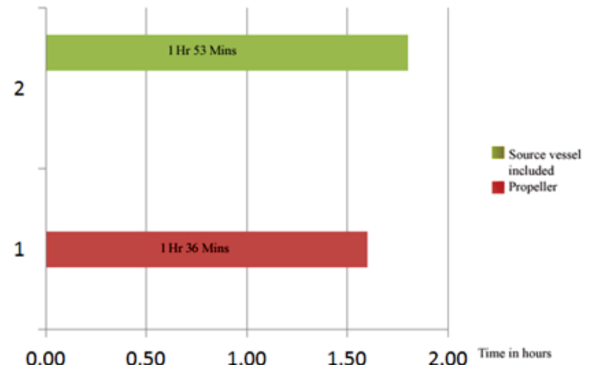


Fig 1: Mean operative time in both the groups

One patient in whom a lumbar artery perforator based propeller flap was done had donor site morbidity in the form of a widened scar due to secondary healing of a small segment of donor site closure (3%). We lost one flap pedicled on the lateral circumflex femoral vessel due to pedicle compression causing irreversible venous congestion (3%). A skin graft was done after application of negative pressure wound therapy. Two flaps had a partial and a marginal necrosis requiring additional skin graft and secondary suturing respectively (6%). We had to do a secondary suturing of the flap inset in one patient who had a dehiscence due to hematoma under the flap (3%). The overall complication rate was 14%.

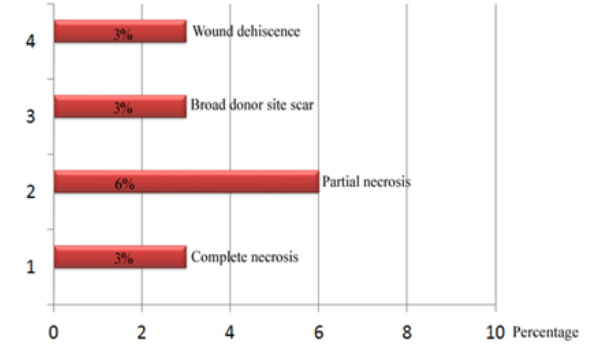
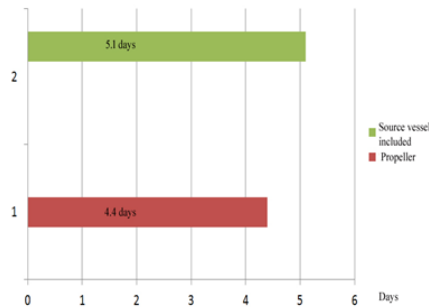


Fig 2: Overall complications

The post-operative hospital stay ranged from 3 to 14 days. The patients who needed a skin graft along with the flap or in the donor sites generally took more time to be discharged. One patient where the entire flap was lost stayed the longest time (14 days) as a skin graft was done after the flap completely necrosed. The overall mean hospital stay in the post-operative period was 4.75 days.



**Fig 3: Mean post-operative hospital stay**

**DISCUSSION :**

With a success rate of 97%, we found the islanded, pedicled perforator flaps to be very reliable for a wide range of soft tissue defects. Recognized complications like venous congestion<sup>11</sup> can be avoided by adhering to the already established perforator dissection techniques described in literature<sup>8,9</sup>. Reducing the size of the defect whenever possible helps to keep the flap size within safe limits<sup>13</sup> and minimizes donor site morbidity.

Tissue of similar characteristics in the loco-regional area of a defect is used while avoiding dog-ears associated with peninsular flaps and bulges of musculocutaneous flaps. Hence the aesthetic outcome is also superior. Having said that, being a local flap, it requires a healthy, usable skin territory with good perforators in the vicinity of the defect unlike a free flap. This is a limitation of these flaps.

Replacing cross-leg flaps and abdominal flaps with perforator flaps, we have alleviated patient discomfort associated with those morbid procedures and reduced the hospital stay at the same time.

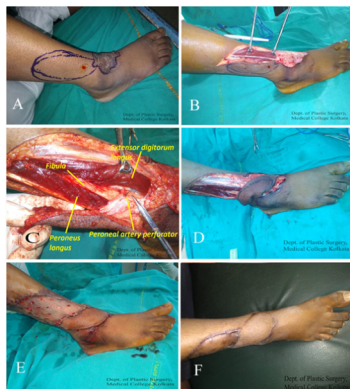Though these flaps require microvascular dissection techniques, unlike free flaps they do not require vessel anastomosis and so are less time consuming. This advantage provides better reconstructive opportunities in certain group of patients like the elderly or those with multiple injuries where their compromised general condition contraindicates a time consuming free flap procedure. A reduced operative time also allows us to operate upon more patients on a given day. This along with a short post-operative hospital stay can help increase the patient turn-over rate without compromising on the standard of care.

**CONCLUSION:**

Islanded, pedicled perforator flaps are a reliable option for covering a wide range of soft tissue defects. They are simpler and quicker than free flaps. They are aesthetically better than other loco-regional flaps and have a shorter post-operative hospital stay.

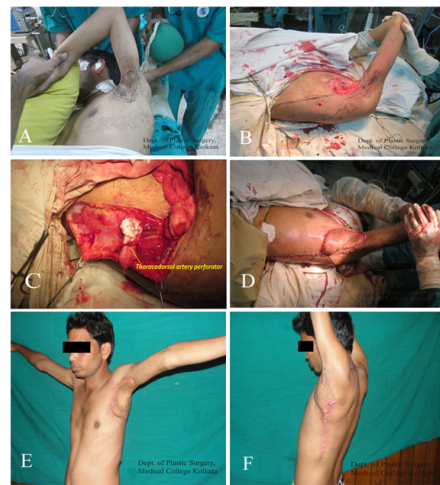**Photographs:**

**Patient 1:**



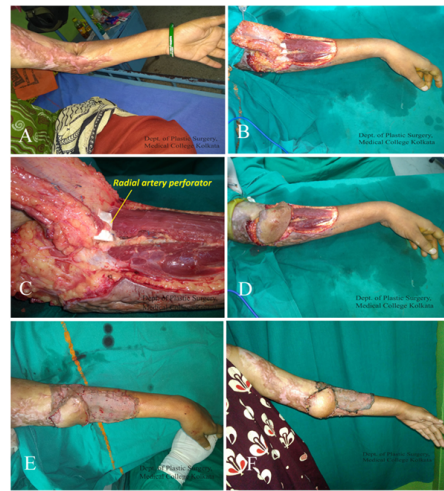**Fig 4: A.** The flap planned over a perforator marked with a hand-held Doppler device. **B.** Anterior exploring incision placed and subfacial dissection done to trace the perforator. **C.** At least 3 cm length of perforator dissected out and flap islanded. **D.** Flap rotated into the defect. **E.** Donor site skin grafted. **F.** Follow-up in the out patients department after 3 months.

**Patient 2:**



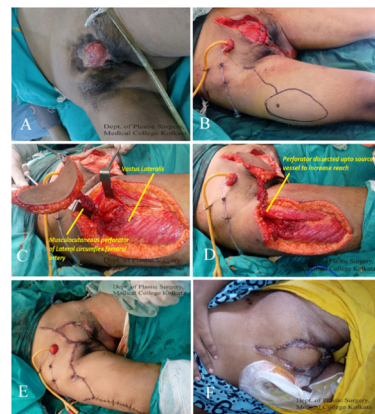**Fig 5: A.** Axillary hidradenitis. **B.** Thoracodorsal artery perforator marked. **C.** Perforator dissected out. **D.** Flap inset into the defect and the donor site closed primarily. **E, F.** Flap and the donor site after 3 months

**Patient 3:**



**Fig 6: A.** Post-burn contracture of the elbow. **B.** Propeller flap elevated over proximal radial artery perforator. **C.** Close-up of the perforator. **D.** Flap rotated into the defect. **E.** Donor site skin grafted. **F.** Flap and donor site on follow-up

**Patient 4:**



**Fig 7: A.** Ectopiavesicae defect on lower abdomen. **B.** Flap planned over Dopplered perforator. **C.** Intramuscular dissection of the perforator through vastuslateralis. **D.** Perforator dissected proximally to include the source vessel i.e. Lateral circumflex femoral artery. **E.** Flap inset into defect and donor site closed primarily. **F.** Flap after 3 months of follow-up

**Acknowledgement:**

No financial support is reported.

**Conflict of Interest:**

The authors declare no conflict of interest.

**REFERENCES :**

1. Koshima I, Soeda S. Inferior epigastric artery skin flaps without rectus abdominis muscle. *Br J Plast Surg* 1989;42:645-648
2. Hyakusoku H, Yamamoto T, Fumiiri M. The propeller flap method. *Br J Plast Surg* 1991;44:53-4.
3. Hallock GG. The propeller flap version of the adductor muscle perforator flap for coverage of ischial or trochanteric pressure sores. *Ann Plast Surg* 2006;56:540-2.
4. Pignatti M, Ogawa R, Hallock GG, et al. The "Tokyo" consensus on propeller flaps. *Plast Reconstr Surg* 2011;127:716-22.
5. Phillip N, Blondeel, Steven F. Morris, Geoffrey G. Hallock, Peter C. Neligan ed. *Perforator Flaps: anatomy, technique and clinical applications*. St. Louis, Missouri. Quality Medical Publishing, Inc. 2006
6. Mathes SJ, Nahai F. Flap selection, analysis of features, modifications and applications. In: Mathes SJ, Nahai F, eds. *Reconstructive Surgery: Principles, Anatomy & Technique*. New York: Churchill Livingstone; 1997:37
7. Teo TC. Perforator local flaps in lower limb reconstruction. *Cir Plast Iberlatinamer* 2006;32:15-6.
8. Georgescu AV, Matei I, Ardelean F, et al. Microsurgical non-microvascular flaps in forearm and hand reconstruction. *Microsurgery* 2007;27:384-94
9. D'Arpa S, Cordova A, Pignatti M, et al. Freestyle pedicled perforator flaps: safety, prevention of complications, and management based on 85 consecutive cases. *Plast Reconstr Surg* 2011;128:892-906.
10. Wong CH, Cui F, Tan BK, et al. Nonlinear finite element simulations to elucidate the determinants of perforator patency in propeller flaps. *Ann Plast Surg* 2007;59:672-8.
11. Hýža P, Streit L, Schwarz D, Kubek T, Gilboe HE, Veselý J. Vasospasm of the flap pedicle - the new experimental model on rat. *Acta Chir Plast*. 2014;56(1-2):3-11.
12. Georgescu AV. Propeller perforator flaps in distal lower leg: evolution and clinical applications. *Arch Plast Surg*. 2012 Mar;39(2):94-105. doi: 10.5999/aps.2012.39.2.94. Epub 2012 Mar 14.
13. Panse NS, Bhatt YC, Tandale MS. What is safe limit of the perforator flap in lower extremity reconstruction? Do we have answers yet? *Plast Surg Int* 2011;2011:349357