



MORPHOLOGICAL VARIATIONS OF COMMON CAROTID ARTERY: A CADAVERIC STUDY IN TELANGANA REGION

Anatomy

Dr. Aparna Veda Priya . K I/C Professor & HOD, Dept of Anatomy, Osmania Medical College, Koti, Hyderabad, Telangana.

Dr. Niveditha Samala Assistant professor, Department of Anatomy, Osmania Medical College, Koti, Hyderabad, Telangana.

Dr. Heena Fathima* Post graduate, Dept of Anatomy, Osmania Medical College, Koti, Hyderabad, Telangana.
*Corresponding Author

ABSTRACT

INTRODUCTION: Common carotid artery chiefly supplies the head and neck region. Each common carotid artery bifurcates at the level of superior border of thyroid cartilage of larynx into External and Internal carotid arteries.

AIMAND OBJECTIVES: To describe the variations of the levels of bifurcation of

MATERIAL AND METHODS: Present study was conducted on 22 formalin fixed adult cadavers (44 carotid arteries) during routine dissection for medical students in Osmania Medical College, Hyderabad, Telangana for a period of two years (April 2018-March 2020). Bifurcation results were noted with respect to thyroid cartilage.

RESULTS: In the present study the standard bifurcation of common carotid artery was found in 54.5%, high bifurcation was found in 36.3% and low bifurcation was observed in 9.2% of the cases.

CONCLUSION: Standard level of bifurcation of common carotid artery was found to be more common in the present study. The anatomical levels of common carotid artery bifurcation is decisive clinically and surgically. Anatomical knowledge of common carotid artery is useful in Angiographic studies, Trans catheter embolization procedure.

KEYWORDS

Common carotid artery, Bifurcation, Thyroid cartilage

INTRODUCTION:

Common carotid system serves as a major source of arterial supply in the head and neck region¹. The common carotid artery arises from the arch of aorta on the left side and from brachiocephalic trunk on the right side. Each common carotid artery extends upwards and laterally from the sterno- clavicular joint to the upper border of lamina of thyroid cartilage and bifurcates into Internal and External carotid artery. Internal carotid artery is situated postero-laterally and External carotid artery is placed antero-medially in the Carotid triangle².

The common carotid artery may bifurcate at higher or lower than the usual levels. The bifurcation can occur as high as C1 or as low as T2. High level of bifurcation is associated with high incidence of penetrating vascular injuries³. The knowledge of bifurcation of common carotid artery is essential in Diagnostic imaging, Radical neck dissections, cervical dissection, Carotid end arterectomy, Catheterization and Aneurysms⁴.

AIMAND OBJECTIVES:

To describe the variations of levels of bifurcation of Common carotid artery with respect to lamina of Thyroid cartilage in Telangana region.

MATERIAL AND METHODS:

The present study was conducted on 22 formalin fixed adult cadavers (44 carotids) during routine dissection for medical students at Osmania Medical College, Hyderabad, Telangana state for a period of two years (April 2018-March 2020). The sides of neck were dissected according to the standard procedures of Cunningham's manual of dissection volume iii and common carotid arteries were exposed in the carotid triangle. The bifurcation levels of Common carotid arteries were observed with reference to upper border of Thyroid cartilage.

The cadavers with considerable damage to Common carotid artery, the cadavers in which embalming was done through Common carotid artery were excluded from the study.

OBSERVATION AND RESULTS:

A total of 22 adult cadavers (44 carotids) were dissected and results of the study were represented in table no: 1.

The present study considered the upper border of Thyroid cartilage as the standard bifurcation point of common carotid, any bifurcation noted above this level was considered as high and below this level as low bifurcation of common carotid artery.

Table no: 1 Showing the bifurcation pattern of common carotid artery. The standard bifurcation of common carotid artery was found on 24 sides (54.5%)(fig 1), higher bifurcation was observed in 16 sides(36.3)(fig 2) and low bifurcation was observed on 04 sides of neck (9.2%)(fig 3)

Level of bifurcation	No .of common carotid arteries	Percentage
High	16	36.3%
Standard	24	54.5%
Low	04	09.2%

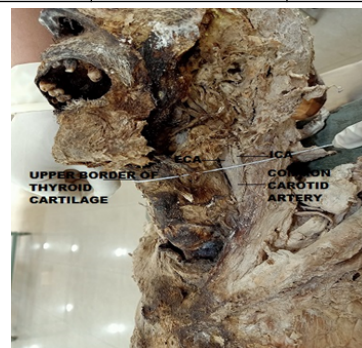

Fig:1 Standard Bifurcation Of Common Carotid Artery



Fig 2: Higher Bifurcation Of Common Carotid Artery

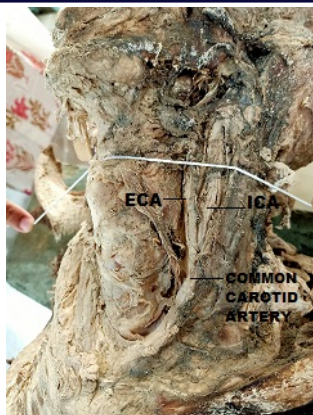


Fig 3: Lower Bifurcation Of Common Carotid Artery

DISCUSSION:

The bifurcation of common carotid artery usually occurs at the upper border of Thyroid cartilage. Variations in the termination of common carotid artery due to differences in the level of embryological origins of External carotid artery⁷.

These variations are important for plastic surgeons to get a blood less field and to avoid iatrogenic injuries during head and neck surgeries.

The results of present study compared with findings of several other studies and are represented in **Table No2**

S. No	Author and year	Sample size	Standard bifurcation (%)	High bifurcation (%)	Low bifurcation (%)
1	S.Shivaprakash et al 2014(3)	50	38	40	22
2	Woldeyes DH 2014 (6)	26	53.8	46.15	-
3	Hayashi n et al 2005 (7)	80	57.5	31.2	11.3
4	Lucev n et al 2005 (8)	40	50	37.5	12.5
5	Al Rafiah et al 2011 (9)	60	48.3	43.3	8.3
6	Vrinda hari A et al 2018 (10)	30	53.3	30	16.67
7	Present study	44	54.5	36.3	9.2

In the present study the standard bifurcation of the Common carotid artery was found in 54.5%, high bifurcation and low bifurcation was found in 36.3% and 9.2% of samples respectively. These findings were close to the results of studies done by Hayashi et al, Lucev et al.

These variations should be kept in mind during surgical approaches in the head and neck region as high level of bifurcation are associated with increased incidence of penetrating vascular injuries.

CONCLUSION:

In our study standard level of bifurcation was found to be more common than High level bifurcation. Anatomical level of Common carotid artery bifurcation is decisive clinically as well as surgically. Anatomical knowledge of variations of common carotid artery will be useful in Angiographic studies, Transcatheterization, Embolization procedures.

Conflicts Of Interest: None

Acknowledgements

We would like to thank all who donated their bodies and students for participating in the cadaveric dissection process.

Funding: No funding sources

Conflict of interest: None declared

Ethical approval: The study was approved by the Institutional Ethics Committee

REFERENCES

1. Anasuya ghosh IJRMS-2019
2. Padmashree B.R.-IJAR-2017
3. S.Shivaprakash-IJHSR-2014
4. Blanca Mompea-EUR J.ANAT 2015
5. N.Shankar- EUR J.ANAT 2008.
6. Woldeyes DH. Anatomical variations of the common carotid artery bifurcations in relation to the cervical vertebrae in Ethiopia. *Anatomy Physiol.* 2014;4:2161-0940.
7. Hayashi N, Hori E, Ohtani Y, Ohtani O, Kuwayama N, Endo S. Surgical anatomy of the cervical carotid artery for carotid endarterectomy. *Neurol Med Chirurgica.* 2005;45(1):25-30.
8. Lucev N, Bobinac D, Marić I, Dreščik I. Variations of the great arteries in the carotid triangle. *Otolaryngol Head Neck Surg.* 2000;122(4):590-1.
9. Al-Rafiah A, El-Haggagy AA, Aal IH, Zaki AI. Anatomical study of the carotid bifurcation and origin variations of the ascending pharyngeal and superior thyroid arteries. *Folia Morphol.* 2011;70(1):47-55.
10. Vrinda Hari.A-IJAR-2018
11. Bheemshetty S.-IJAV-2012
12. Standring S. *Gray's anatomy: the anatomical basis of clinical practice.* 39th Ed. Elsevier, Churchill Livingstone, New York; 2015. es