



“CERVICAL LYMPHADENOPATHY AND ITS ETIOLOGY IN CHILDREN: A STUDY IN A TERTIARY HEALTH CARE INSTITUTE.”

ENT

Dr Kumkum Bora Associate Professor, Department of ENT, Gauhati Medical College and Hospital

Dr Uma Roy Post Graduate Trainee, Department of ENT, Gauhati Medical College and Hospital

ABSTRACT

Background: Lymphadenopathy occurs in a number of cases presenting in ENT out-patient department. Most cases are found to have enlarged cervical lymph glands. Lymphadenopathy is a condition affecting the lymph nodes of the body as a result of infection, benign or malignant conditions. As a result, lymph nodes become enlarged and abnormal in size, shape, consistency and they may show fixity, abnormal mobility or symptoms that differ from normal. This is due to fluid accumulation and action of lymphocytes. The most common form is lymphadenitis when it is due to inflammation. Inflammation may spread from surrounding soft tissue via lymphatic vessels or direct involvement of the lymph glands. A study was conducted to have an idea about the most common cause of cervical lymphadenopathy in children as most common region of lymph node in children is cervical groups of lymph nodes. **Methods and Materials:** A hospital-based prospective study was conducted in the department of otorhinolaryngology and head and neck surgery, from a time period of October 2021 to March 2022 and results analysed from the collected data. **Results:** Reactive lymphadenopathy due to viral or bacterial infections is the leading cause followed by systemic and malignant diseases. **Discussion:** Inflammatory response is the leading cause of cervical lymphadenopathy in children.

KEYWORDS

INTRODUCTION:

The lymph nodes are an essential part of body's immune system and as such are affected by many infectious, autoimmune, metabolic and malignant diseases. The cervical lymph nodes are particularly important because they are the first drainage stations for key points of contact with outside world. Cervical lymphadenopathy is the enlargement of the lymph nodes (>1 cm diameter) of the neck, including preauricular, parotid, jugulodigastric (at the angle of the jaw), submental, submandibular, posterior cervical, superficial cervical, deep cervical, occipital and posterior auricular (mastoid) lymph nodes.^[1] Cervical lymph node enlargement is a common finding in children with viral or bacterial infection that presents on out-patient basis. Enlarged, palpable lymph nodes are common due to the reactive hyperplasia of lymphatic tissue mainly connected with local inflammatory process.^[2] About 38 to 45% of otherwise normal children have palpable lymph nodes.^[3,4] Cervical lymphadenopathy affects as many as 90% of children aged 4 to 8 years.^[5] In many cases, they were occasional findings during examination. The condition most commonly represents a transient response to benign local or generalized infection, but occasionally it might herald the presence of a more serious disorder. Among the children who presented in out-patient department as neck swelling, majority are followed by acute viral respiratory infection or acute bacterial infection of upper respiratory tract that are mostly caused by streptococcal pharyngitis or staphylococcal infection. Generalized lymphadenopathy is often caused by viral infection and less frequently by malignancies, collagen vascular disorders and medications. Systemic infections also cause lymph node enlargement in neck which is mostly due to tuberculosis and also by diseases such as infectious mononucleosis, cat scratch disease, toxoplasmosis. Laboratory tests are often not necessary in the majority of children with cervical lymphadenopathy. As treatment of the primary cause is shown to cause regression most cases of cervical lymphadenopathy. Among those effected, localization may be on anterior triangle of the neck or posterior triangle or in some cases both anterior and posterior triangles can get involved.

Supraclavicular or posterior cervical lymphadenopathy carries a much higher risk for malignancies than does anterior cervical lymphadenopathy. It also calls for ruling out tubercular cause the posterior triangle lymph nodes get enlarged. A study was carried out to assess the incidence of children with enlarged cervical lymph nodes in a tertiary health centre. Condition of lymphadenitis are classified as – 1) Acute (less than 2 weeks), 2) Subacute (2 to 6 weeks) and 3) Chronic (more than 6 weeks). There has been limited evidence to suggest a single definitive approach to the management of cervical lymphadenitis in children.

The aim of the study was to study the etiological factors of cervical lymphadenopathy based on its incidence among children.

AIMS AND OBJECTIVE:

To study the etiological factors of cervical lymph nodal enlargement among children who present as cases of neck swelling in out-patient department.

MATERIALS AND METHODS:

A study was carried out in 60 patients in the out-patient department of Otorhinolaryngology, Gauhati Medical College and Hospital.

Study design was hospital-based Prospective study of children with cervical lymphadenopathy.

Location:

Gauhati Medical College and Hospital, Department of Otorhinolaryngology and Head and Neck surgery in a time October 2021 to March 2022.

Sample Size:

A sample size of 60 patients were taken for analysis

Inclusion Criteria:

Children below 14 years of age with enlarged neck glands were included in this study.

Exclusion Criteria:

Children above 14 years of age were not included. Also children with neck swelling in which the diagnosis was made to be other than lymphadenopathy after clinical examination and investigation, were kept out from the analysis.

Children below 14 years of age, who attended out patient department of Otorhinolaryngology with the complaints of swelling or pain the neck were examined. After thorough history taking and clinical examination, those having palpable lymph nodes were included for the study and given treatment according to the signs, symptoms and provisional clinical diagnosis. Those cases in which neck swelling was other than lymph nodes such as soft tissue, muscular swelling, cystic swelling or lump were excluded from study sample. For the patients diagnosed to be viral, bacterial infection, adequate management was done and followed up. While those lymphadenopathy as a cause of tuberculosis and hematological conditions such as lymphoma, FNAC, ultrasonography of neck performed for diagnosis. Results were analysed.

Review of Literature:

Lymph node: These are oval, bean shaped structures scattered throughout body along lymph vessels and usually 1-25 mm in length. May be superficial or deep. These are filled with lymph and trap foreign particles, organisms, cell debris and tumour cells.

Structure of a Lymph node:

Outer capsule that contains stroma which is differentiated into cortex and medulla. Outer cortex is filled with lymph follicles containing T-cells. Inner germinal layer is the site of B-cell proliferation. Medulla composed of plasma cells, macrophages and lymphocytes.

Afferent vessels bring the lymph in into subcapsular sinus. Because of fewer efferents, lymph flow somewhat stagnates in the nodes.

Cervical groups of lymph nodes:

- a) Superficial group
- b) Deep group

Submental group:

Situated in midline, inferior to mandible and in between two anterior bellies of digastric.

Submandibular group:

These are divided into six groups- preglandular, prevascular, retrovascular, retroglandular, interglandular and deep nodes.

Jugular chain:

Eighty percent of lymph nodes of neck are closely associated with internal jugular vein.

The jugulodigastric nodes are the first echelon nodes for the drainage of posterior faucial region, especially palatine tonsil. Others are middle jugular and lower jugular nodes.

Posterior nodes:

Lymph node levels: The most widely accepted system for describing lymph node levels is taken from Sloan Kettering Memorial Hospital and was adopted by American Academy of Otolaryngology and Head and Neck Surgery in 1991. It divides the neck into six levels from level 1 to level 6.

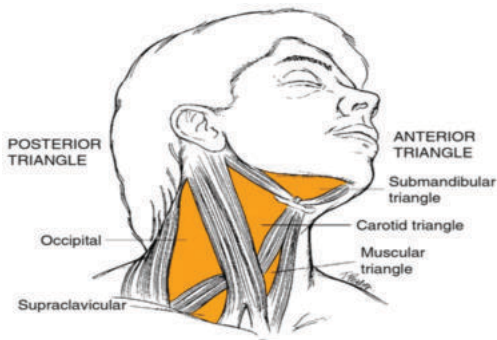


Fig 1: Triangles of neck^[15]

RESULTS:

Data gathered from those results were analysed statistically and shown below.

Sl. no	Disease or pathology	male cases	female cases
1	Inflammatory	30	22
2	malignancy	4	2
3	Systemic causes	2	0

Fig 2: Table showing no of children having cervical lymphadenopathy and their etiology.

In the study, majority of children (86.67%) having cervical lymphadenopathy cases were found to be due to inflammatory causes as a response to viral or bacterial infections forming 86.67%, followed by malignant causes found in 10% cases and systemic cause rest 3.33% of cervical lymphadenopathy in those children.

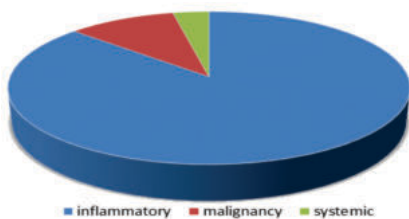


Fig 3: Pie chart showing frequency of cervical lymphadenopathy in

children according to etiology

Sl. no	Neck triangles involved in cervical lymphadenopathy	No. of cases
1	Anterior	28
2	posterior	16
3	Both anterior and posterior	16

Fig 4: Table showing involvement of different neck triangles in cervical lymphadenopathy in children.

AGE	MALE	FEMALE
0-1year	1	0
2-5years	18	14
6-10years	11	8
11-14years	6	2

Fig 5: Table showing age distribution of children with cervical lymphadenopathy

DISCUSSION:

A total of 60 cases below 14years of age were analysed for cervical lymphadenopathy. Among them 36 were males and 24 were females. Male predominance in the present study is also comparable with other studies.^[6,10,11,12]

In majority of children (86.67%), most common cause of cervical lymphadenopathy was found to be inflammatory response to viral and bacterial infections that formed 86.67% of the study sample. Malignant diseases such as Hodgkin lymphoma and Non-Hodgkin lymphoma formed 10% cases and rest (3.33%) were found to be due to systemic causes such as tuberculosis and infectious mononucleosis.

In 22 no of cases, anterior triangle lymph nodes were found enlarged and those were mostly due to acute viral or bacterial infections. In 4 cases, posterior triangle lymphadenopathy was noted and in 14 cases lymph nodes from both anterior and posterior triangle were palpable. Knight et al^[6] and Reddy et al^[7] observed in their study of children with cervical lymphadenopathy that the predominant site was the upper anterior cervical lymph node group. Majority cases were found to be result of inflammatory response. While posterior triangle cervical lymphadenopathy was found mostly in malignant causes.

From the study, it is found that inflammatory or reactive response to acute viral infection and bacterial infection is the major cause (86.67%) of cervical lymph node in children below 14 years of age. According to Srouji et al, tenderness, mobility and fluctuating size of the nodes are clinical features associated with reactive lymphadenopathy.^[8] Of all those cases, the diagnosis was mostly clinically and management of viral and treatment of the bacterial infection with antibiotics and supportive therapy showed to regress the size of lymph nodes. Failure of regression after 4—6 weeks might be an indication for a diagnostic biopsy.^[9]

10% cases were found to have enlarged lymph nodes because of malignancy including both Hodgkin and non-Hodgkin lymphoma. Those cases were found to have axillary and inguinal lymph node enlargement as well in some cases. Patients with malignant features should undergo early excisional biopsy.^[13] Systemic causes were found to contribute to 3.33% of cases having lymphadenopathy along with other sites and symptoms and signs. Those cases were diagnosed to be tuberculosis and infectious mononucleosis. Management of the primary or systemic cause was necessary in those cases. Regular follow-up (at least monthly) is essential to see response to standard antituberculosis treatment.^[14]

CONCLUSION:

Inflammatory or reactive response is the major cause of cervical lymphadenopathy in children that accounts for 85-90% of cases. Other causes of enlarged cervical lymph node includes mostly malignant causes. A small percentage (3.33%) of children had systemic response and had cervical lymph nodal enlargement as a consequence.

CONSENT:

Written and informed consent was obtained from the patients or their guardians regarding the use of their clinical findings and reports of the investigations that were conducted.

Disclosure Statement:

No potential conflict of interest was reported by the authors.

REFERENCES:

1. Sarper N, Passali GC. Cervical Lymphadenopathy in Children. In *Pediatric ENT Infections 2022* (pp. 251-261). Springer, Cham.
2. Niedzielska G, Kotowski M, Niedzielski A, Dybiec E, Wieczorek P. Cervical lymphadenopathy in children—incidence and diagnostic management. *International journal of pediatric otorhinolaryngology*. 2007 Jan 1;71(1):51-6.
3. Genc B. Çocukluk Çağında Lenfadenopatilere Yaklaşım. Approach to Childhood Lymphadenopathy. *The Journal of Pediatric Research* 2014;1:6-12.
4. Rajasekaran K, Krakovitz P. Enlarged neck lymph nodes in children. *Pediatr Clin North Am* 2013;60:923-36.
5. Weinstock MS, Patel NA, Smith LP. Pediatric cervical lymphadenopathy. *Pediatrics in review*. 2018 Sep;39(9):433-43.
6. Knight PJ, Mulne AF, Vassy LE: When is lymphnode biopsy indicated in children with enlarged peripheral lymphnodes? *Paediatrics* 1982;69:142-148
7. Reddy PM, Moorchung N, Chaudhary A: Clinicopathological profile of pediatric lymphadenopathy. *Ind J Pediatr* 2002;69:1047-1051
8. I.A. Srouji, N. Okpalaa, E. Nilssena, S. Birchb, P. Monneryc, Diagnostic cervical lymphadenectomy in children: a case for multidisciplinary assessment and formal management guidelines, *Int. J. Paediatr. Otolaryngol.* 68 (2004) 551—556
9. P.J. Chesney, Cervical lymphadenopathy, *Pediatr. Rev.* 15(1994) 276—284.
10. Kissane JM, Gephardt JN: Lymphadenopathy in childhood: Long-term follow-up in patients with non-diagnostic lymphnode biopsies. *Human Pathol* 1974;5:431-439
11. Murthy MTV: Tuberculous lymphadenitis in children. *Indian Pediatr* 1978;18:533-538
12. Annam V, Kulkarni MH, Puranik RB. Clinicopathologic profile of significant cervical lymphadenopathy in children aged 1-12 years. *Acta cytologica*. 2009;53(2):174-8.
13. Wang J, Pei G, Yan J, Zhao Q, Li Z, Cao Y, Li J, Zhang G, Chen H, Hao X. Unexplained cervical lymphadenopathy in children: predictive factors for malignancy. *Journal of pediatric surgery*. 2010 Apr 1;45(4):784-8.
14. Marais BJ, Wright CA, Schaaf HS, Gie RP, Hesselning AC, Enarson DA, Beyers N. Tuberculous lymphadenitis as a cause of persistent cervical lymphadenopathy in children from a tuberculosis-endemic area. *The Pediatric infectious disease journal*. 2006 Feb 1;25(2):142-6.
15. Paul Flint, Bruce Haughey, Valerie Lund, K. Robbins, J. Regan Thomas, Marci Lesperance, Howard W. Francis. Cummings Otolaryngology Head and Neck Surgery, 3-Volume Set 7th Edition. 2020 April 22