



CT BASED ANATOMICAL VARIATIONS IN SPHENOID SINUS FOR UNIQUE IDENTIFICATION.

Biochemistry

Dr. Shiekh Amir Department of Forensic Medicine, GMC Srinagar.

Dr. Sadaf Ali* Department of Biochemistry, GMC Srinagar. *Corresponding Author

Dr. Omar Mohammad Shafi Department of ENT, GMC Srinagar.

Dr. Rassieq Aslam Department of Radiology, GMC Srinagar.

ABSTRACT

Aim of this study was to observe the anatomical variations of sphenoid sinus and its relation to various adjoining neurovascular structures. This study was conducted on 60 living subjects. Computed Tomography scans of the study participants were taken in axial, sagittal and coronal planes. Contiguous 1 mm thick slice CT technique was used. Pterygoid process pneumatization was found in 18 patients (30%), ACP in 9 patients (15%). Anterior wing of sphenoid pneumatization was seen in 12 patients (20%). It was observed that in 25 patients (41%) internal carotid artery was protruding in the sphenoid sinus. Optic nerve protrusion was present in 21 patients (35%). Protruding maxillary nerve and vidian nerve was found in 13 patients (21.6%) and 24 patients (43%) respectively. Additionally, dehiscence of different structures such as optic nerve, maxillary nerve, internal carotid artery and vidian nerve was encountered in 31.6%, 11.6%, 30% and 38.3% respectively.

KEYWORDS

Computed tomography, Pneumatization, Sphenoid sinus.

INTRODUCTION

Identification plays a key role in disasters – fire, transportation accident and explosive incidents. It is a basic requirement for any criminal investigations. Human bone remains are helpful for identification in medicolegal investigations. In anthropology, identification is used in order to find population diversity, sexual dimorphisms, and age-associated changes. The most commonly used techniques for identification purposes are dactylography, dental assessment, and DNA fingerprinting. Skull bone is considered second best bone to establish identification after pelvis. In cases like completely charred bodies DNA is severely damaged, then fingerprints or DNA analysis cannot be performed. Anthropological method is the preferable choice under such circumstances further aided by comparative radiography.^{1,3} Computed tomography is ideal imaging technique to study paranasal sinuses.^{1,4,7}

Air present in paranasal sinuses makes the skull lighter, offers resonance to the voice and makes inspired air moist and warm. These sinuses are essential for medical doctors because of the diseases like sinusitis and its complications. In human skull four important paranasal sinuses are frontal, maxillary, ethmoid and sphenoid sinuses.¹ Pneumatization of sinuses shows a discrepancy in different individuals. Similar variations are also seen in sphenoid sinus and its relations with the adjacent neuro-vascular structures.¹ These variations in relations are noteworthy for the surgeons to avoid complications during surgeries. Sphenoid bone is the keystone of skull, as it is connected to both neuro-cranium and viscerocranium by articulations with most of the skull bones.²

The sphenoid sinus lies within the body of sphenoid bone, and is seen in primates like humans, apes, and monkeys and not seen in other animals. The sphenoidal sinus neighbours vital structures like the cavernous sinus, optic nerve and hypophysial gland, with only thin bone walls separating it from these structures.² The sinus is first noted as early as 2 to 3 years of age in radiographs and achieves its mature size in adolescence (at the age of approximately 12–14 years, but it keeps on growing throughout life. The sphenoidal sinus is generally classified into three types: conchal, presellar, and sellar, according to the extension of pneumatization around the sella turcica.^{3,8,9}

Although there are many studies done with plain radiograph in forensic identification but the amount of studies with CT scan is still limited.⁵ The intend of the study is to develop a modernised and practical record system of identification by using CT scan of sphenoid sinus and anatomical variations and their relation to adjacent neurovascular structures.

MATERIALS AND METHODS:

A cross sectional study was carried out in SMHS Hospital, Srinagar during the period of January 2019 to August 2019. Total of 60 CT scans were selected randomly from participants after fulfilling our inclusion

and exclusion criteria.

Computed Tomography scans of 60 living subjects (males 32 and females 28) in axial, sagittal and coronal planes were taken. Contiguous 1 mm thick slice CT technique was used.

INCLUSION CRITERIA:

The type of pneumatization, protrusion or dehiscence of neurovascular structures was studied. Subjects were between the ages of 18 to 60 years.

EXCLUSION CRITERIA:

Subjects with acute or chronic sinusitis, FESS, trans-sphenoid surgery, head injury or intra-cranial infection were excluded from the study.

CT sections were studied with respect to the variations in pneumatization of the sinus, with addition to that we also studied association of protrusion or dehiscence of the optic nerve, maxillary nerve, internal carotid artery and vidian nerve with sphenoid sinus.

RESULTS:

Table 1: Relation of Pneumatization with ACP, GWS, and PP

Pneumatization	Bilateral	Right side	Left side	Total	Percent age
Anterior clinoid process	4	3	2	9	15
Greater wing of sphenoid	5	3	4	12	20
Pterygoid process	8	4	6	18	30

ACP: Anterior clinoid process, GWS: Greater wing of sphenoid, PP: Pterygoid process

Table 2: Relation of Protrusion with ICA, ON, MN, VN

Protrusion	Bilateral	Right side	Left side	Total	Percent age
Internal carotid artery	14	7	4	25	41
Optic nerve	12	4	5	21	35
Maxillary nerve	4	5	4	13	21.6
Vidian nerve	8	4	12	24	40

ICA: Internal carotid artery ON: Optic nerve, MN: Maxillary nerve, VN: Vidian nerve

Table 3: Relation of Dehiscence with ICA, ON, MN, VN

Dehiscence	Bilateral	Right side	Left side	Total	Percent age
Internal carotid artery	6	9	3	18	30
Optic nerve	6	8	5	19	31.6
Maxillary nerve	2	3	2	7	11.6
Vidian nerve	10	6	7	23	38.3

ICA: Internal carotid artery ON: Optic nerve, MN: Maxillary nerve, VN: Vidian nerve

Pneumatisation of pterygoid process was found in 18 patients (30%), ACP in 9 patients (15%). Pneumatisation of anterior wing of sphenoid was seen in 12 patients (20%). It was observed that in 25 patients (41%) internal carotid artery was protruding in the sphenoid sinus. Optic nerve protrusion was present in 21 patients (35%). Protruding maxillary nerve and vidian nerve was found in 13 patients (21.6%) and 24 patients (43%) respectively. Additionally, dehiscence of various structures such as internal carotid artery, optic nerve, maxillary nerve and vidian nerve was encountered in 31.6%, 11.6%, 30% and 38.3% respectively.

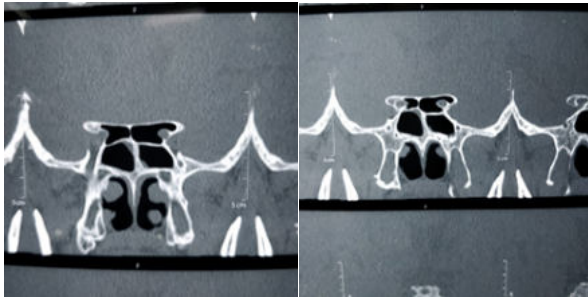


Fig: 1(A) and Fig: 1 (B) showing Coronal CT scan images through sphenoid sinus shows bilateral Onodi cells and dehiscence of right optic canal and intra sinus course of left optic nerve.

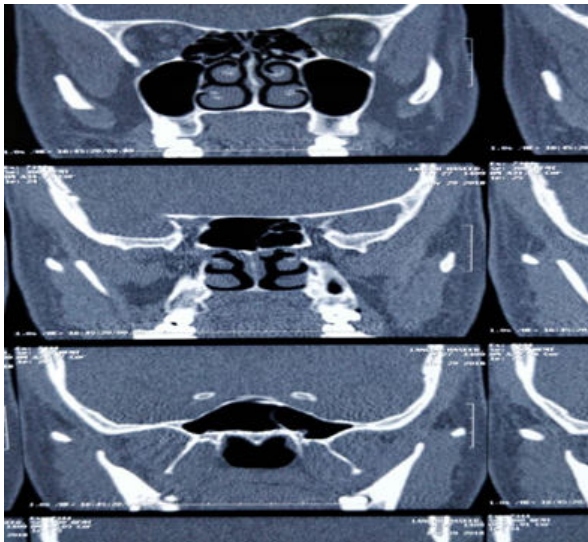


Fig: 2. Coronal CT scan showing left sided intra sphenoid septae arising from left optic canal

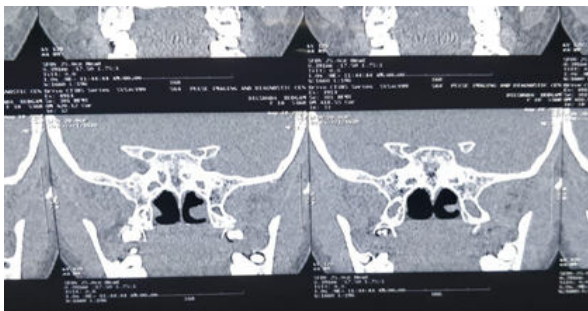


Fig: 3. Coronal CT cuts through sphenoid sinus showing incomplete septum

DISCUSSION:

According to the anatomy, normal sphenoid sinus consists of two symmetrical cavities separated by intersphenoidal septum placed in the midline and doesn't usually intrude the adjacent neuro-vascular structures.¹ According to different studies variations like absence of accessory septa, protrusion and dehiscence of various adjacent neuro-

vascular structures are seen in the sinus.^{1,3} Pneumatisation commences when the sphenoid fatty conversion areas are invaded by the respiratory mucosa.² In cases where this process fails this will lead to arrest in pneumatisation in adults.⁷ In many studies post-sellar variety is common except in Libyan population.^{1,8,9} Post-sellar variety is favourable for trans-sphenoid approach into intra-cranial surgeries. However, in the conchal type, special instruments are required by surgeons for the successful procedure.

According to the results shown by **Hewaidi GH et al.**, there was significant relation between pneumatisation of GWS with the protrusion of MN, PP with the VN and ACP with the ON.³ According to the study results of **Bolger et al.**, pneumatisation of ACP was found in 15%, of GWS in 20% and that of PP in 29% of the patients.⁷

John Earwaker identified pneumatisation of ACP in 13% and of PP in 43% patients, found pneumatisation of GWS in 20% of patients.⁴ ACP pneumatisation was observed in 4% and in 24% of patients.^{5, 10} respectively.

Fuji et al., observed 8% dehiscence ICA, 4% dehiscence ON.⁶ Another study conducted by **Birsen et al.**, showed protrusion and dehiscence of ICA in 30.3% and 3.5% of patients.⁵

CONCLUSION:

In our study we analysed the types, subtypes, dimensions, and septation outlines of the sphenoid sinus of cranium of 60 patients. This was done by studying the CT scan reports of head in these patients but without sinus pathology. Our study results may prove beneficial in formulation of a database for the Kashmiri population in view of sphenoid sinus patterns. Sphenoid sinus is highly variable; therefore careful preoperative assessment for surgery in this region is necessary to smooth the progress of safe entry through the sinus to various target areas.

Sphenoid sinus is surrounded by important neurovascular structure. According to our study sphenoid sinus of each individual is different. Therefore, sphenoid sinus pattern matching may be helpful in some cases of forensic identification. In future methods for sphenoid sinus pattern studies similar to that of fingerprint analysis may be developed. This would help the implementation of standardized methods for human identification using the metric variables of the sphenoid sinus.

REFERENCES

1. Chougale MS, Dixit D. A cross-sectional study of sphenoid sinus through gross and endoscopic dissection in North Karnataka, India. *Journal of Clinical and Diagnostic Research*. 2014; 8(4):AC01-05.
2. Gurevitch O, Slavin S, Feldman AG. Conversion of red bone marrow into yellow cause and mechanisms. *Med Hypotheses*. 2007; 69:531-36.
3. Hewaidi GH and Omami GM. Anatomic variation of sphenoid sinus and related structures in Libyan population: CT scan study. *Libyan Journal of Medicine*. 2008; 49:01-08.
4. Earwaker J. Anatomic variants in sinonasal CT. *Radiographics*. 1993; 13:381-415.
5. Birsen U, Gulsah B, Yasemin K. Risky anatomic variations of sphenoid sinus for surgery. *Surg Radiol Anat*. 2006; 28:195-201.
6. Fuji K, Chambers A, Rhoton J. Neurosurgical relationships of the sphenoid sinus: a microsurgical study. *J Neurosurgery*. 1979; 50:31-39.
7. Bolger WE, Butzin CA, Parsons DS. Paranasal sinus bony anatomic variations and mucosal abnormalities: CT analysis for endoscopic sinus surgery. *Laryngoscope*. 1991; 101:56-64.
8. Elwany S, Yacout YM, Talaat M, El-Nahass M, Gunied A. Surgical Anatomy of the Sphenoid Sinus. *The Journal of Laryngology and Otology*. 1983; 97:227-41.
9. Sethi DS, Pillay PK. Endoscopic management of lesions of the sella turcica. *The Journal of Laryngology and Otology*. 1995; 109: 956-62.
10. Delano MC, Fun FY, Zinrich SJ. Relationship of optic nerve to the posterior paranasal sinuses: a CT anatomic study. *Am J Neuroradiol*. 1996; 17:669-75.