



## DIAGNOSTIC LAPAROSCOPY IN SUSPECTED ABDOMINAL TUBERCULOSIS: A TOOL FOR DIAGNOSIS

### General Surgery

**Sunitha Raghu Kumar\***

Assistant Professor, Department of Surgery, BGS Global Institute of Medical Sciences, Bangalore. \*Corresponding Author

**Lokesh M N**

Associate Professor, Department of Surgery, BGS Global Institute of Medical Sciences, Bangalore.

**Satish V**

Professor and Head of Department, Department of Surgery, BGS Global Institute of Medical Sciences, Bangalore.

### ABSTRACT

**Background:** Abdominal tuberculosis has plagued mankind over decades and is a major reason of morbidity and mortality even today in the developing world. Establishing a histological diagnosis in abdominal tuberculosis can be difficult, frequently delaying treatment. This study was performed with a view to evaluate the role of laparoscopy for ascertaining the diagnosis in suspected abdominal tuberculosis. **Methods:** A retrospective clinical study, wherein the records of 33 patients who underwent diagnostic laparoscopy for suspected abdominal tuberculosis over a 1-year period were analyzed to establish its usefulness as a clue to histological diagnosis. **Results:** From January 2019 to December 2019, 50 patients underwent diagnostic laparoscopies in our institution, of which 33 patients had unknown etiologies for pain abdomen and ascites. This subset of patients had been investigated for suspected abdominal tuberculosis with biochemical tests of serum and ascetic fluid, ultrasound and computed tomography before being considered for diagnostic laparoscopy. None had manifestations of extra-abdominal tuberculosis. At laparoscopy, 25 of these patients (78%) had peritoneal nodules. Histological examination performed in 29(87%) patients was suggestive of TB by presence of caseating granuloma. Only 2(6%) patients had no findings on laparoscopy, however on continued follow up, no diagnosis were made for these patients. **Conclusion:** Diagnostic laparoscopy is a potential answer for the diagnostic dilemma posed by abdominal tuberculosis. In patients suspected to have abdominal tuberculosis without evidence of extra-abdominal disease, laparoscopy may be useful to establish a histological diagnosis.

### KEYWORDS

Abdominal Tuberculosis, Diagnostic Dilemma, Diagnostic Laparoscopy.

### INTRODUCTION

Tuberculosis is a disease that has been affecting mankind since time immemorial and it still continues to be a global health concern. Globally around 10 million are affected with tuberculosis and 1.3 million died from the disease in the year 2017 [1]. In developing countries poor living conditions, overcrowding and limited access to health care facilities are the major causes of the disease [2].

Tuberculosis can affect any part of the gastrointestinal system and abdomen is the sixth most common site of involvement [3]. The sites of involvement of abdominal tuberculosis are peritoneum, lymph nodes, intestine and solid viscera. Presentation of abdominal tuberculosis always mimics many other conditions like inflammatory bowel disease and other similar conditions [4]. This state of confusion usually leads to an undue delay in diagnosis and treatment plan and thus further increases the overall morbidity. A large number of these patients present with acute abdomen and are diagnosed on exploratory laparotomy only. These laparotomies could be easily avoided had there been an efficient and reliable method to diagnose abdominal TB. This actually leads to consideration of diagnostic laparoscopy in all patients with suspected abdominal tuberculosis to find out tuberculous lesions and to take biopsy of any such foci.

Diagnosis of abdominal tuberculosis poses a challenge to the surgeon due to its clinical presentation with many vague symptoms and nonspecific signs. Histopathological confirmation is, as a rule, essential for initiation of anti-tubercular therapy in abdominal TB.

The main objective of this study is to evaluate the role of laparoscopy in establishing a histological diagnosis in suspected abdominal TB.

### MATERIAL AND METHODS

A retrospective review of case records of patients who underwent diagnostic laparoscopy for suspected abdominal tuberculosis during a 1-year period at BGS Global Institute of Medical Sciences Bangalore, India was carried out to evaluate its efficacy in establishing histological diagnosis.

All gynaecological patients and those who had histological confirmation of abdominal TB by any means other than laparoscopy (endoscopic, ultrasound or computed tomography (CT) directed biopsy) were excluded from this study. Data on age, sex, clinical presentation, diagnostic investigations, histological data, treatment

and outcome were collected and descriptive statistics were used for analysis using SPSS software.

Laparoscopy was performed under general anaesthesia in all cases, specimens of peritoneum and of the nodules were taken for histopathological examination which was confirmatory for tuberculosis when features of epithelioid granuloma with central caseous necrosis were observed, acid fast bacilli staining and cartridge based nucleic acid amplification test (CBNAAT). Samples of ascetic fluid were also sent for biochemical analysis and culture of acid fast bacilli.

### RESULTS

From January 2019 to December 2019, 248 cases of TB involving various organ systems were treated at our institution. During the same period 50 patients underwent diagnostic laparoscopies for diverse indications of which 33 cases (18 women and 15 men) were carried out for suspected abdominal TB. In this subset the age of the patients ranged from 11 to 70 years with median age of 40.5 years.

### Clinical Presentation

Twenty-one (64%) of patients had a chronic presentation with symptoms of >6 weeks duration, 7(21%) presented with sub-acute symptoms of 2-6 weeks duration, 5(15%) presented with acute symptoms of <1 week duration. Majority of the patients presented with abdominal pain 28(85%), fever 25(76%) and weight loss 24(73%). Ascites was the most common physical finding encountered 24(73%) Table 1. None of the patients had overt manifestations of extra-abdominal tuberculosis.

**Table 1. Abdominal Tuberculosis- Symptoms And Physical Finding.**

	No.	%
Duration of symptoms		
Acute <1 week	5	15%
Subacute 2-6 weeks	7	21%
Chronic > 6 weeks	21	64%
Presenting symptoms		
Abdominal pain	28	85%
Fever	25	76%
Abdominal swelling	18	55%
Weight loss	24	73%

Bowel disturbance	16	48%
Anorexia	13	39%
Physical finding		
Ascites	24	73%
Abdominal mass	3	9%
Peripheral lymph nodes	5	15%
Abdominal tenderness	9	27%

**Laboratory Findings**

Majority of patients 22 (66%) had anemia(defined as Hb<10g/dl).An elevated erythrocyte sedimentation rate was noted in 26(78%) and hypoalbuminemia in 20(61%). Mantoux test were done in 23(73%) patients and of these 8(33%) were positive. Twenty four (73%)who presented with signs and symptoms of ascites, ascetic fluid was analyzed in all .In 18(86%) patients ascetic fluid was exudative in nature (protein >2.5g/100ml).In the remaining volume of ascetic fluid was insufficient for detailed examination. Sputum examination for acid fast bacilli yielded negative result in all samples collected from all patients. Ziehl-Neelson staining for acid fast bacilli and mycobacterial culture from the peritoneal fluid were negative in all.

**Radiological Findings**

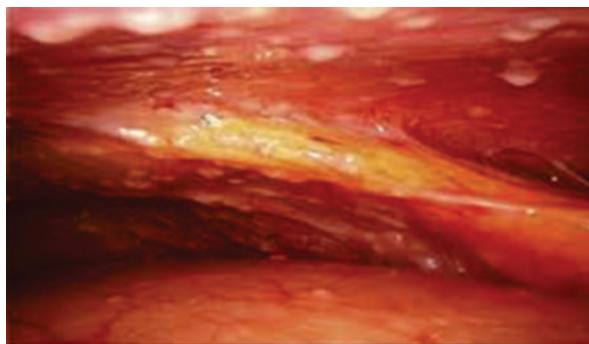
Chest X-ray done revealed no signs of tuberculosis in any of the patients. Plain films of the abdomen was done in two patients who presented with features of acute abdomen, which revealed features of intestinal obstruction. Ultrasound scan of the abdomen was performed in all patients with findings suggestive of TB in 21 of these patients (fibrinous strands in ascetic fluid, localized ascites, calcified lymph nodes);12 others were found to have ascites but no specific features,2 of the patients were found to have features of small bowel obstruction. CT scan of the abdomen was done in 18 patients, all showed a variety of positive findings including ascites in 12(67%), peritoneal nodules in 8(45%), retroperitoneal nodes in 5(28%), inflammatory mass in omentum in 2(11%) and small bowel lesion in 2(11%)Table 2.

**Table 2. Radiological Findings In Abdominal Tuberculosis.**

	Positive finding no.	Positive finding%
CT Findings		
CT done =18 patients		
Ascites	12	67%
Peritoneal nodules	8	45%
Retroperitoneal nodes	5	28%
Inflammatory mass in omentum	2	11%
Small bowel lesion	2	11%

**Laparoscopic Finding**

Out of 33 patients 31(94%) patients showed positive findings on laproscopy and in 2(6%) patients laparoscopy did not reveal any finding.Intraoperative findings revealed findings which include peritoneal nodules (Fig. 1) in 25(78%), enlarged mesenteric lymph nodes in 4(12%), stricture ileum in 2 (6%) and adhesions in 14(42%)Table 3.



**Figure 1:** Peritoneal Nodules

**Table 3. Laparoscopic Findings.**

Finding	Frequency	Percentage
Peritoneal nodules	25	78%
Mesenteric lymphadenopathy	4	12%
Adhesions	14	14%
Stricture ileum	2	6%
No abnormality detected	2	6%

Histological examination performed in 29/31 patients was suggestive of TB by presence of caseating granulomas in 29(87%).CBNNAT test for tubercular gene was sent from biopsied specimens in 18 patients and yielded positive result in 7(39%) patients. Laparoscopy did not yield any diagnosis in two (6%).However on continued follow up they remained practically healthy and additional investigations failed to show any diagnosis in these patients.

Preoperatively, two (6%) patients underwent small bowel resection for associated tubercular stricture. Four (12%) patients had ascetic leak from the wound which settled within a week.

All 31 patients with confirmed histopathological diagnosis were started on anti-tubercular medications. Their follow up over 6 months to 1 year period confirmed considerable resolution of symptoms.

**DISCUSSION**

Tuberculosis is an archetypal example of a disease with protean manifestations presenting to general physicians as well as specialists. The most common mode of presentation of abdominal TB include abdominal pain, ascites, fever and can be hard to diagnose. Existing anti-tubercular therapy is highly effective. For definitive diagnosis of TB, microbiological or histological diagnosis is obligatory. Conventional microbiological studies take 4-6 weeks and have low sensitivity [5].

Diagnostic laparoscopy in our study had excellent accuracy for diagnosis of abdominal tuberculosis equal to other series in published work [6], [7].

In present study, disease incidence was found to be more in females 18(56%)cases, males 15(45%) cases with female to male ratio of 1.2:1.The male female ratio is highly variable from equal in series reported by Ramesh et al to marked male predominance reported in Abdelaal A et al and to a marked female predominance in study of Safarpor Faizallah et al [8], [9], [10].

The most common symptom in the study was abdominal pain in 28 (85%) patients, followed by fever in 25(76%) and weight loss in 24 (73%) patients which is comparable with studies by Rai et al, Khan R et al, Islam J et al[6], [11], [12].The most consistent finding in our study and in the literature was the presence of ascites24(73%) ,although Muneef et al[13] differed in finding ascites in only 61% of their patients.

Anemia, elevated ESR and hypoalbuminemia were commonly seen in our patients .Mantoux test was positive in 24( 33%) of our patients in comparison to a study by Demir et al [14] who obtained a positive result in all their patients. Bhargava et al [15] studied 87 patients with high protein ascites , of which 38 were diagnosed to having tuberculosis, in our study 8/18(44%) were diagnosed to have tuberculosis.

The chest radiographs and sputum cultures were negative in all our patients. Ultrasonography of abdomen was suggestive of tuberculosis in 21(64%) of patients, and CBNNAT was positive in 7(39%) patients.

A laparoscopy is considered to be a crucial diagnostic tool in patients with abdominal tuberculosis. It is a safe and accurate method to inspect the peritoneum and intestinal loops and take specimens for histological examination. Its sensitivity is superior to 80%, especially in the presence of ascites. The histological study shows giant cells and epithelioid granuloma with or without caseous necrosis in 85-100% of cases[16 ], [17], [18], [19]. In our study histological diagnosis of tuberculosis was established in 29(87%) of the cases.

Peritoneal nodules was the most common finding in our study 25(78%), in comparison to studies by Nafeh et al who had 58% and Al-Mulhim et al who had 91% of their patients with peritoneal nodules [20], [21]. Adhesions were present in 14(42%) in our study which was similar to that by Nafeh et al and less than in the series by Mulhim et al(52%) [20], [21].

A biopsy is taken each time it is judged necessary, particularly if the macroscopic aspect is not conclusive [22] .Some authors contraindicate laparoscopy in the fibroadhesive form because of a high risk of perforation and the lack of provided information. We think that a

laparoscopy can be performed in all cases irrespective of the macroscopic aspect. It allows the retrieval of important elements for the diagnosis of doubtful abdominal tuberculosis.

In Ibrarullah study [7] the diagnosis was established by laparoscopy in 87% of cases. In our study, laparoscopy associated with a biopsy helped in the diagnosis of abdominal tuberculosis in all (93%) but two patients in whom laparoscopy did not yield any positive finding. Two patients (6%) underwent small bowel resection-anastomosis for associated small bowel stricture. In our study 4(12%) patients had ascetic leak from the wound in the postoperative period which settled within a week. All patients with confirmed diagnosis were started on anti-tubercular medications, complications were reported and course was uneventful in all cases with a follow up of one year.

Our study supports previous work on the value of laparoscopy the most specific diagnostic test for abdominal tuberculosis [23] with its advantage of histological confirmation [24].

In summary, we have shown in our study that in patients suspected to have abdominal TB without evidence of extra-abdominal disease, early laparoscopy associated with a biopsy is useful to establish a diagnosis, and a regular use of this diagnostic modality can improve the overall outlook of this common disease in the developing world.

## REFERENCES

- World Health Organization. Global tuberculosis report Geneva: WHO; 2018. 26 Sept; 2018.
- Kapoor VK. Abdominal tuberculosis. Postgraduate medical journal. 1998 Aug 1;74(874):459-67.
- Mehta JB, Dutt A, Harvill L, Mathews KM. Epidemiology of extrapulmonary tuberculosis: a comparative analysis with pre-AIDS era. Chest. 1991 May 1;99(5):1134-8.
- Akcam M, Artan R, Yilmaz A, Cig H, Aksoy NH. Abdominal tuberculosis in adolescents. Difficulties in diagnosis. Saudi medical journal. 2005 Jan;26(1):122-6.
- Mansour-Ghanaei F, Shafaghi A, Bagherzadeh AH, Fallah MS. Low gradient ascites: a seven-year course review. World Journal of Gastroenterology: WJG. 2005 Apr 21;11(15):2337.
- Rai S, Thomas WM. Diagnosis of abdominal tuberculosis: the importance of laparoscopy. Journal of the Royal Society of Medicine. 2003 Dec;96(12):586-8.
- Ibrarullah M, Mohan A, Sarkari A, Srinivas M, Mishra A, Sundar TS. Abdominal tuberculosis: diagnosis by laparoscopy and colonoscopy. Tropical gastroenterology: official journal of the Digestive Diseases Foundation. 2002;23(3):150-3.
- Ramesh J, Banait GS, Ormerod LP. Abdominal tuberculosis in a district general hospital: a retrospective review of 86 cases. QJM: An International Journal of Medicine. 2008 Mar 1;101(3):189-95.
- Abdelal A, Alfkey R, Abdelaziem S, Abunada M, Alfaky A, Ibrahim WH, Toro A, Di Carlo I. Role of laparoscopy peritoneal biopsy in the diagnosis of peritoneal tuberculosis. A seven-year experience. Chirurgia (Bucur). 2014 May 1;109(3):330-4.
- Safarpor F, Aghajanzade M, Kohsari MR, Hoda S, Sarshad A, Safarpor D. Role of laparoscopy in the diagnosis of abdominal tuberculosis. Saudi Journal of Gastroenterology. 2007 Jul 1;13(3):133.
- Khan R, Abid S, Jafri W, Abbas Z, Hameed K, Ahmad Z. Diagnostic dilemma of abdominal tuberculosis in non-HIV patients: an ongoing challenge for physicians. World journal of gastroenterology: WJG. 2006 Oct 21;12(39):6371.
- Islam J, Clarke D, Thomson SR, Wilson D, Dawood H. A prospective audit of the use of diagnostic laparoscopy to establish the diagnosis of abdominal tuberculosis. Surgical endoscopy. 2014 Jun 1;28(6):1895-901.
- Al Muneef M, Memish Z, Al Mahmoud S, Al Sadoon S, Bannatyne R, Khan Y. Tuberculosis in the belly: a review of forty-six cases involving the gastrointestinal tract and peritoneum. Scandinavian journal of gastroenterology. 2001 Jan 1;36(5):528-32.
- Demir K, Okten A, Kaymakoglu S, Dincer D, Besisik F, Cevikbas U, Ozdil S, Bostas G, Mungan Z, Cakaloglu Y. Tuberculous peritonitis—reports of 26 cases, detailing diagnostic and therapeutic problems. European journal of gastroenterology & hepatology. 2001 May 1;13(5):581-5.
- Bhargava DK, Chopra P, Nijhawan S, Dasarathy S, Kushwaha AK. Peritoneal tuberculosis: laparoscopic patterns and its diagnostic accuracy. American Journal of Gastroenterology. 1992 Jan 1;87(1).
- Manohar A, Simjee AE, Haffjee AA, Pettengell KE. Symptoms and investigative findings in 145 patients with tuberculous peritonitis diagnosed by peritoneoscopy and biopsy over a five year period. Gut. 1990 Oct 1;31(10):1130-2.
- Volpi E, Calgareo M, Ferrero A, Viganò L. Genital and peritoneal tuberculosis: potential role of laparoscopy in diagnosis and management. The Journal of the American Association of Gynecologic Laparoscopists. 2004 May 1;11(2):269-72.
- Sharma MP, Bhatia V. Abdominal tuberculosis. Indian Journal of Medical Research. 2004 Oct 1;120:305-15.
- Bhargava DK, Chopra P, Nijhawan S, Dasarathy S, Kushwaha AK. Peritoneal tuberculosis: laparoscopic patterns and its diagnostic accuracy. American Journal of Gastroenterology. 1992 Jan 1;87(1).
- Nafeh MA, Medhat A, Abdul-Hameed AG, Ahmad YA, Rashwan NM, Strickland GT. Tuberculous peritonitis in Egypt: the value of laparoscopy in diagnosis. The American journal of tropical medicine and hygiene. 1992 Oct 1;47(4):470-7.
- Al-Mulhim AA. Laparoscopic diagnosis of peritoneal tuberculosis. Surgical endoscopy. 2004 Dec 1;18(12):1757-61.
- Sanai FM, Bzeizi KI. Systematic review: tuberculous peritonitis—presenting features, diagnostic strategies and treatment. Alimentary pharmacology & therapeutics. 2005 Oct;22(8):685-700.
- de Lope CR, Joglar GS, Romero FP. Laparoscopic diagnosis of tuberculous ascites. Endoscopy. 1982 Sep;14(05):178-9.
- Wolfe JH, Behn AR, Jackson BT. Tuberculous peritonitis and role of diagnostic laparoscopy. The Lancet. 1979 Apr 21;313(8121):852-3.