



A COMPARATIVE STUDY IN EVALUATION OF MIDDLE EAR DISEASES BY OTO-ENDOSCOPY AND OTO-MICROSCOPY

Otorhinolaryngology

Balaje R	Junior Resident, Dept of ENT, Sri Siddhartha Medical College, Tumkur, Karnataka.
Jyothi Swarup	Professor and HOD, Dept of ENT, Sri Siddhartha Medical College, Tumkur, Karnataka.
Swaroop Dev	Professor, Dept of ENT, Sri Siddhartha Medical College, Tumkur, Karnataka.
Sradha Asok	Junior Resident, Dept of ENT, Sri Siddhartha Medical College, Tumkur, Karnataka.
Moulya KM	Junior Resident, Dept of ENT, Sri Siddhartha Medical College, Tumkur, Karnataka.

ABSTRACT

Background: Middle ear diseases are the most common conditions in otology, proper evaluation of these patients are mandatory. Microscopic examination of ear is the routine procedure in evaluating the findings with certain limitations. Introduction of endoscopy had led to the attempts of utilizing it in otolaryngology for the evaluation of middle ear spaces. **Materials And Methods:** This is a Hospital based comparative study, patients attending outpatient department of ENT, Sri Siddhartha Medical College, of both genders between 18 to 60 years of age, diagnosed to have disease of middle ear have been enrolled for the study after obtaining the written informed consent. Study parameters of both the groups were compared. **Results:** Among 124 participants, our study showed that 29 participants (23.38 %) Eustachian tube opening is visible through the microscope, while it is visible in 111 participants (89.51%) under otoendoscopy. In 33 participants (26.61%) epitympanum is visible under microscopy, compared to otoendoscope were 95 participants (76.61%) are visible. Hypotympanum is visible in 58 participants (46.77%) with microscope and 112(90.3%) participants with otoendoscope. Visualization of sinus tympani in 9 participants (7.2%) is possible through microscope whereas it is visible in 91 participants (73.3%) through otoendoscope. Facial recess is visible in 8 participants (6.4%) through microscopy and in 89(71.7%) participants through otoendoscope. Oval window is visible in 12 participants (9.6%) through microscope whereas it is visible in 89 (71.7%) participants through Otoendoscopy. The p-value of all the above parameters is less than 0.001; indicating study is statistically significant thus otoendoscope has a better visualisation of these structures. No statistically significant difference between the examination of the external auditory canal and round window using a microscope and otoendoscope has been obtained. **Conclusion:** Oto-microscopy despite having the better three dimensional images, otoendoscope gives a better visualization of middle ear structure in evaluating diseases of middle ear. Therefore we conclude that Otoendoscopic examination should be mandatory along with routine Otomicroscopic examination.

KEYWORDS

Oto-microscopy, Oto-endoscopy, Eustation tube.

INTRODUCTION

Middle ear diseases are the most common conditions among all the otological diseases¹. Some of the diseases being life threatening while most of the diseases lead to hard of hearing hence proper evaluation of these patients are mandatory. Examination of ear under microscope is one of the routine procedures in evaluating the findings in middle ear diseases. Despite continuous technical improvements there are certain limitations which have stayed the same². Introduction of endoscopic surgeries had led to the attempts of utilizing endoscope in otolaryngology. Photographic role of examining the tympanic membrane and the external auditory canal with endoscopy has been widely published³. Very few studies have been documented in the use of endoscopy as a tool in routine diagnostic evaluation of middle ear diseases. There is a great need to understand the anatomical variation of the middle ear cavity and the normal middle ear structure status in every individual prior to any procedure. It can be well visualised using an endoscope, without any discomfort to the patient on outpatient basis⁵. The areas in the middle ear like ossicular chain, sinus tympanum, facial recess remains hidden in case of microscopic examination. These structures are assessed by the surgeon intraoperatively. These areas can be assessed better in case of Oto-endoscopic examination. With the help of 0° and 30° Oto-endoscope external auditory canal and tympanic membrane can be better visualised. The need for magnification in visualization of these structures and considering the smaller diameter of external auditory canal favours the use of otoendoscope in evaluation.⁴ For the evaluation of middle ear spaces, Otoendoscopy has a better advantage in visualization as well as it avoids the frequent tilting of the patient's head while examining.

AIM:

To compare the visualization of middle ear structures in evaluation of middle ear diseases by Otoendoscopy and Otomicroscopy.

OBJECTIVES:

1. To assess middle ear disease using operating microscope. 2. To assess middle ear disease using Oto-endoscope. 3. To compare the visualization of various middle ear structures.

MATERIALS AND METHODS

This is a Hospital based Comparative study. The patients attending the outpatient department of E.N.T, Sri Siddhartha Medical College hospital and Research Centre, Tumkur, Karnataka, of both the genders and aged between 18 to 60 years, diagnosed to have disease of middle ear were enrolled for the study after obtaining the written informed consent. Patients with congenital anomalies of external ear, acute inflammation of middle ear and complications of chronic otitis media were excluded from the study. Parameters Studied were: External Auditory Canal, Tympanic membrane, Promontory, Eustachian tube orifice (lateral end), Epitympanum, Hypotympanum, Oval window, Round window and Facial recess. Each study parameter is subdivided into three categories based on the visualization of the structure (visualised, partially visualised and not visualised). All patients with middle ear disease who meet the inclusion criteria were evaluated under Otomicroscopy and later Otoendoscopy was performed on the same patients, using 2.7mm and 4.0 mm endoscope of 30 and 45 degree rigid endoscope (18cm), depending on the size of perforation. A tri-chip camera, monitor and recording system were also used. Findings were noted.

RESULTS

Visualisation of External auditory canal

When external auditory canal examined, Otoendoscopy and microscopy revealed results that are almost identical.

The p-value for this study parameter is higher than 0.05, indicating that there is no statistically significant difference between the examination of the external auditory canal using a microscope and an otoendoscope.

Visualisation of Eustachian tube orifice

In our study, 29 participants (23.38 %) Eustachian tube opening is visible through the microscope, while it is visible in 111 participants (89.51%) under otoendoscope. 62 participants (50.0%) it is not visible through microscope, comparatively only in 6 participants (4.8%) through otoendoscope, with a statistically significant p value of <0.001.

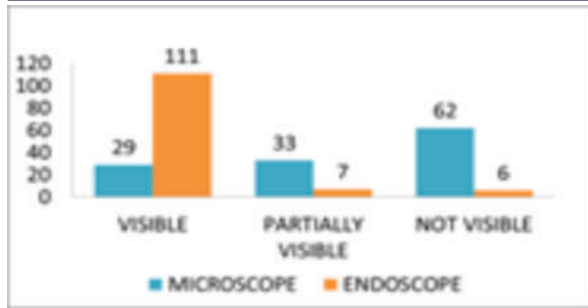


Chart-1, Comparison between Otoendoscopy and microscopy in visualization of Eustachian tube opening

Table -1, Comparison Between OTO Endoscopy And Microscopy In Visualisation Of E.A.C

EAC	Normal	Narrow	Tortious	p-value
Microscope	102	17	05	0.73
Otoendoscope	106	13	05	

Visualisation of Epitympanum

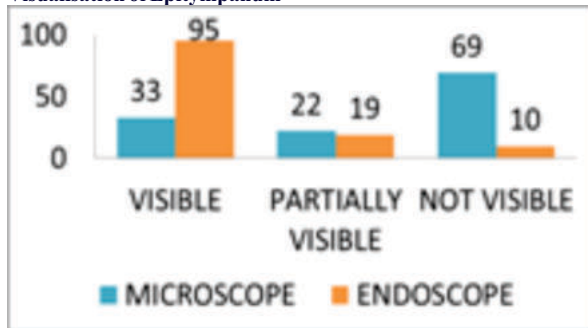


Chart-2, Comparison between Otoendoscopy and microscopy in visualization of epitympanum

In 33 participants (26.61%) epitympanum is visible under microscope, compared to otoendoscope were 95 participants (76.61%) are visible. It is not visible in 69 participants (55.64%) through microscope and 10 (8.06%) participants through otoendoscope, with a statistically significant p value of <0.001.

Visualisation Of Hypotympanum

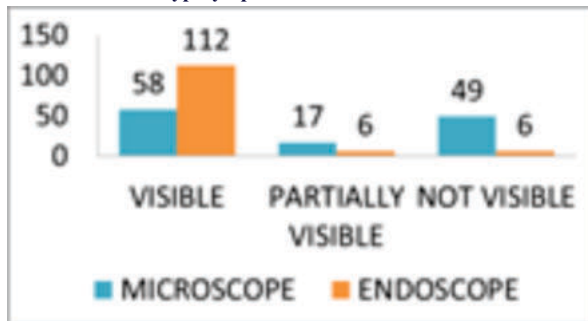


Chart-3, Comparison between Otoendoscopy and microscopy in visualization of hypotympanum

Hypotympanum is visible in 58 participants (46.77%) with microscope and 112 (90.3%) participants with otoendoscope. they are Not visible in 49 participants (39.5%) through microscope and in 6 participants (4.8%) through otoendoscope, with a statistically significant p value of <0.001.

Visualisation Of Sinus Tympanum

In visualizing sinus tympanum Otoendoscopy was better than microscope It is visible only in 9 participants (7.2%) through microscope whereas it is visible in 91 participants (73.3%) through otoendoscope, with a statistically significant p value of <0.001

Visualisation of Facial recess

Facial recess was better seen through Otoendoscopy than microscope.

Facial recess is visible in 8 participants (6.4%) through microscopy and in 89 (71.7%) participants through otoendoscope; it is not visible in 97 participants (78.2%) through microscopy and in 22 participants (17.7%) through Otoendoscopy, with a statistically significant p value of <0.001.

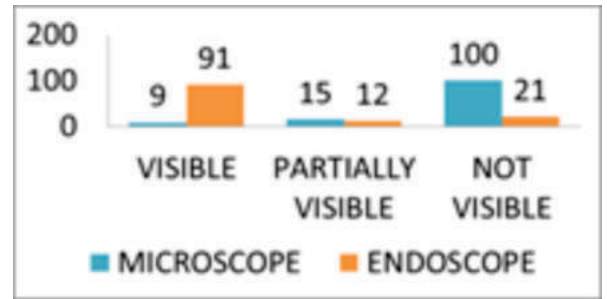


Chart-4, Comparison between Otoendoscopy and microscopy in visualization of sinus tympanum

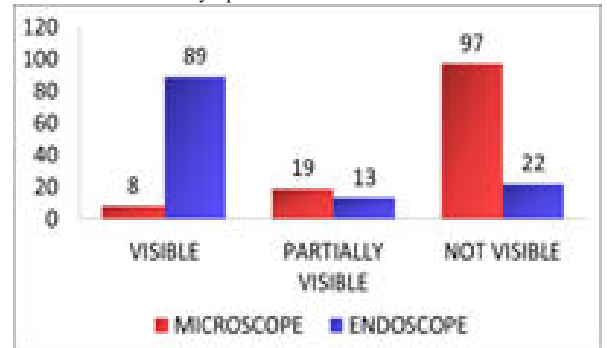


Chart-5, Comparison between Otoendoscopy and microscopy in visualization of Facial recess

Visualisation of Oval window

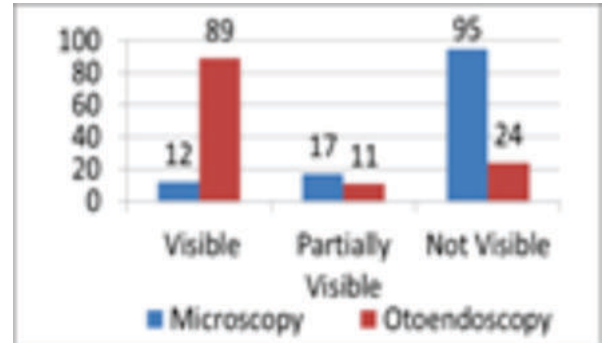


Chart-6, Comparison between Otoendoscopy and microscopy in visualization of oval window

In viewing oval window Otoendoscopy is superior to microscope. Oval window is visible in 12 participants (9.6%) and not visible in 95 (76.6%) participants through microscope whereas it is visible in 89 (71.7%) participants and not visible in 24 (19.3%) participants through Otoendoscopy, with a statistically significant p value of <0.001.

Visualisation of Round window

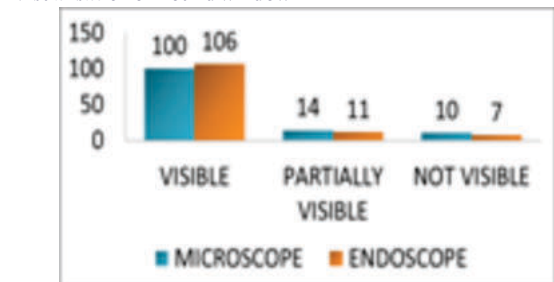


Chart-7, Comparison between Otoendoscopy and microscopy in visualization of round window

In 106 (85.5%) participants round window is visible through Otoendoscopy similarly, in 100 participants (80.6%) it is visible through microscopy. with p-value of 0.54.

DISCUSSION:

There is a great need to understand the anatomical variations of the middle ear cavity and the normal middle ear structure status in every individual prior to any Otological procedure. It can be well visualised using an Otoendoscope, without any discomfort to the patient on outpatient basis. Role of endoscopy in neurotologic procedure have been published by many investigators; however these studies are limited to cholesteatoma cases.^{8, 9} Very few studies have been documented in the use of endoscopy as a tool in routine diagnostic evaluation of middle ear diseases. In our study, Otoendoscopic and microscopic analysis of the external auditory canal and round window yielded nearly identical results. p-value for these study parameters was greater than 0.05, indicating that there is no statistically significant difference. However, the otoendoscope is effective than the microscope in distinguishing the anatomy of the Eustachian tube opening, epitympanum, and hypotympanum. Our study shows visibility of 29 participants (23.3%), 33 participants (26.6%) and 58 participants (46.77%) respectively using a microscope compared to otoendoscope were it is 111 participants (89.5%), 95 participants (76.6%) and 112(90.3%) participants. with p-value being <0.001. Thus, using an otoendoscope to evaluate these structures has statistically significant advantages. Similar results were seen in a comparative study conducted in the year 2016 by Marc L Bennett et al¹. It was found that using 0 degree scope provides significantly better visualization of every structure except antrum. In addition, angled scopes permit superior visualization as it covers more surface area of every sub unit of middle ear than straight scope or microscope.

In our study, sinus tympani can be seen using an otoendoscope in 91 participants (73.3%) and not seen in 22 participants (16.9%). whereas it is seen in 9 participants and not seen 100 participants (80.6%) when visualised under a microscope, with p-value < 0.001. Visualisation of facial recess was possible by the otoendoscope in 89 participants (70.6%) and not visible in 22 participants (17.7%) compared to 8 participants(6.45%) complete visualisation ,19 participants partial visualisation (15.32%) and not visualised in 97 participants (78.2%) by the microscope. Thus, the status of sinus tympani and facial recess could be seen in our study using 45° endoscope much better than a microscope. Similar results are seen in a prospective study conducted on 100 patients by Arjun Gopinatha Menon et al⁸, in the year 2016, were they found that middle ear structures were better evaluated with 30- and 70-degree endoscopes than with a microscope. A comparative study conducted on 180 patients in the year 2018, by Goel S,et al., found that 0 degree endoscopy was better than microscopy in visualization of round window niche even though statistically it was not significant. 30 and 70 degree endoscopes provided good visualization of all the middle ear structures. Therefore, endoscopes must be more frequently used in OPD setup. Similar results were shown by our study, where among 124 participants, we were able to visualize round window in 96 participants (77.4%) through microscope and 110 participants (88.7%) through otoendoscope. Mucosa at these sites and at adjacent structures is better assessed using Otoendoscopy.

CONCLUSION

Oto-microscopy despite having the better three dimensional images, otoendoscope gives a better visualization of eustachian tube opening, epitympanum, hypotympanum, sinus tympani, facial recess, oval window and round window in evaluating diseases of middle ear. Therefore we conclude that Otoendoscopic examination should be mandatory along with routine Otomicroscopic examination and also otoendoscopic examination will be better than otomicroscopy in post-operative evaluation and follow up of mastoid cavity after canal wall down.

Conflict of interest and Financial support – NIL

Ethical approval - The study was approved and ethical clearance taken from the Ethics committee, Sri Siddhartha Medical College, Tumkur, Karnataka.

REFERENCES

1. Kumari MS, Madhavi J, Meghanath KAR, Jyothy A. A Large Study on Otological Diseases from South India: A Decade Report. *J Ear Nose Throat Disord.* 2016 1(1): 1003.

2. Tarabichi M. Endoscopic middle ear surgery. *Annals of Otolaryngology Rhinology Laryngology.* 1999; 108:39-46
3. Hawke M. Telescopic otoscopy and photography of the tympanic membrane. *Journal of Otolaryngology.* 1982; 11:35-9.
4. Marc L. Bennett, Dongqing Zhang, et al. Comparison of Middle Ear Visualization with Endoscopy and Microscopy. *Otol Neurotol* 2016; 37:362-6.
5. Goel S, Sood A, Parmar SM. Middle Ear Evaluation in Chronic Suppurative Otitis Media: Otomicroscopy versus Otoendoscopy—A Comparative Study. *Int J Otorhinolaryngol Clin* 2018;10(3):87–90.
6. Sirajul Islam Mahfuzl, Kabir A2, AHM Zahurul Haq3 etall, Prevalence of Chronic Suppurative OtitisMedia in Out Patient Department in General Hospital, Gopalganj, Bangladesh. *Bangladesh J Otorhinolaryngol.* 2016; 22(2):102–9.
7. Menon AG, Kaushik M, Nevil V, Vinayakumar AR. A comparative study of middle ear evaluation by otomicroscopy and otoendoscopy in cases of chronic suppurative otitis media. *Archives of Clinical and Experimental Surgery.* 2016 Jul 1; 6(3):149-55.
8. M.Badr El Dine. Value of ear endoscopy in cholesteatoma surgery. *Otology and Neurotology.* 2002; 23:631-35
9. Jose Acuin. Chronic suppurative otitis media, Burden of Illness and Management Options. World Health Organization, Geneva, Switzerland. 2004.