



COMPUTED TOMOGRAPHY EVALUATION OF CRANIOVERTEBRAL JUNCTION IN ASYMPTOMATIC RURAL POPULATION OF ANDHRA PRADESH

Radiodiagnosis

Dr. S. Vamshikiran*	Final year Postgraduate Student, Department of Radiodiagnosis, Santhiram Medical College and General Hospital, Nandyal,*Corresponding Author
Dr. B.E.panil Kumar	MDRD, Professor and HOD, Department of Radiodiagnosis, Santhiram Medical College and General Hospital, Nandyal.
Dr. K. Janardhan Reddy	DNB, RD, Professor, Department of Radiodiagnosis, Santhiram Medical College and General Hospital, Nandyal.

KEYWORDS

INTRODUCTION

The craniovertebral junction (CVJ) is the anatomical junction between the cranium and the spine. It is a separate structure functionally from both the cranium and the cervical spine¹. It comprises of the occiput, atlas, axis, and their articulations. It encloses the vital soft tissue structures of the cervicomedullary junction (medulla, spinal cord and cervicomedullary junction)²

CVJ is the transition point between the brain and cervical spine. Most of the spine movements occur between the occiput, the atlas, and axis. The movements at the Craniovertebral junction are studied with craniovertebral junction segments. The complex CVJ anatomy and biomechanics has helped in understanding of the pathological processes that affects this region. Advancements in surgical techniques of the Craniovertebral junction has promoted further characterization of its anatomy³.

X-ray assessment of Craniovertebral junction is inaccurate due to the superimposition of the bony structures⁴. Modern diagnostic techniques like computed tomography and Magnetic Resonance imaging can play a tremendous role in accurate morphometry.

CT evaluation would help us in understanding the joint dynamics⁵. It acquires 3-dimensional cross-sectional image of the patient without superimposition of the structures as in X-ray. There is also the added advantage of improved spatial resolution with computed tomography.

Most of the studies of Craniovertebral junction so far were performed in patients with congenital malformations⁶. And, most of the normative data published are based on studies conducted by Western authors. Because, Craniovertebral junction morphometry has racial and ethnic variations, there is a need to study normative data of Indian population. This study aimed at computed tomography assessment of the normal craniovertebral junction to standardise morphometry in rural population of Andhra Pradesh.

REVIEW OF LITERATURE

The measurements mentioned below are the most used measurements of the craniovertebral junction:

McRae's Line:

It is the line from the anterior border (basion) to the posterior border (opisthion) of foramen magnum. It indicates the presence of basilar invagination if the tip of the odontoid process crosses this line. Tip of dens should normally be 5 mm below this line as measured on skull lateral X-ray⁷.

Chamberlain's line:

Chamberlain line is between the posterior border of hard palate and the opisthion. Basilar invagination is diagnosed if the tip of the odontoid process is >3 mm above this line².

McGregor's line:

The McGregor line connects posterior border of the hard palate to the caudal point on the occipital curve. Basilar invagination is diagnosed if the tip of the dens lies more than 4.5 mm cranial to this line. It is a

modification of the chamberlain's line and used when opisthion is not visualised on plain radiographs⁸

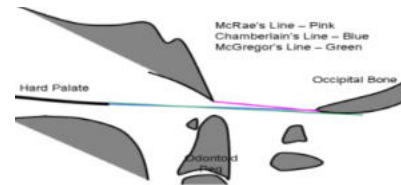


Figure 1: Illustrates the various bony landmarks and the lines of the linear craniometry of craniovertebral junction⁷

The basion-dens interval (BDI) is the distance between the basion and the tip of the dens. Harris et al calculated that 95% of adults in their study population had a BDI less than 12 mm and considered this value as the upper limit of normal.

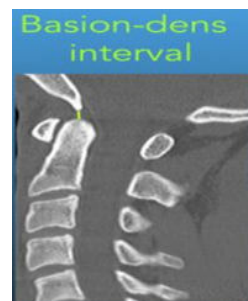

Figure 2: Basion-dens interval

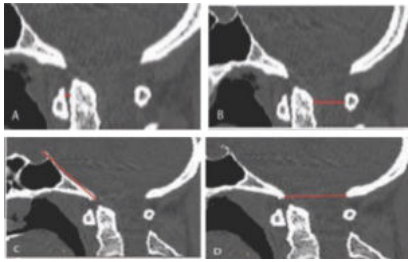
Anterior atlanto-dental interval (AADI): Horizontal distance from the posterior margin of anterior atlas arch and anterior margin of odontoid process of axis, in midline sagittal cuts of CT scan. Anterior atlantodental interval (AADI) described by Hinck et al, is conventionally held to be normal when it is less than 3 mm in men and 2.5 mm in women

Posterior atlantodental interval (PADI): Horizontal distance from the anterior margin of posterior atlas arch to the posterior margin of odontoid process of axis in midline sagittal section.

The clivus length (CL): It is measured as the distance between the top of the dorsum Sella to the basion in midline sagittal image. The significance of clivus length lies in the fact that it distinguishes adult female healthy individuals with benign tonsillar ectopia from those with symptomatic Chiari malformation.

AP diameter of Foramen magnum (FMD): Distance between the anterior margin and posterior margin of foramen magnum in a midline sagittal section of CT image.

Figure 3: CT measurements of the following parameters (A) AADI (B) PADI (C) AP diameter of foramen magnum (D) Clivus length



Boogaard's angle is measured by drawing a line from basion to opisthion and another line along the plane of the clivus to the basion intersecting the first line the angle between these two lines is measured⁹

Basal angle: Angle formed by intersection of the line joining the nasion with the center of sellar floor and the line joining the anterior margin of the foramen magnum with the center of floor of sella¹⁰

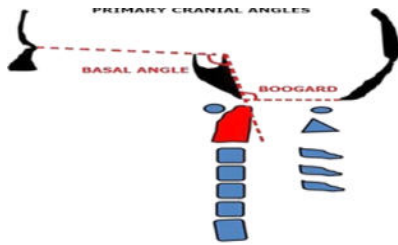


Figure 4: The image demonstrates the angular craniometry of the craniovertebral junction¹¹

Powers ratio: It is the ratio between the lines connecting Basion to anterior surface of posterior arch of Atlas and the line connecting the Opisthion to the posterior surface of anterior arch of Atlas. It is a measurement of the relationship of the foramen magnum to the atlas, used in the diagnosis of atlanto-occipital dissociation injuries.

The ratio, AB/CD, is measured as the ratio of the distance in the median (midsagittal) plane between the:

1. Basion (A) and the posterior spinolaminar line of the atlas (B) and,
2. Opisthion (C) and posterior surface of the anterior arch of the atlas (D)

It is considered normal when the value is less than 1. If this ratio is >1, then the anterior atlanto-occipital dissociation should be suspected.

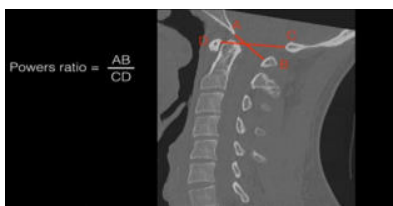

Figure 5: The image demonstrates the normal powers ratio measurement¹²

AIMS AND OBJECTIVES

1) CT evaluation of normative data of the Cranio-Vertebral Junction anatomy among the asymptomatic rural population of Andhra Pradesh.

MATERIALS AND METHODS

TYPE OF STUDY: It is a Cross sectional study

SOURCE OF DATA: Department of Radiodiagnosis at Santhiram medical college and general hospital, Nandyal, Andhra Pradesh.

PERIOD OF STUDY: October 2022 to December 2022

SAMPLE SIZE: Approximate sample size is 60

SAMPLING CRITERIA

INCLUSION CRITERIA:

1. All the head injury patients who were advised CT brain and cervical spine but reported normal CT cervical spine.
2. Patients who came to our department for CT-brain or CT-PNS for

various reasons were further advised imaging for CVJ evaluation.
3. Patients who had given informed and written consent.

EXCLUSION CRITERIA:

1. Patients with cervical spine injury.
2. Patients who had prior history of autoimmune disease, neurological deficit, and any cervical spine pathology on CT cervical spine
3. Patients who had not given written and informed consent

EQUIPMENT

SIEMENS 32 slice SOMATOM SCOPE CT VC 40, H-SP spiral CT machine, at Santhiram Medical college and General Hospital

RESULTS

This study consisted of 60 cases, which included 39 male and 21 female patients. The age group ranged from 3 years to 90 years. The mean age of the study population was found to be 42.9 years. About 40% (24 patients) of the population belonged to age group <30 years, 46.6 % (28 patients) belonged to the age group of 31- 60 years, while only 13.3% were in the age group of 61-90 years. Most of the study population were males (39 patients- 65%).

Table 1 shows normal age wise distribution of cases in the study

Age group (In years)	Number	Percentage (%)
<30 years	24	40%
31-60 years	28	46.6%
61-90 years	8	13.3%
Total	60	100%

Table 2 shows the mean and standard deviation of various parameters in the study

	Mean	SD
Tip of the odontoid from McRae's line	6.88mm	1.39mm
Tip of odontoid from Chamberlain's line	2.3mm	1.2mm
Tip of the odontoid from McGregor line	5.09mm	2.59mm
Basion dens interval	7.56	1.6
AADI	1.42mm	0.43mm
PADI	16.77mm	2.08mm
CL	42.81mm	3.68mm
FMD	35.03mm	3.10mm
BA	130.24°	4.4°
BOO	126.44°	5.21°
Power ratio	0.73	0.053

Table 3 shows comparison of data between male and female.

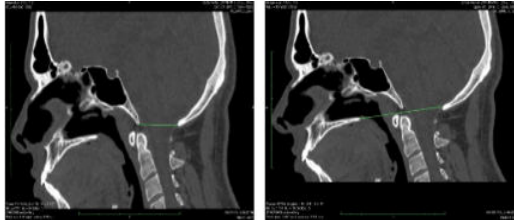	Male-Mean	Female-Mean
Tip of the odontoid from McRae's line	7.033mm	6.458mm
Tip of odontoid from Chamberlain's line	2.33mm	2.25mm
Tip of the odontoid from McGregor line	5.309mm	4.5mm
Basion dens interval	7.82	6.98
AADI	1.47mm	1.35mm
PADI	17.03mm	16.2mm
CL	43.41mm	41.68mm
FMD	35.48mm	34.88mm
BA	130.32°	130.13°
BOO	126.76°	126.10°
Power ratio	0.745	0.734

Table 4 shows comparison of observed data with global standards

	Mean	Global available standards
Tip of the odontoid from McRae's line	6.88mm	Above 5mm
Tip of odontoid from Chamberlain's line	2.3mm	0-3 mm
Tip of the odontoid from McGregor line	5.09mm	0-4.5 mm

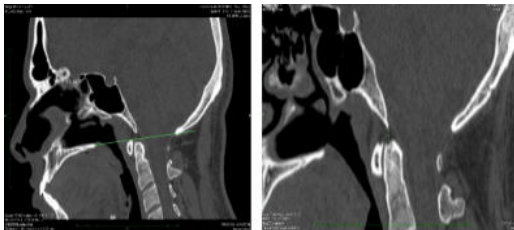Basion dens interval	7.56	<12mm
AAADI	1.42mm	<3mm for males, <2.5mm for females
PADI	16.77mm	13-23.7 mm
CL	42.81mm	43.05 +/-3.33 mm
FMD	35.03mm	36.29+/-2.35mm
BA	130.24°	125-143°
BOO	126.44°	126+/-6°
Power ratio	0.73	0.77

REPRESENTATIVE CASES



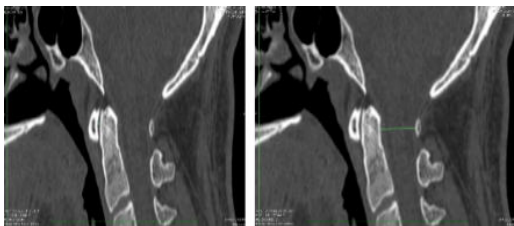McRae's Line

Chamberlain's line

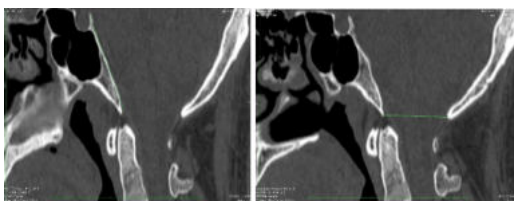

McGregor's line

Basion-dens interval (BDI)

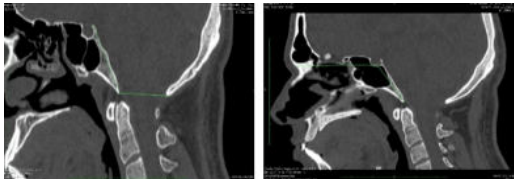


Anterior atlanto-dental interval Posterior atlanto-dental interval



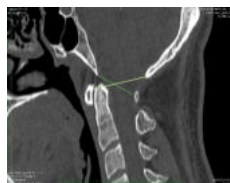Clivus length

AP diameter of Foramen magnum



Boogaard's angle

Basal angle



Powers ratio

DISCUSSION

This study was conducted on 60 patients who came to santhiram general hospital, nandyal. Study conducted using multidetector computed tomography for evaluation of the normative data of

craniocervical junction among rural population of Andhra Pradesh. The intention was to find the average of the various parameters of the craniocervical junction and thereby standardise the values for asymptomatic population of rural population of Andhra Pradesh. This study also attempted to see how different these values are from the globally accepted standards.

The mean age of the study population was found to be 40.42 years. The age group ranged from 3 years to 90 years. About 40% (24 patients) of the population belonged to age group <30 years, 46.6 % (28 patients) belonged to the age group of 31- 60 years, while only 13.3% were in the age group of 61-90 years. Most of the study population were males (39 patients- 65%).

The most important of these measurements were the tip of odontoid from the McRae's line. The odontoid tip crossed the line in none of these patients. The mean value of the McRae's line measurement was found to be 6.88 mm. There is a mild difference in this value from the study done by Dash Et al on craniometry in asymptomatic individuals in Indian population⁶³. The mean value for the same in their study was 5.11 mm. So, the tip of the odontoid can be normally at up to 6.88 +/- 1.39 mm caudal to the McRae's line. Another study done by Marathe Et al in Indian population showed that McRae's line value can be up to 6.2 mm¹³.

The accepted radiographic cut off for McGregor line is 4.5 mm. It means that the tip of the odontoid can project up to 4.5 mm above the McGregor's line¹⁴. The mean value of McGregor line in this study was 5.09 mm which is in accordance with this study. However, in a review published by Maheshwari et al on "imaging of normal and abnormal craniocervical junction", the normal values ranged up to 8 mm in males and 10 mm in females¹⁵. None of the cases in this study showed a dens tip crossing the McRae's line and by extension the foramen magnum, the possibility of basilar invagination was excluded. So, the tip of odontoid can be normally up to 5.09 mm cranial to the level of the McGregor's line.

Study done in Istanbul by Neil et al, where the mean chamberlain's line distance was 2.5mm¹⁶. The mean value for chamberlain's line in this study was 2.3mm. So, the tip of the odontoid can be normally up to 2.3 mm cranial to the level of the chamberlain's line as per this study.

The three lines are important in the diagnosis of basilar invagination. These three lines showed a slightly higher value for males than females. However, there was no statistically significant difference between the values and gender. There was also no significant difference in these values and age groups by statistical analysis.

The average values of basal angle and Boogaard's angle are 130.24°, and 126.44° respectively. There was no significant statistical association with age and gender for any of these values. In a CT based study by Dash et al, the basal angle value averaged to about 121.65°. The value is comparable with this study¹⁷. In an MRI based study done on south Indian population by Raveendranath et al, the mean values are 113° and 114° for basal angle, 120° and 121° for Boogaard's angle, in males and females respectively¹⁸. Like this study, there was no statistical significance between genders. The values for Boogaard's angle were like this study. However, there was a 7° variation in basal angles between both studies. This could be attributed to use of modified MRI technique for basal angle measurement.

The values of powers ratio averaged to 0.73. Powers ratio is an indicator of atlantooccipital dissociation injuries. Normal values are taken as less than 1 on plain radiographs with a range of 0.77 to 1¹⁹. This study showed no significant variation from the normal criteria as was found in a study done by Rojas et al²⁰.

The mean value of anterior atlanto-dental interval (AAADI) was found to be 1.42 mm +/- 0.43mm. There was no significant association with age or gender. The mean anterior atlanto-dental interval was found to be 1.4+/- 0.5 mm in a study conducted by Demirel Et al¹⁶. In the study conducted by Dash et al, the mean value of the same was found to be 1.12 +/- 0.66 mm¹⁷. The values are comparable in both studies.

Value of posterior atlanto-dental interval (PADI) ranged from 12.10 mm to 26.20 mm with mean PADI of 16.77 mm and standard deviation (SD) of 2.08. Difference between male and female values of PADI was found to be statistically nil-significant.

The Antero posterior diameter of the foramen magnum measured an average of 35.03 +/- 3.04mm. The values are corresponding with the study done by Dash et al, wherein the value was 36.29 +/-2.35mm. There was no significant correlation with age and gender.

The mean clivus length measurement was 42.81 +/- 3.68 mm. There was no significant association with age and gender. The mean clivus length was found to be 44.74 mm in a study done by Batista et al²¹. These values are comparable with this study values.

CONCLUSION

This study was conducted on 60 patients who came to santhiram general hospital, nandyal. Study conducted using multidetector computed tomography for evaluation of the normative data of craniocervical junction among rural population of Andhra Pradesh. The various parameters of the craniocervical junction were developed using radiography previously. The radiographic measurements were always suspected to have inherent flaws due to the poor spatial and contrast resolution as compared to computed tomography. The intention of this study was to find the average of the various parameters of the craniocervical junction and thereby standardise the values for asymptomatic population of rural population of Andhra Pradesh. This study also attempted to see how different these values are from the globally accepted standards.

The relevance of the normative anatomical parameters in the current scenario and their variations from the current accepted global standards were the main objectives of this study. Attempt was made to analyse if there is any correlation between the various parameters.

All the parameters measured showed minimal or no variations from the accepted global standards. All parameters mean values are slightly more in males than in females. But none of the parameters showed significant association with age.

REFERENCES

- Offiah CE, Day E. The craniocervical junction: embryology, anatomy, biomechanics and imaging in blunt trauma. *Insights Imaging*. 2017 Feb;8(1):29–47.
- Smoker WR. Craniocervical junction: normal anatomy, craniometry, and congenital anomalies. *Radiographics*. 1994 Mar;14(2):255–77.
- Lopez AJ, Scheer JK, Leibl KE, Smith ZA, Dlouhy BJ, Dahdaleh NS. Anatomy and biomechanics of the craniocervical junction. *Neurosurgical Focus*. 2015 Apr 1;38(4):E2.
- Essentials of Skeletal Radiology (2 Volume Set), 3rd Edition by Terry R. Yochum | 9780781739467 | Booktopia [Internet]. [cited 2021 Nov 4]. Available from: <https://www.booktopia.com.au/essentials-of-skeletal-radiology-2-volume-set-terry-r-yochum/book/9780781739467.html>
- Abuzayed B. Computed Tomography Evaluation of Craniocervical Junction. *J Neurosci Rural Pract*. 2020 Jul;11(3):363–4.
- Dhadve RU, Garge SS, Vyas PD, Thakker NR, Shah SH, Jaggi ST, et al. Multidetector Computed Tomography and Magnetic Resonance Imaging Evaluation of Craniocervical Junction Abnormalities. *N Am J Med Sci*. 2015 Aug;7(8):362–7.
- Cronin CG, Lohan DG, Mhuirheartigh JN, Meehan CP, Murphy J, Roche C. CT evaluation of Chamberlain's, McGregor's, and McRae's skull-base lines. *Clin Radiol*. 2009 Jan;64(1):64–9.
- Keats TE, Siström C. *Atlas of Radiologic Measurement*. Mosby; 2001. 738 p.
- Berry M. *Diagnostic Radiology : Neuroradiology : Head and Neck Imaging*. Jaypee Brothers medical Publishers; 2006. 705 p.
- Frade HC, França CCNL, Nascimento JJC do, Holanda MM de A, Silva Neto EJ da, Araújo Neto SA. Craniocervical transition assessment by magnetic resonance imaging in a sample of a northeast Brazilian population. *Arq Neuro-Psiquiatr*. 2017 Jul;75(7):419–23.
- Botelho RV, Ferreira EDZ. Angular craniometry in craniocervical junction malformation. *Neurosurg Rev*. 2013;36(4):603–10.
- POWERS RATIO [Internet]. [cited 2021 Nov 12]. Available from: <http://www.scientificspine.com/spine-imaging/powers-ratio.html>
- Marathe NA, Dahapute AA, Desai JR, Dhole KP, Bhaladhare S, Shah S. X-ray and Computed Tomography Scan-Based Morphometric Analysis of Skull Baselines in Indian Population. *Asian J Neurosurg*. 2019 Nov 25;14(4):1116–21.
- Goel A. Basilar invagination, Chiari malformation, syringomyelia: A review. *Neurology India*. 2009 May 1;57(3):235.
- Maheshwari S, Bhat V, Bn KK. Imaging of Normal and Abnormal Craniocervical Junction - A Pictorial Review. 2021;5(1):10.
- Demi R, el N, Gül A, Gergi N, S, Düzkalir HG, Başaran R, Düzkalir AH, et al. CRANIOVERTEBRAL JUNCTION MORPHOMETRIC EVALUATION WITH RECONSTRUCTIVE COMPUTED TOMOGRAPHY. :6.
- Dash C, Singla R, Agarwal M, Kumar A, Kumar H, Mishra S, et al. Craniocervical junction evaluation by computed tomography in asymptomatic individuals in the Indian population. *Neurology India*. 2018 Jan 5;66(3):797.
- Raveendranath V, Dash PK, Nagarajan K, Kavitha T, Swathi S. Skull Base Angle Morphometry in South Indian Population with Review on Terminology. *Indian Journal of Neurosurgery*. 2021 May 13;s-0041-1722824.
- Powers B, Miller MD, Kramer RS, Martinez S, Gehweiler JA. Traumatic Anterior Atlanto-occipital Dislocation. *Neurosurgery*. 1979 Jan 1;4(1):12–7.
- Rojas CA, Bertozzi JC, Martinez CR, Whitlow J. Reassessment of the Craniocervical Junction: Normal Values on CT. *American Journal of Neuroradiology*. 2007 Oct 1;28(9):1819–23.
- Batista UC, Joaquim AF, Fernandes YB, Mathias RN, Ghizoni E, Tedeschi H. Computed tomography evaluation of the normal craniocervical junction craniometry in 100 asymptomatic patients. *Neurosurg Focus*. 2015 Apr;38(4):E5.