



A RARE CASE REPORT OF RETAINED METALLIC INTRAOCULAR FOREIGN BODY IN ANTERIOR CHAMBER PRESENTING AS HYPOPYON WITH CORNEAL ULCER

Ophthalmology

Dr. Namrata Patel	MS Ophthalmology, Assistant Professor, Department of Ophthalmology, GSVM Medical College, Kanpur, UP, India
Dr Ritu*	MBBS, Junior Resident, Department of Ophthalmology, GSVM Medical College, Kanpur, UP, India *Corresponding Author
Dr Shalini Mohan	MS Ophthalmology, DNB, MNAMS, Professor & Head of Department of Ophthalmology, GSVM Medical College, Kanpur, UP, India
Dr. Suraj Mishra	MS Ophthalmology, senior Resident, Department of Ophthalmology, GSVM Medical College, Kanpur, UP, India

ABSTRACT

Retained Intraocular Foreign Body (IOFB) following Penetrating Ocular Trauma is a vision-threatening condition but timely investigations, Diagnosis and management can save Vision and reduce complications. Patients of Ocular Trauma with no clear cut history of Penetrating injury and Cases which are Non-responding to appropriate treatment following Ocular Trauma should be considered for Surgical Exploration.

KEYWORDS

INTRODUCTION

Ocular trauma, especially penetrating type, is potentially a vision-threatening injury. The extent of penetration depends on factors that include size and composition of the Foreign Body, force of entry into the eye, location of the resulting wound, and the final location of the foreign body in the eye.

Other important factors that might influence the final prognosis include initial visual acuity, presence of an afferent pupillary defect, perforation of the globe, and Endophthalmitis. So it is extremely important to diagnose early and remove foreign body for better visual outcome. In some cases, the intraocular foreign body (IOFB) itself may not be easily detected, even on slit lamp examination. Then we must proceed towards other investigations, and should consider for surgical Exploration.

Case Report

A 6-year old male child, presented to us with chief complaints of Right eye pain, swelling, redness and Photophobia. On taking history, patients' attendant told that the child was apparently asymptomatic one week ago when he developed sudden pain, Diminution of vision and redness following Ocular trauma while playing. On initial examination, the patient's visual acuity was 6/12 OD and 6/6 OS.

The intraocular pressure was digitally normal. On slit-lamp examination, there was Right eye edematous lids with presence of circumcorneal congestion with 3×1mm sized elongated, dry looking, oval lesion, located at junction of upper and lower outer quadrant of cornea with stromal infiltrations.

It did not involve pupillary area. It was stain positive with Fluorescence dye. It was Negative for Seidel's test and Seidel's Pressure test. There was also Hypopyon of 4mm which was thick dense, immobile in nature. The Iris pattern was normal. Pupillary reaction was sluggish in Right eye.

The lens was clear. On Distant direct ophthalmoscopy, Fundal Glow was present. Right eye USG-B scan was Normal. The corneal scraping was sent for KOH mount & culture which showed positive result for Fungal hyphae. So, the probable diagnosis of Post Traumatic Fungal corneal ulcer with Hypopyon was made & Antifungal treatment was started with eyedrop Natamet, Eyedrop Moxifloxacin, eye drop Homide, and eye drop CMC.

After 1 week of appropriate treatment, we noticed that other signs were reduced, but Hypopyon got organised in an oval shape. It was not decreasing despite treatment with the Antifungal drugs.

As the defined lesion was not responding to the appropriate treatment, it led us to plan Anterior Chamber (AC) wash under GA.

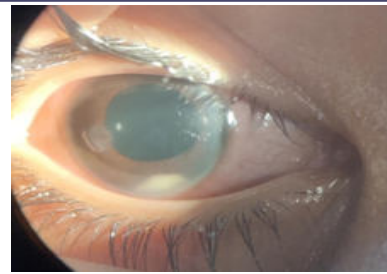


Figure 1 : Pre-OP image showing Non-Resolving Organised Hypopyon

While doing AC wash, as the exudates were removed, a Dark Brown coloured solid foreign body was noticed in the inferior part of AC. It was covered with exudates and so was hidden and undiagnosed. It was grasped & removed with the help of Lim's Forceps successfully & Intracameral Antifungal Given.

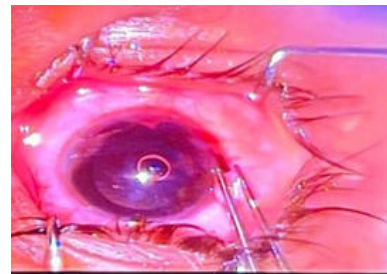


Figure 2 : Intra-OP image of foreign body removal

On close assessment of this foreign body we found that, it was a small 2mm rusted iron wire particle.

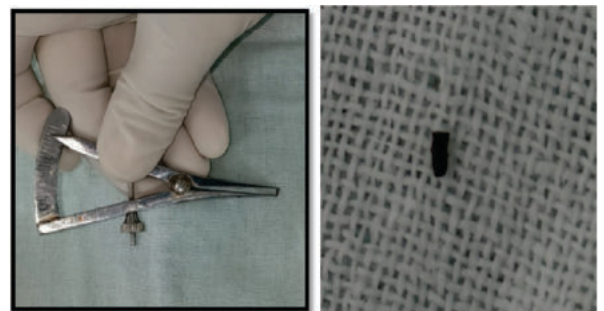


Figure 3 : Showing 2mm iron particle after removal

Patient got relieved of Pain on immediate Next Post-OP day. Other signs also resolved slowly over a period of 2 weeks. 1month Post-Op ,the Final visual acuity of the child, both uncorrected and Best Corrected, returned to 6/6 P in R/E.

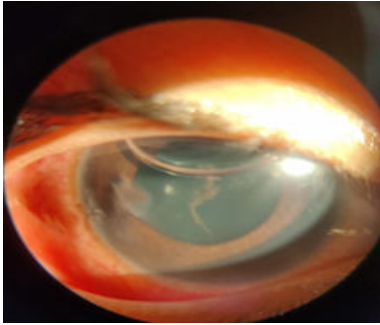


Figure 4 : Immediate Next post-OP day image

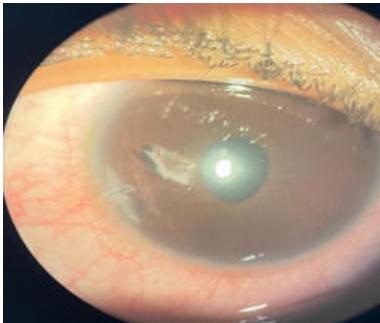

Figure 5 : 15 days post-OP after removal of foreign body

DISCUSSION

A few cases of retained intraocular foreign bodies presenting in the anterior chamber angle have been reported. Our patient had a metallic foreign body entering through the cornea and resting in the inferior chamber angle, covered with exudates, making it difficult to diagnose on slit lamp examination. Therefore, after taking a thorough history of any ocular trauma, foreign body must be ruled out even when not observed on the initial examination. Gonioscopy is recommended only if there is no risk of extrusion of intraocular content¹¹. In Our case, we did not do Gonioscopy as there was infection and child was also non-cooperative. Thereafter, a proper imaging like X-ray, ultrasound biomicroscopy (UBM), Anterior segment OCT (AS-OCT) should be performed in order to confirm the diagnosis and rule out foreign body. While Magnetic Resonance Imaging (MRI) is contraindicated when dealing with a metallic foreign body, CT scan is considered the gold standard. UBM and AS-OCT may further add to the diagnosis by estimating more accurately the foreign body size and location^{12,31}. As in our case, there was no clear cut history suggestive of Penetrating trauma, so we did not advice for X-ray. Further UBM, is a contact modality, so can't be done in an infected case. And as child was non-cooperative, ASOCT couldn't be done.

CONCLUSION

Exploration of such cases, where there is no respond to appropriate treatment, may yield good result even if Foreign Body is not present, we can clear the anterior chamber and also inject Intracameral Antifungal.

REFERENCES

- (1) R. S. Davidson and A. Sivalingam, "A metallic foreign body presenting in the anterior chamber angle," *CLAO Journal*, vol.28, no. 1, pp. 9-11, 2002.
- (2) G. Mete, Y. Turgut, A. Osman, U. Gulsen, and A. Hakan, "Anterior segment intraocular foreign body causing chronic Hypopyon uveitis," *Journal of Ophthalmic Inflammation and Infection*, vol. 1, pp. 85-87, 2011.
- (3) A. E. Sargsyan, A. G. Dulchavsky, J. Adams, S. Melton, D.R. Hamilton, and S. A. Dulchavsky, "Ultrasound detection of Simulated intra-ocular foreign bodies by minimally trained Personnel," *Aviation Space and Environmental Medicine*, vol. 79, No. 1, pp. 58-61, 2008.