



## BELL'S PALSY IN PREGNANCY AND PUERPERIUM: A CASE REPORT

## Obstetrics &amp; Gynaecology

**Dr. Maithily Vaidya\***

Junior resident, Department of Obstetrics and Gynaecology, GMC Miraj, Maharashtra  
\*Corresponding Author

**Dr. Rohini Bambare**

Junior resident, Department of Obstetrics and Gynaecology, GMC Miraj, Maharashtra

**Dr. Jyoti Rokade**

Associate Professor, Department of Obstetrics and Gynaecology, GMC Miraj, Maharashtra

## ABSTRACT

Bell's Palsy is an idiopathic facial nerve palsy and also the most common cause of facial nerve palsy. Its incidence is 17/100,000 population per year in women of child bearing age group(WCBA). We, hereby present a case of 26 year old gravida 2, para 1, living 1 with 35 weeks of gestation who presented with gradual onset of facial weakness and few other complaints which after thorough examination were suggestive of Bell's palsy in a case of pre eclampsia. Patient was later posted for C-section at 36 weeks for scar tenderness. In the post operative period patient was on steroids for persistent facial nerve palsy but the patient landed in an unusual complication due to on going steroids as she had failed to follow up. Patient was taken up for exploratory laparotomy, patient tolerated the procedure well and went home on POD-42. Amongst the medications used in this patient for Bell's palsy, we saw that steroids could thus act as a double edged sword and thus close monitoring, follow up and patient compliance is equally important.

## KEYWORDS

Bell's palsy, pregnancy and bell's palsy, pre eclampsia, steroids, facial nerve palsy

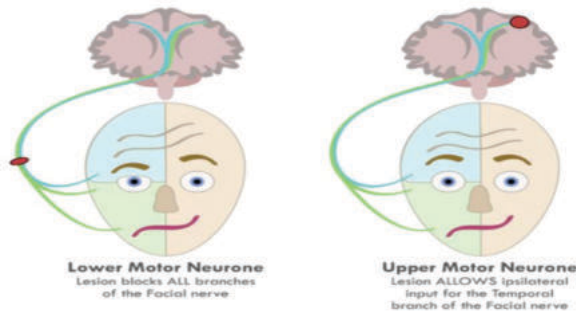
## INTRODUCTION

Sir Charle's Bell first described the term Bell's palsy which is idiopathic facial nerve palsy and most common cause of facial palsy and also described its association with pregnancy<sup>[1]</sup>. Bell's palsy is the most common cause of facial palsy. It has female predominance and rates in pregnancy may be increased<sup>[2-3]</sup>. The incidence of Bell's palsy is 17/100,000 population per year in women of child bearing age group(WCBA). The pregnant population is affected about 2 to 4 times more than the non pregnant population with an incidence of 38-45/100,000 deliveries<sup>[4]</sup>. The precipitating factors are blood clotting disorders, high blood pressure, eclampsia or pre-eclampsia, increased extracellular fluid, changes in levels of estrogen and progesterone, impaired glucose tolerance, increased cortisol levels and during third trimester of pregnancy or in first week of delivery after child birth due to risk of reactivation of HSV infection.

The patient then reported to emergency room at 36 weeks of gestation with scar tenderness. On examination her pulse was 110/min, blood pressure was 130/90mmhg, urine albumin 1+. She was presently having Bell's palsy. She was immediately posted for emergency cesarean section in view of scar tenderness. Intra operative and post operative period was uneventful except for persistence of facial weakness for which steroids(deflazacort 6mg twice daily), multivitamins and physiotherapy were started. Steroids were tapered and patient was asked to regularly follow up every 7 days after being discharged. Patient was asked to monitor her blood glucose levels in view of ongoing steroids. But the patient had poor compliance and failed to follow up and landed up in an unusual complication due to ongoing steroids. The patient came to emergency room on POD-32 with high grade fever, loose stools and peritonitis like picture on CT scan. Patient was started on higher antibiotics (Piperacillin, Tazobactam) and taken up for exploratory laparotomy. It was found that patient had multiple pus pockets. All the pockets were identified, the abdominal organs examined and thorough wash with normal saline and metronidazole was given. Patient tolerated the procedure well. Patient went home on POD-42.

## DISCUSSION

The incidence of Bell's palsy is 17/100,000 population per year in women of reproductive age group. Whereas in pregnancy it is 38-45/100,000 pregnant females<sup>[4]</sup>. Clinical presentation of Bell's palsy in pregnancy is the same as in non pregnant state. The typical findings are less prominent wrinkles on affected side, eyebrow drop, flattened nasolabial fold, corner of mouth turned down, inability to wrinkle forehead, raise eyebrows, purse lips, show teeth or whistle. Thorough history and examination are important to rule out the different causes of facial palsy. Pregnancy is maximally immunocompromised in last trimester due to high titres of cortisol. There can be activation of herpes virus which lives in geniculate nucleus of facial nerve leading to inflammatory reaction resulting in demyelination of nerve. Increase in interstitial fluid or extracellular fluid leads to compression neuropathy. Pregnancy is hypercoagulable state and thrombosis of vasa nervosa supplying facial nerve can cause devascularization and ischaemic nerve injury. Bell's palsy during pregnancy has been associated with pre eclampsia<sup>[5]</sup>. Pre eclampsia often manifests with edema. Many patients can have considerable edema and thrombophilia leading to hypercoagulable state. Other than a five fold greater rate for gestational hypertension or pre eclampsia, women with Bell's palsy do not have increased adverse pregnancy outcomes rates<sup>[6]</sup>. Treatment of Bell's palsy includes topical eye care, corticosteroids, antivirals and/or surgery. Use of steroids has been found to improve recovery<sup>[7]</sup>. Consensus supports that prednisone, 1mg/kg given orally daily for 5 days, will improve outcomes and shorten the recovery period. It is



## Case Report

A 26 year old gravida 2, para 1, living 1 with 35 weeks of gestation with previous 1 cesarean section four years back (indication-fetal distress) presented to antenatal outpatient department with complaints of gradual onset of facial weakness over left side of face, altered taste sensation, drooling of saliva from left angle of mouth since 4-5 days. On examination patient was conscious, afebrile, her pulse was 90/min, blood pressure was 130/90 mmhg, respiratory rate 18/min. Respiratory system and cardiovascular system examination was normal. Uterus was 34-36 weeks size, fetal heart rate was 136/min, 1+ proteinuria was present. The present diagnosis of Bell's palsy was made after medicine consultation and after performing all the tests of facial nerve such as absence of frowning, inability to blow, inability to close eyes and investigations to rule out other causes of facial palsy were done. No investigations and tests had positive findings. MRI brain was done and was within normal limits. The patient was advised physiotherapy and prescribed with multivitamins and anti hypertensive (labetalol 100mg BD). She was asked to follow up regularly in antenatal outpatient

controversial whether added valacyclovir or acyclovir will hasten recovery. High rate of spontaneous recovery has been observed and this has been associated with resolution of physiological and anatomical changes after antenatal period.



**CONCLUSIONS**

Women with Bell's palsy during pregnancy should be evaluated critically as in some it may be manifestation of some neurological disorder and it can be labelled as idiopathic only after ruling out all predisposing factors. It can act as an indicator for another underlying medical condition. As it is a self limiting condition, careful evaluation and timely steroids are supposed to give maximum benefit. However, steroids can act as a double edged sword in these patients, hence they require close monitoring, follow up and patient compliance is an equally important factor.

**REFERENCES:**

1. C. Bell, The Nervous System of the Human Body, Longman, Hurst, Rees, Orme, Brown & Green, London, UK, 1830.
2. Beal MF, Hauser SL: Trigeminal neuralgia, Bell's palsy, and other cranial nerve disorders. In Jameson JL, Fauci AS, Kasper DL, et al (eds): Harrison's Principles of Internal Medicine, 20th ed. New York, McGraw-Hill Education, 2018, p 3169
3. Choi HG, Hong SK, et al: Pregnancy does not increase the risk of Bell's Palsy: a national cohort study. Otol Neurotol 41(1):e111, 2020
4. R.L. Hilsinger Jr., K.K. Adour, and H.E. Doty, "Idiopathic facial paralysis, pregnancy, and the menstrual cycle," Annals of Otolaryngology, Rhinology and Laryngology, vol.84, no.4, part 1, pp.433-442, 1975.
5. D. Shmorgun, W.-S. Chan, and J. G. Ray, "Association between Bell's palsy in pregnancy and pre-eclampsia," Quarterly Journal of Medicine, vol. 95, no. 6, pp. 359-362, 2002.
6. Katz A, Sergienko R, Dior U, et al: Bell's palsy during pregnancy: is it associated with adverse perinatal outcome? Laryngoscope 121:1395, 2011
7. M. J. Ramsey, R. DerSimonian, M. R. Holtel, and L. P. A. Burgess, "Corticosteroid treatment for idiopathic facial nerve paralysis: a meta-analysis," The Laryngoscope, vol. 110, no. 3, part 1, pp. 335-341, 2000.