



FILICIDE-FETICIDE-SUICIDE: AN UNUSUAL VARIANT OF TRIADIC DEATH – A CASE REPORT

Forensic Medicine

**Dr. Kemsaram
Kiranmai**

Second Year Post Graduate, Department Of Forensic Medicine And Toxicology, Osmania Medical College, Hyderabad, India.

**Dr. Abhijit
Subhedar**

Professor And Hod, Department Of Forensic Medicine And Toxicology, Osmania Medical College, Hyderabad, India.

ABSTRACT

According to the inquest report, a 22year old pregnant female after prolonged verbal abuse by her husband and in laws killed her son by hanging him with the help of saree, later committed suicide by hanging from the other end of the same saree. They were found dead on 24/06/2023 at 01:00AM at their residence with feet touching the bed and doors locked from inside. D1 is pregnant female and D2 is her son. Bodies were shifted to OGH Mortuary for post-mortem examination by the investigating officer. The postmortem findings were D1 pregnant female had an ante mortem oblique ligature mark which is non-continuous around the neck, above the level of thyroid cartilage, in the midline extending from right posterior hair line to left posterior hair line. D2 son had an ante mortem non-continuous ligature mark around the neck, passing above the level of thyroid cartilage extending from right mastoid eminence to left posterior hair line. As per inquest report, post mortem examination and circumstantial evidences the cause of death in D1 is HANGING and the cause of death in D2 was given as HOMICIDAL HANGING.

KEYWORDS

Triadic deaths, homicide-suicide, pregnant female, filicide and death of foetus.

INTRODUCTION:

- Dyadic suicides** comprise of suicides occurring simultaneously or one after another in two or more people, either with an agreement or without one. [1]
- Investigation of dyadic deaths remains a challenge for the investigators especially in concluding on the **cause and manner** of death. [1]
- Dyadic deaths are **relatively unusual**: the global rate ranges between 0.02 and 0.46 per 100,000 per year, with significant national and regional variations. [1]
- Most often the mothers are **depressed and/or psychotic** before and at the time of committing the acts. [2]
- In turn, there is unspecified psychoses, which range from acute psychotic episodes to reactive or puerperal psychoses and affect 1.9 out of 1000 people. [2]
- Maternal filicides [59%]** are more common than paternal filicide [39%]. [3]
- Typically, the perpetrator mother beats, suffocates, stabs, strangles, drowns or throws the child from a window and uses a similar method for her own suicide **commonly by hanging and poisoning**. [3]

Case:

A 22-year-old moderately built pregnant female^(fig1) was found dead by hanging to ceiling fan with the help of a saree along with her 2 and half year old moderately built son(fig1) who was hanged to other end of saree. They were found dead on 24/06/2023 at 01:00AM in their house with feet touching the bed and doors locked from inside. The deceased bodies were brought to mortuary, Osmania general hospital at 02:00 PM on 24/06/2023 by the investigating officer and requested for post mortem examination.



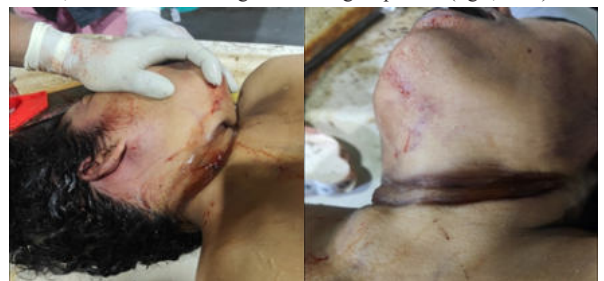[fig1] Crime scene photo

Post Mortem Examination:

The post mortem findings were as such: D1- A 22-years-old female of height 150cms, with moderately built body. Conjunctivae were congested. Finger nail beds are bluish in colour. Abdomen is distended. Body was preserved in cold storage. Post-mortem lividity present over back of the body and in lower limbs. Rigor Mortis present all through the body.

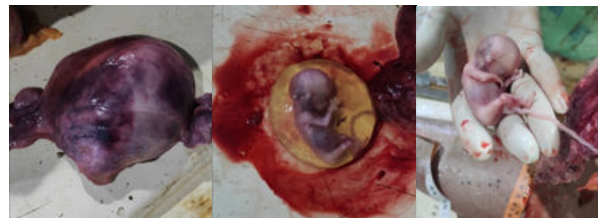
On examination,

An ante mortem reddish brown non-continuous ligature mark of length 24cms with varying width of 1-3cms, broader on right side and narrower on left side, obliquely placed in front and sides of neck on and above the level of thyroid cartilage in the midline extending from right posterior hair line to left posterior hair line was noted with an inverted "V" shaped impression on occipital area and with a gap of 8cms on back of neck (fig 2&3). UTERUS: Pregnant, measuring size 17cm x 15cm x 5cm. length of foetus is 9cms and umbilical cord length is 11cms, a foetus of 3months gestational age is present (fig 4,5 & 6).



[fig 2]

[fig 3]



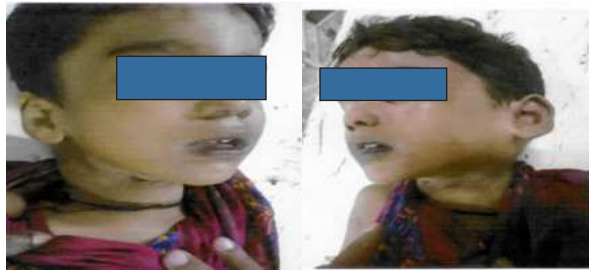[fig 4]

[fig 5]

[fig 6]

D2 - A 2 and half years-old male child of height 101cms, with moderately built body. Conjunctivae were congested. Finger nail beds are bluish in colour. Body was preserved in cold storage. Post-mortem Lividity present over back of the body and in lower limbs. Rigor Mortis present all through the body.

- On examination, an ante mortem reddish brown non continuous ligature mark of length 18cms with varying width of 1-3cms, broader on right side of neck and narrower on left side of neck, obliquely placed in front and sides of neck on and above the level of Thyroid cartilage in the midline, the ligature mark is extending from right mastoid eminence to left posterior hair line was noted with an inverted "V" shaped impression on occipital area and with a gap of 10cms on back of neck (fig 7&8).



[fig 7]

[fig 8]

DISCUSSION:

- Suicide** in any of its form is a global health issue. The estimated annual burden of suicides each year is 14.5 suicides per 100,000 populations. Prevalence of suicidal death in India is 10.6 per 100,000 populations (Accidental deaths and suicides in India 2015). The common precipitating factors for suicide include marital and financial problems, unemployment, depression and social isolation, alcohol abuse, physical and mental illness, etc. In Indian scenario, financial burden, marital disharmony, and substance abuse are the major factors associated with suicidal deaths. [1]
- Psychosis in pregnancy:** Psychosis refers to a disorder in which the person suffers a loss of perception with respect to reality, where he or she cannot distinguish what is real from what is unreal. In pregnant women, psychotic episodes can be the consequence of the manifestation of a previous psychiatric illness or may begin during the pregnancy itself, placing not only the mother, but also the foetus at risk during the psychotic episode. Among the main risk factors for suffering psychosis in pregnancy, having a family history of psychosis, previous history of psychosis in pregnancy and pre-existing or undiagnosed psychotic/mood disorder, such as schizophrenia or bipolar disorder, are considered. [2]
- Psychological autopsy:** The principle of psychological autopsy is based on the meticulous collection of data that are likely to help reconstitute the psychosocial environment of individuals who have committed suicide and thus understand better the circumstances of their death. Psychological autopsy appears to be a complex and multidimensional strategy. Studies involving psychological autopsy gather information on a large number of parameters including details about the person's death, family background, social context, life trajectory, social interaction, working conditions, physical/mental health and history, previous suicidal behaviour if any, negative elements in the person's life, contact if any with help line services before committing suicide, and reaction of friends and relatives to the suicide. [4]

REFERENCES:

- Ateriya et al. Egyptian Journal of Forensic Sciences (2018) 8:65 <https://doi.org/10.1186/s41935-018-0098-y>
- Ortega MA, Pekarek T, Fraile-Martinez O, Garcia-Montero C, Pekarek L, Rodriguez-Martin S, Funes Moñux RM, Bravo C, De León-Luis JA, Lahera G, Monserrat J, Quintero J, Bujan J, Garcia-Honduvilla N, Álvarez-Mon M, Alvarez-Mon MA. A Review: Integrative Perspectives on the Features and Clinical Management of Psychotic Episodes in Pregnancy. *J Clin Med.* 2023 Jan 13;12(2):656. doi: 10.3390/jcm12020656. PMID: 36675582; PMCID: PMC9864993.
- Kauppi A, Kumpulainen K, Karkola K, Vanamo T, Merikanto J. Maternal and paternal filicides: a retrospective review of filicides in Finland. *J Am Acad Psychiatry Law.* 2010;38(2):229-38. PMID: 20542944.
- INSERM Collective Expertise Centre. Suicide: Psychological autopsy, a research tool for prevention [Internet]. Paris (FR): Institute national de la santé et de la recherche medical; 2005. Available from: <https://www.ncbi.nlm.nih.gov/books/NBK7126/>