ORIGINAL RESEARCH PAPER
Volume - 13 | Issue - 08 | August - 2024 | PRINT ISSN No. 2277 - 8179 | DOI : 10.36106/ijsr
INTERNATIONAL JOURNAL OF SCIENTIFIC RESEARCH

EXTERNAL AUDITORY CANAL OSTEOMA WITH HIDDEN MIDDLE EAR CHOLESTEATOMA – A RARE CASE ASSOCIATION

Surgical Oncology

Josephine Joy* Mbbs, Ms Ent, Fellow In Department Of Head & Neck Surgical Oncology, Hcg Cancer Center, Bangalore, Karnataka, India – 560027 *Corresponding Author

Jinoraj R Mbbs, Ms Ent, Senior Resident, Department Of Otorhino Laryngology And Head And Neck Surgery, St. John's Medical College And Hospital, Bangalore, Karnataka, India – 560034

Balasubramanya A M Mbbs, Ms Ent, Professor, Department Of Otorhino Laryngology And Head And Neck Surgery, St. John's Medical College And Hospital, Bangalore, Karnataka, India – 560034

ABSTRACT

Aim: To highlight a rare association of external auditory canal osteoma with middle ear cholesteatoma. **Materials And Methods:** 20-year-old male, with right external auditory canal osteoma was treated surgically along with clearance of middle ear cholesteatoma at St. John's Medical College Hospital, Bangalore, Karnataka, India. **Results:** External auditory canal osteoma and middle ear cholesteatoma were approached via posterior meatotomy with canaloplasty, tympanoplasty and epitympanotomy. Patient had significant functional improvement following surgery with no recurrence till date. **Conclusion:** While addressing external auditory canal osteoma, the possibilities of rare association of middle ear cholesteatoma should be kept in mind and the surgeon should foresee the possibility of involvement of temporomandibular joint, facial nerve, ossicular erosion and labyrinthine fistula and thence, should be prepared to tackle any of the above situations appropriately.

KEYWORDS

external auditory canal osteoma, middle ear cholesteatoma

INTRODUCTION

The incidence of osteoma of the external auditory canal (EAC), a rare benign tumor, is estimated to be 0.05% of all otologic surgeries.(1) In the fourth decade of life, its incidence peaks with a male predominance.(2)

It presents as a solitary, pedunculated, slow growing, unilateral bony mass arising from the tympanomastoid or tympanosquamous suture lines adjacent to the bony cartilaginous junction of the external auditory canal. Usually, it is asymptomatic due to its slow growing nature. But, symptoms such as conductive hearing impairment and ear fullness develop in cases of canal obstruction.(2)

"Cholesteatoma is defined as a three dimensional epidermal and connective tissue structure, usually in the form of a sac and frequently conforming to the architecture of the various spaces of the middle ear, attic and mastoid. This structure has the capacity for progressive and independent growth at the expense of underlying bone and has a tendency to recur after removal."(3) It may be congenital or acquired.

Congenital cholesteatoma, according to Derlacki and Clemis, is described as having a pearly white mass medial to an intact tympanic membrane, a normal pars tensa and flaccida, and no prior history of otologic procedures, tympanic membrane perforation or otorrhea.(4) Levenson et al. proposed that congenital cholesteatoma should not be excluded because of previous episodes of otitis media.(5)

Four theories which has been put forward to explain the etiopathogenesis of acquired cholesteatoma are:

1. Invagination Theory (Retraction Pocket Theory)
2. Theory of Epithelial Invasion or Migration (Immigration Theory)
3. Theory of Squamous Metaplasia
4. Basal Cell Hyperplasia Theory (Papillary Ingrowth Theory)(6)

Case Presentation

A 20-year-old male patient presented with complaints of growth in the right ear canal in the last 2 years. Patient was apparently normal 2 years back, while he noticed a growth in right ear canal while cleaning the canal with earbuds, which bled and was associated with pain. It was not associated with ear discharge or itching. Later, he was symptom free for following 1 year and 10 months. Further, in the last 2 months, he developed insidious onset of progressive right ear pain, aural fullness and hearing loss, associated with increase in growth in right ear canal occluding it completely. The patient did not have any relevant medical history or any significant family history. He did not have any difficulty in mouth opening of jaw pain while chewing.

On examination, there was bony hard mass covered by pink colored mucosa completely occluding the right ear canal, 2cm medial to outer end of right external auditory canal. A probe could be passed all around the mass except at the antero superior quadrant.

Investigations :

Pure Tone Audiometry

Right ear: 97.5 decibel profound hearing loss

Left ear: 20 decibel minimal hearing loss

High Resolution Computed Tomography Scan Of Temporal Bone Without Contrast

Right Temporal Bone: A relatively well defined pedunculated partly calcified lesion (average HU of 544) measuring approximately 12.5 x 10.5 x 16.32 mm (AP x ML x CC) is noted arising from the anterior wall of the junction of osseous and cartilaginous right external auditory canal obliterating the canal lumen. There is paucity of mastoid air cells with sclerosis of mastoid part of temporal bone and soft tissue thickening noted involving the mastoid air cells and middle ear cavity including the aditus and prussak's space. There is evidence of erosion of head of mallets and proximal aspect of body of incus with subtle erosion involving the lateral wall of the bony canal of the tympanic segment of the facial nerve. Tympanic membrane could not be visualized.

Left Temporal Bone: Normal

Differential Diagnosis

Clinically in view of bony hard swelling in the external auditory canal, the possibilities of osteoma, exostoses, external auditory canal cholesteatoma, keratosis obturans, benign necrotizing otitis externa were considered.

Treatment

External auditory canal mass was approached via posterior meatotomy following post aural William Wilde's incision. The mass was dislodged from its attachment and removed in toto. 360-degree canaloplasty was done being more aggressive at the antero superior region. Tympanic membrane was found adherent to promontory. On elevation of tympanomeatal flap after careful dissection, granulation and cholesteatoma was found in mesotympanum, hypotympanum, anterior and posterior epitympanum associated with attic erosion. Atticotomy was done. Eroded short process of incus, head of malleus was removed along with granulation and cholesteatoma following which type 2 tympanoplasty was done. External auditory canal was packed with medicated gel foam and mastoid dressing was placed.

Outcome & Follow Up

Mastoid dressing was removed and post aural dressing was done on post operative day 2. Post aural sutures were removed on post operative day 7. The right ear was examined under microscope on post operative day 14, and medicated gel foam was found to be in situ without any signs of infection. Examination under microscope on post operative day 30, revealed, congested external auditory canal with an intact tympanic membrane. Post operative Pure Tone Audiometry showed improvement in hearing.

DISCUSSION

External auditory canal osteomas are rare benign tumors arising from the tympanomastoid or tympanosquamous suture lines adjacent to the bony cartilaginous junction of the external auditory canal. (2) An osteoma originates from the preosseous connective tissue in these suture lines because due to the presence of a thicker subcutaneous layer and a richer blood supply than the other bony canal.(7)

It usually occurs in the fourth decade of life with a male predominance and presents as a solitary, pedunculated, slow growing, unilateral bony mass. It gradually progresses in size and remains asymptomatic till it gains size to cause canal obstruction resulting in hearing impairment, usually conductive type and ear pain.(2) Mixed or sensorineural hearing loss (longstanding passage of toxic substances through the round window membrane which is often found in chronically infected ears with and without cholesteatoma) may result from the long-standing infectious process itself, especially of the middle ear cavity. (8)

Its aetiology includes trauma, surgery, radiotherapy, chronic infection, and glandular factors such as pituitary dysfunction, the precise aetiology is still unknown and considered to be a true bone tumour.(9) Surgical excision is the main treatment for EAC osteoma in patients with growing osteoma occluding the EAC with complaints of recurrent infection and conductive hearing impairment. Osteoma may be removed by drilling or by using an osteotome via transmeatally if it is located at the lateral portion, is pedunculated or via the post auricular approach if it is located medial to the isthmus, is huge, or broad based. Patients with a small osteoma and little or no symptoms may be treated in a conservative manner. (10)

Radiologically they present as unilateral solitary pedunculated bony overgrowth of the external auditory canal usually at the bony cartilaginous junction.

No studies have been reported in the literature till date where external auditory canal osteoma has occurred in conjunction with middle ear cholesteatoma, as was observed in this case.

It should be differentiated from exostoses which is a benign periosteal bone growth from deep part of meatus which forms a smooth, sessile mass adjacent to tympanic membrane. These are usually multiple and are bilateral (11) and develop secondary to cold water exposure as in water sports enthusiasts; surfers, divers. (12) They are usually asymptomatic until they enlarge to cause a stenosis of greater than 80% of the canal lumen leading to recurrent otitis externa, chronic infection, wax and debris accumulation, conductive hearing loss and even canal cholesteatoma.(13)

The invasion of squamous epithelium into a localized region of bony erosion with or without bone necrosis is termed primary auditory canal cholesteatoma.(11) The etiology of external ACC is uncertain. It may be post traumatic or post-surgical (e.g., stapectomy) where a piece of exposed bone of the auditory canal becomes infected and sequests resulting in epithelial migration into it (14) or it may result from a reduced migratory capacity of the canal epithelium which leads to 'keratinization in situ'.(15) Its etiology has been linked to branchial arch anomalies that result in the retention of epithelial masses and paves way for cholesteatoma formation in the floor of EAC.(16) Patients usually presents with unilateral otalgia, itchiness, blocked feeling, otorrhea without hearing loss.(11)

"Keratosis obturans is the accumulation of a large plug of desquamated keratin in the external auditory meatus."(11) It is proposed to develop due to abnormal epithelial migration of the external auditory canal skin which may arise either secondary to inflammation (viral infection) or due to abnormal separation of the keratin (silent type).(17) Symptoms of severe otalgia and conductive hearing loss are common which is usually unilateral.(11)

The development of an avascular bony sequestrum of the inferior tympanic bone along with secondary inflammation of the overlying soft tissue and skin is termed as benign necrotizing otitis externa.(11) The etiology of necrotic bone in BNOE is unknown.(18) The proposed theories include vascular insufficiency(19), repeated local trauma (e.g., earbud abuse, picking of the ear or the use of hearing aids)(20), 'neurotropic disturbances.(21)' Patients present with chronic painless infected otorrhea, dehiscent skin with localized exposed bone.

CONCLUSION

While addressing external auditory canal osteoma, the possibilities of canal cholesteatoma, middle ear cholesteatoma, hidden pathological changes of the middle ear cleft should be kept in mind and the surgeon should be prepared to tackle any of the above situations on table appropriately.

Inside out mastoidectomy is a better alternative in canal wall down procedures as it not only clears the disease from the middle ear cleft, but also leaves behind a small postoperative cavity, which will preserve the hearing, decrease the cavity problems and increase the quality of life of such patients

Figure Captions

1. **Figure 1:** Mass completely occluding the external auditory canal
2. **Figure 2:** Pure Tone Audiogram
3. **Figure 3:** External auditory canal mass exposed via posterior meatotomy following post aural William Wilde's incision during Microscopic Ear Surgery under GA
4. **Figure 4:** Intra operative photograph showing removal of external auditory canal mass
5. **Figure 5:** Histopathological Examination showing osteoma with cholesteatoma
6. **Figure 6:** Post operative photograph showing completeness of removal



Figure 1

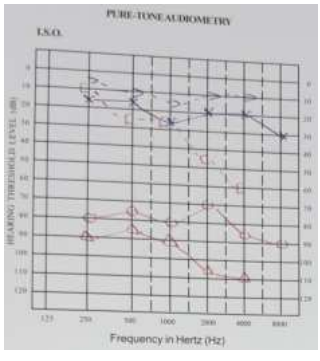

Figure 2



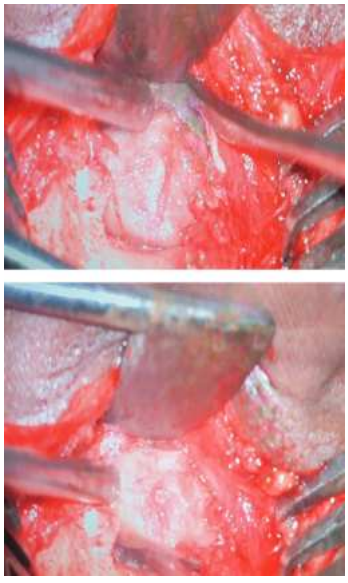

Figure 3(a, B, C)

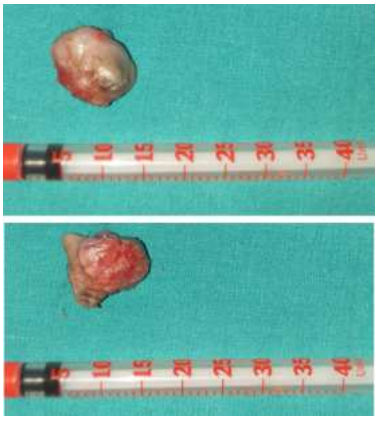

Figure 4(a, B)

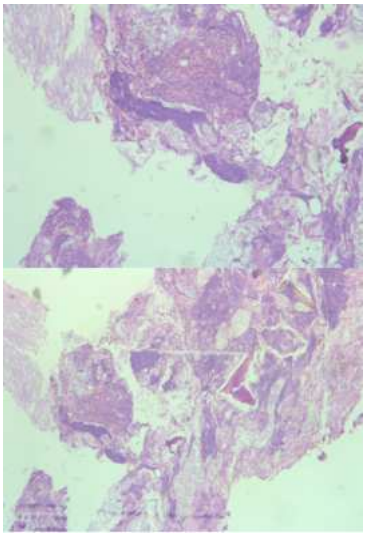

Figure 5



Figure 6

Acknowledgements: We express our gratitude to the Head of Department of ENT of St. John's medical college hospital, Bangalore, India for the whole hearted support for conduction and completion of this study.

Ethical Statement:

1. **Funding:** This study was not funded by any funding sources.
2. **Competing Interests:** The authors declare none.
3. **Informed Consent:** An informed consent was obtained from patients before procedures.

REFERENCES

1. Sheehy J. Diffuse exostoses and osteomata of the external auditory canal: a report of 100 operations. Otolaryngol Head Neck Surg. 1982;
2. Lee DH, Jun BC, Park CS, Cho KJ. A case of osteoma with cholesteatoma in the external auditory canal. Auris Nasus Larynx. 2005 Sep;32(3):281–4.
3. Ludman H, Wright T. Diseases of the Ear. Glasgow Med J.
4. Derlacki EL, Clemis JD. Congenital cholesteatoma of the middle ear and mastoid. Ann Otol Rhinol Laryngol [Internet]. 1965 [cited 2023 Feb 28];74(3):706–27. Available from: https://pubmed.ncbi.nlm.nih.gov/5846535/
5. Levenson MJ, Parisier SC, Chute P, Wenig S, Juarbe C. A review of twenty congenital cholesteatomas of the middle ear in children. Otolaryngol Head Neck Surg [Internet]. 1986 [cited 2023 Feb 28];94(5):560–7. Available from: https://pubmed.ncbi.nlm.nih.gov/3088516/
6. Kuo CL. Etiopathogenesis of acquired cholesteatoma: prominent theories and recent advances in biomolecular research. Laryngoscope [Internet]. 2015 Jan 1 [cited 2023 Feb 28];125(1):234–40. Available from: https://pubmed.ncbi.nlm.nih.gov/25123251/
7. Fenton FJE, Turner TJ, Fagan FPA. A histopathologic review of temporal bone exostoses and osteomata. Laryngoscope [Internet]. 1996 [cited 2023 Mar 1];106(5 Pt 1):624–8. Available from: https://pubmed.ncbi.nlm.nih.gov/8628093/
8. Lee DH, Jun BC, Park CS, Cho KJ. A case of osteoma with cholesteatoma in the external auditory canal. Auris Nasus Larynx [Internet]. 2005 Sep [cited 2023 Mar 1];32(3):281–4. Available from: https://pubmed.ncbi.nlm.nih.gov/15923098/
9. Graham MD. Osteomas and exostoses of the external auditory canal: A clinical, histopathologic and scanning electron microscopic study. Annals of Otology, Rhinology & Laryngology. 1979;88(4):566–72.
10. Fisher EW, McManus TC. Surgery for external auditory canal exostoses and osteomata. J Laryngol Otol 1994;108:106–10. - Yahoo Search Results [Internet]. [cited 2023 Mar 1]. Available from: https://search.yahoo.com/search;_ylt=AwrjbFCNXv5jfdYR.SZXNyoA;_ylc=X1MDMjc2NjY3OQRfcgMyBGZyA21jYWZlZQRmcjIDc2ltdG9wBGdwcmlkA294cERCQUhaUnhlQjB0YTJGcUE4SUEEbl9yc2x0AzAEbl9zdWdnAzAEb3JpZ2luA3NlYXJjaC55YWhvby5jb20EcG9zAzAEcHFzdHIDBHBxc3R ybAMwBHFzdHJsAzExNwRxdWVyeQMlMjBGaXNoZXIlMjBFVyUyQyUyME1jTWFudXMlMjBUQy4lMjBTdXJnZXJ5JTIwZm9yJTIwZXh0ZXJuYWwlMjBhdWRpdG9yeSUyMGNhbmFsJTIwZXhvc3Rvc2VzJTIwYW5kJTIwb3N0ZW9tYXRhLiUyMEolMjBMYXJ5bmdvbCUyME90b2wlMjAxOTk0JTNCMTA4JTNBMTA2JUUyJTgwJTkzMTAuBHRfc3RtcAMxNjc3NjE0NzY5?p=+Fisher+EW%2C+McManus+TC.+Surgery+for+external+auditory+canal+exostoses+and+osteomata.+J+Laryngol+Otol+1994%3B108%3A106%E2%80%9310.&fr2=sb-top&fr=mcafee&type=E211US826G0
11. Watkinson JC, Clarke RW. Scott-Brown's otorhinolaryngology and head and neck surgery. Volume 2, Paediatrics, the Ear, and Skull Base Surgery. 2018 [cited 2023 Feb 28];2673. Available from: https://books.google.com/books/about/Scott_Brown_s_Otorhinolaryngology_and_He.html?id=2tFfDwAAQBAJ
12. Wong BJF, Cervantes W, Doyle KJ, Karamzadeh AM, Boys P, Brauel G, et al. Prevalence of external auditory canal exostoses in surfers. Arch Otolaryngol Head Neck Surg [Internet]. 1999 [cited 2023 Feb 28];125(9):969–72. Available from: https://pubmed.ncbi.nlm.nih.gov/10488981/
13. Agarwal A, Deschler D, Baker KB. Exostoses of the external auditory canal. Am J Otol. 1999;
14. Owen HH, Rosborg J, Gaihede M. Cholesteatoma of the external ear canal: etiological factors, symptoms and clinical findings in a series of 48 cases. BMC Ear Nose Throat Disord [Internet]. 2006 Dec 23 [cited 2023 Mar 1];6. Available from: https://pubmed.ncbi.nlm.nih.gov/17187684/
15. Makino K, Amatsu M. Epithelial migration on the tympanic membrane and external canal. Arch Otorhinolaryngol [Internet]. 1986 Mar [cited 2023 Mar 1];243(1):39–42. Available from: https://pubmed.ncbi.nlm.nih.gov/3707423/
16. Hickey SA, Scott GA, Traub P. Defects of the first branchial cleft. J Laryngol Otol [Internet]. 1994 [cited 2023 Mar 1];108(3):240–3. Available from: https://pubmed.ncbi.nlm.nih.gov/8169509/
17. Soucek S, Michaels L. Keratosis of the tympanic membrane and deep external auditory canal. A defect of auditory epithelial migration. Eur Arch Otorhinolaryngol [Internet]. 1993 [cited 2023 Mar 1];250(3):140–2. Available from: https://pubmed.ncbi.nlm.nih.gov/8357603/
18. BOTTARI G. Comment on a case of circumscribed benign necrosant osteitis of the ear canal. Valsalva [Internet]. 1948 Jul 1 [cited 2023 Mar 1];24(7–8):183–8. Available from: https://europepmc.org/article/MED/18885487
19. GOUFAS G. [Diagnosis and pathogenesis of benign necrotic osteitis of the external ear canal]. Ann Otolaryngol [Internet]. 1954 Jan 1 [cited 2023 Mar 1];71(5–6):390–6. Available from: https://europepmc.org/article/MED/13181193
20. Youngs R, Willatt D. Benign necrotizing osteitis of the external auditory meatus. J Laryngol Otol [Internet]. 1985 [cited 2023 Mar 1];99(8):805–8. Available from: https://www.cambridge.org/core/journals/journal-of-laryngology-and-otology/article/abs/benign-necrotizing-osteitis-of-the-external-auditory-meatus/466A8D27255E95A0D7F50F5566A2078C
21. Bharadwaj VK, Walling KE, Rees J, Novotny GM. Necrosis and sequestration in the tympanic part of the temporal bone. Journal of Otolaryngology. 1984;13(5):299–304.