



UNUSUAL PRESENTATION OF PAEDIATRIC TERATOMA: 2 CASE REPORTS.

Urology

Kaustubh Vaidya

Assistant Professor in Urology, Grant Medical College and J.J. group of hospitals, Mumbai, India.

Ojas Vijayanand Potdar*

Assistant Professor in Urology, Grant Medical College and J.J. group of hospitals, Mumbai. *Corresponding Author

KEYWORDS

INTRODUCTION:

Germ cell tumors (GCT) are tumors arising from primordial germ cells. Gonadal and extra gonadal GCT are infrequent in childhood occurring at a rate of 2.4 cases per million children accounting for 2-3 % of pediatric malignancies with most common pathologic subtype being a matured Teratoma (44%).¹

The word is derived from the Greek teras, meaning monster, which Virchow coined in the first edition of his book on tumors published in 1863. We describe two case reports of unusual presentation of pediatric teratoma.

Case reports:**Case-1:**

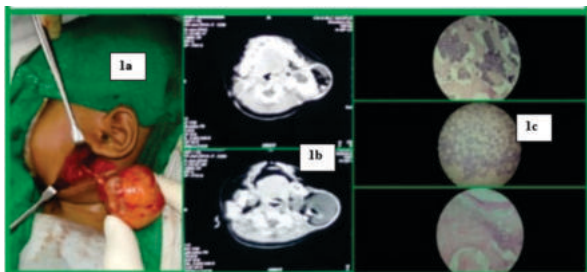
3 Months old female child presented with complaints of a swelling over left parotid region since birth. Swelling was nontender slow growing firm freely mobile 4 x 4 cm in dimension.

Ultra sonogram of left parotid revealed a well-defined cystic lesion with internal echoes solid components and dense calcifications.

CECT Head revealed well defined round to oval cystic lesion in left parotid region with parotid gland not separately visualized; lesion showing fatty component and calcifications.

Treatment: Total Parotidectomy -Tumor was involving both the lobes of parotid but not the facial nerve so total parotidectomy was done & facial nerve was spared.

Histopathological examination of the specimen revealed a Matured Teratoma. It is a rare presentation of extragonadal Teratoma.



Figures 1a- Intraoperative image of left sided extragonadal parotid region teratoma.

1b- CECT head images of the Left sided extragonadal parotid region teratoma.

1c: Histopathology examination findings of the excised left sided extragonadal parotid region teratoma.

Case-2:

10-year-old female patient presented with cough with expectoration, fever and hemoptysis with a similar episode 15 days back.

CECT Thorax:

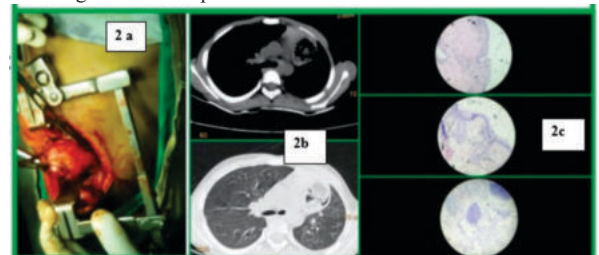It revealed well defined lobulated smoothly emarginated lesion in anterior mediastinum with fat densities, air foci and obvious communication with bronchi, centrilobular ground-glass radiopacities with bronchiectatic changes with a consolidatory patch noted in left lingual lobe and a diagnosis of thymolipoma was made.

Treatment:

Thoracotomy with resection of the mass was done. On exploration, a mass adherent to aortic pericardium and pleura, communicating with lingual bronchus was found. Cheesy pultaceous material was coming out through the mass. Mass along with the pathological lingual lobe was excised.

Histology:

It was suggestive of a mediastinal matured teratoma with bronchiectasis, pneumonitis and hemorrhage in lung tissue. So, the final diagnosis was a ruptured mediastinal teratoma.



Figures 2a- Intraoperative image of thoracotomy with resection of mass.

2b – CECT Thorax images of the mass.

2c- Histopathology examination images of the resected mass.

DISCUSSION:

Extragonadal germ cell tumors arise from aberrant or incomplete migration of primordial germ cells. Another hypothesis being origin from totipotent embryonic cells that have escaped the influence of embryonic organizers controlling normal differentiation.²

Surgical resection is the therapy of choice in benign tumors like Matured teratoma. Chemotherapy and radiotherapy play no role. In malignant tumors (immature teratoma) in patients over 15 years of age, adjuvant cisplatin-based combination chemotherapy is recommended.

CONCLUSION:

These case reports demonstrate that a very degree of suspicion by the treating surgeon is required to diagnose and manage these cases and that final diagnosis is confirmed by histopathology and thus possess a unique challenge to manage these cases.

Consent for publication:

Consent for publication has been given by all the authors mentioned in the study.

Availability of data and material:

The data and material required for the conduct of the study was collected by filing out case proforma sheets and use of hospital information system to collect patient related reports and other related data required for the study after obtaining consent from the patient and the hospital administration.

Competing interests –

There are no competing interests-

- The authors have no relevant financial or non-financial interests to disclose.
- The authors have no competing interests to declare that are

relevant to the content of this article.

Source of Support and Funding – None.

- No funding was received to assist with the preparation of this manuscript.
- No funding was received for conducting this study.

Authors contribution:

Author-1-Kaustubh Vaidya: - Principal investigator of the study and history taking

Author-2-Ojas Vijayanand Potdar-Writing the manuscript.

Acknowledgements:

I duly acknowledge the hospital administration and the staff at Government Medical college, Nagpur, Maharashtra, India for their co-operation in conducting the study.

REFERENCES:

1. Travis LB, Beard C, Allen JM, et al Testicular cancer survivorship: research strategies and recommendations. *J Natl cancer inst* 2010;102:1114-1130.
2. Ries LAG SM, Gurney JG, Linet M, et al., eds. Cancer incidence and survival among Children and Adolescents: United States SEER programme 1975-1995, National Cancer Inst, SEER program. NIH publication no994649. Bethesda, MD National Cancer Inst 1999.