



TRANSORAL ENDOSCOPIC THYROIDECTOMY VESTIBULAR APPROACH (TOETVA) VERSUS OPEN THYROIDECTOMY- A PROSPECTIVE NON RANDOMIZED COMPARATIVE STUDY FOR THYROID SWELLINGS

General Surgery

Dr. Pravin D Bhingare

Associate Professor, Dept Of General Surgery, Gmc, Nagpur.

Dr. Vinod Nayak S*

Assistant Professor, Dept Of General Surgery, Scmch, Channapatna *Corresponding Author

Dr. Sanjay D Dakhore

Associate Professor, Dept Of General Surgery, Gmc, Nagpur.

Dr. Prasad Bansod

Assistant Professor, Dept Of General Surgery, Gmc, Nagpur.

ABSTRACT

Open Thyroidectomy is the standard surgical technique for thyroid swellings. Scarless thyroid surgeries are gaining popularity in recent years, one of which is TOETVA. The study elaborates the advantages and drawbacks, learning curve, complications and limitations of TOETVA with open surgery. Study was conducted from June 2019- November 2022 including 52 patients, each group containing 26 patients allocated through serial sequential sampling method. Thyroid nodule size of 6 cm was taken for both groups, patients with previous neck surgeries, neck scar and neck radiation were excluded. Mean operating time was 104.07 and 72.21min ($p=0.005$), Post operative pain 2.75 and 4.77 ($p=0.001$), Intraoperative blood loss of 17.25 and 39.54ml ($p=0.001$), duration of stay was 5.93 and 9.12 days ($p=0.001$), cosmesis score was 2.07 and 6.77 ($p=0.001$) noted in TOETVA and open group respectively. In conclusion, TOETVA has advantages of good cosmesis, less blood loss, hospital stay, post operative pain while it requires long learning curve with increasing operating time.

KEYWORDS

TOETVA, Endoscopic Thyroidectomy, Scarless Thyroidectomy, Minimally Invasive Thyroidectomy

INTRODUCTION

Thyroidectomy is one of the common surgeries performed all over the globe and consisted of open thyroidectomy since beginning, which includes a minimum of 6 to 8 cm of scar in lower neck. Visible scar is one of the concerns for many patients. Multiple endoscopic and remote access techniques were developed over the past two decades for this concern (1). They can be classified into techniques via cervical approach and extracervical approach (2). Cervical approach includes a small incision in the neck and Extra-cervical approach includes incisions in axilla, breast, combined axilla and breast, transoral and retroauricular region (3,4). TOETVA, popularized by Anuwong et al (4). In our study we include this surgical approach (TOETVA) and compare it with conventional open thyroidectomy in our institution in central India.

METHODS

This is a prospective, non randomized, comparative study which included patients presenting with thyroid swellings to our institution, Government Medical College and Hospital, Nagpur from June 2019 to November 2022 who required thyroidectomy. Patients with thyroid nodule of maximum size 6cm were included in this study and both benign and malignant causes of thyroid nodules were included. All patients were euthyroid at the time of surgery. Patients with previous neck surgery, neck radiation, oral cavity malignancies, thyroid malignancy with lymphadenopathy or distant metastasis were excluded from this study. Sample size was calculated based on study conducted by Jipratoom et al in 2016 (5). Total of 52 patients were included in this study and were allotted to TOETVA and Open Thyroidectomy group, each group consisting of 26 patients. Informed consent was taken from all patients and ethical committee clearance obtained from Institutional Ethics Committee. All patients were followed up for 6 months postoperatively to document any possible complications. Data collected in Microsoft excel and statistical methods applied, Chi square tests were applied for categorical data, p value of <0.05 were considered statistically significant and analyzed in a statistical software STATA v10.1(2011).

Operative Technique:

Toetva : Under GA, patient was put in rose position and nasotracheal intubation done. Oral cavity prepped with 0.1% Chlorhexidine. Single midline incision taken in lower vestibule and a 10mm camera port in midline and two 5mm working ports inserted laterally, one on each side taking care to avoid injury to mental nerve. Midline tunneling done through subfascial planes and thyroid gland reached. Carbon dioxide insufflations done at 6 mm hg and surrounding tissues dissected out to

delineate the thyroid swelling completely. Thyroid dissected from superior to inferior pole and along isthmus taking care to avoid injury to parathyroids and recurrent laryngeal nerve. Isthmus divided at last and specimen retrieved through midline camera port. Hemostasis confirmed and checked. Vestibular incision closed using vicryl 3-0 and pressure bandage and dressing applied in neck for 48 hr (6). Amoxicillin+Clavulanic acid 1.2 gm IV at induction and till post operative day 2. All patients were started on oral diet on postoperative day 2 and monitored for early complications if any.

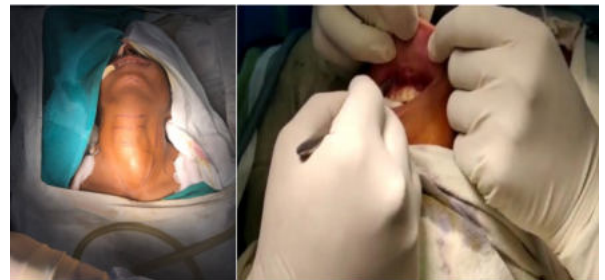

Figure 1: Draping and marking with Vestibular incision

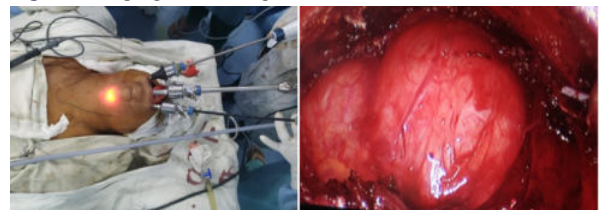


Figure 2 : Port placements and Intraoperative Right thyroid nodule

Open Thyroidectomy: Under GA, patient was put in rose position and orotracheal intubation done. Parts painted and draped. 6 to 8 cm incision was taken 2 finger breadth above suprasternal notch and subplatysmal plane elevated. Strap muscles dissected and thyroid nodule and gland dissected all around taking care not to injure parathyroids and recurrent laryngeal nerve. Hemithyroidectomy done and hemostasis achieved and confirmed. Romovac suction drain 14 fr kept in subplatysmal plane and skin closed using monocryl 3-0 subcuticular manner. Sterile dressings applied. Amoxicillin+Clavulanic acid 1.2 gm IV at induction and till post operative day 2. All patients were started on oral diet on postoperative day 1 and monitored for early complications if any.

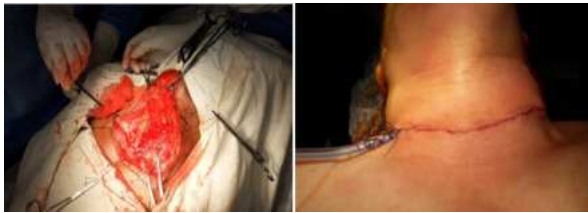


Figure 3 : Intraoperative photograph and post op suture with drain

RESULTS :

Both surgeries were done by a single surgeon to minimize errors in operating time and learning curve. Total of 52 patients underwent surgery and the results are tabulated in Table 1. The Mean age for TOETVA was 33.6 years and for Open thyroidectomy was 35.5 years. 75% of women preferred TOETVA over open surgery. Mean operating time was 104.07 min for TOETVA, while it was 72.21 min for open thyroidectomy (p>0.005). Mean blood loss in TOETVA group was 17.25ml and 39.45ml in open surgery (p<0.001). Post operative pain was calculated on VAS scale of pain(7) which was calculated till day 3. Mean postoperative pain was 2.75 in TOETVA, whereas it was 4.99 in open surgery group.

Table 1: Preoperative and Intraoperative parameters

	TOETVA	Open Thyroidectomy	p value
Mean age (years)	33.6 (20- 60)	35.5 (20- 60)	
Mean Size of Nodule (cm)	3.54 (2-6)	5.26 (2-6)	
Mean Operating time (min)	104.07 (90-120)	72.21 (60-90)	0.005
Mean Intraoperative blood loss(ml)	17.25 (10-22)	39.45 (30-50)	0.001
Mean Hospital stay (days)	5.93 (3-8)	9.12 (3-12)	0.001
Mean score of postoperative pain	2.75 (2-4)	4.77(3-6)	0.001
Mean score of cosmesis	2.07 (1-3)	6.77 (5-8)	0.001

2 patients had hypocalcemia post TOETVA, and in open surgery 6 patients presented with hypocalcemia and were treated with IV and oral calcium supplementation. None developed any permanent symptoms. Temporary recurrent laryngeal nerve palsy seen in 1 patient of TOETVA and 4 patients of open surgery. None of them developed permanent palsy after 6 months of follow up. Two patients from open surgery and one from TOETVA group had local seroma formation, which was treated. No other complications like mental nerve injury, vocal cord palsy, hematoma, surgical site infections were seen in both groups. Cosmesis was scaled from 1 to 10 based on VAS scale and mean score was 2.07 for TOETVA group and 6.77 for open thyroidectomy group (8). Major histopathological variant was colloid goiter in both groups.

Table 2: Postoperative complications

Complications	TOETVA	Open Thyroidectomy
Day of drain removal (days)	None	2.46
RLN neurapraxia	1	4
Seroma	1	2
Hypocalcemia	2	6

Table 3: Histopathological variants

Histopathological Variants	TOETVA	Open Thyroidectomy
Colloid goiter	19	15
Adenoma	05	02
Papillary	01	04
Follicular	01	05

DISCUSSION :

Conventional Open Thyroidectomy is the standard of care for all thyroid nodules since beginning, when Kocher revolutionized the procedure (9), which comes with a visible scar in neck, which is not perceived cosmetically well mainly by young women. This led to the advent and popularization of minimally invasive thyroid surgeries. Pioneered by Gagner, endoscopic neck surgery aroused interest in surgeons worldwide(10). All these surgeries were grouped under minimally invasive thyroid surgeries, which included Transoral, Transaxillary, bilateral breast approach, retroauricular, axillary and breast combined approaches. Among these Transoral technique had advantages of least dissection and use of laparoscopic instruments compared to all other techniques(4). Witzel et al demonstrated first

transoral thyroidectomy in cadaveric and porcine model(11). TOVAT, Totally Transoral Video Assisted Thyroidectomy was demonstrated by Benhidjeb et al.(12)

TOETVA has shortest access to thyroid gland, which helps in minimal dissection, less operating time and both hemithyroidectomy and total thyroidectomy can be performed in same midline incision(13). TOETVA is a true scarless surgery as oral mucosa heals rapidly making the vestibular incision invisible(6). This study describes the results of TOETVA compared to open surgery which included 26 patients in each group. Mean age of patients who underwent TOETVA was 33.6 years while it was 35.5 years for open surgery. Mean size of thyroid nodule was 3.54 cm in TOETVA while 5.26cm in open surgery. Mean intraoperative blood loss was also significantly less 17.25 ml in TOETVA as it is 39.54 ml in open thyroidectomy. Postoperative pain was significantly low among the TOETVA group, 2.75 compared to 4.77 on the visual analogue scale (p 0.001) which can be attributed to smaller incisions, and no need for drain placements. It is comparable with Jipratoom et al conducted for patients with graves' disease(5). The mean hospital stay of TOETVA is around 5.93 days, and that in Open Thyroidectomy is 9.12 days whereas it is same for both group of 6.1 and 6.3 days in Hau Xuan et al study.(14)

Postoperative complications in Open Thyroidectomy group was significant compared to TOETVA group. 1 and 4 patients had transient RLN palsy, with hoarseness of voice, in TOETVA and open group respectively, which resolved during follow up period of 3 months. Incidence of postoperative seroma formation was seen in both cases, which may be attributed to subplatysmal tunnel, incase of TOETVA and skin flap rising in Open group. All of which resolved without any life-threatening complications and surgical intervention. 2 patients had hypocalcemia post TOETVA, and in open surgery 6 patients presented with hypocalcemia and were treated with IV and oral calcium supplementation. None developed any permanent symptoms The important difference being cosmesis, in which TOETVA group had a mean of 2.07 and open group had 6.77 (p value <0.001). Patients who underwent TOETVA had a better accepted scar than the conventional group, without any visible scar in the neck, and very well accepted vestibular scar. Mean Operating time was better in Open Group(72.21 min), compared to TOETVA(104.07 min), especially in starting, owing to its learning curve which is comparable to Hau Xuan et al, which can be explained, by proper training of operating surgeons. Anuwong et al, reported operative time of 90 min for hemithyroidectomy and 135.5 min for total thyroidectomy(4). Another study comparing complications of TOETVA with open thyroidectomy reported transient RLN palsy of 4%, mental nerve injury of 1.4%, temporary hypoparathyroidism in 10.6% of TOETVA(15). In the TOETVA group, 19 cases were colloid goiters, 5 cases were benign adenomas, 1 was follicular neoplasm and 1 papillary thyroid neoplasm. In the Open Thyroidectomy group, 15 were colloid goiters, 2 were benign adenomas, 4 were follicular neoplasm and 5 papillary thyroid neoplasms, without any lymphnode or distant metastasis.

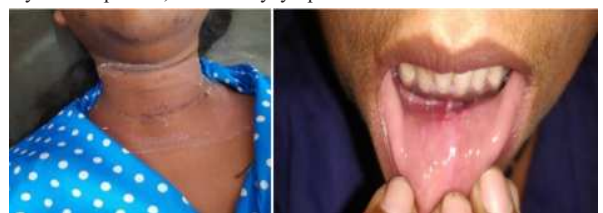

Figure 4: Postoperative scar of open Thyroidectomy and TOETVA.

CONCLUSION :

In this era of minimal access surgeries and patients demanding better cosmesis, minimally invasive thyroidectomy is the need of the hour. In this aspect TOETVA provides excellent cosmesis with less postoperative pain and less rates of postoperative complications. It provides a good alternative to Open Thyroidectomy for benign and non-metastatic malignant thyroid nodules with size less than 6 cm. Hence, TOETVA can be recommended for small benign and non-metastatic malignant Thyroid nodules. It is a technically feasible procedure which can be easily performed once the surgeon has conquered the learning curve. TOETVA can be implemented in treating larger benign nodules, malignant nodules, Central Node and Neck dissection and also for parathyroid surgeries. TOETVA can be implemented in Robotics with much better technological advancements.

REFERENCES:

1. Miccoli, P., Berti, P., Conte, M., Bendinelli, C., & Marcocci, C. (1999). Minimally invasive surgery for thyroid small nodules: preliminary report. *Journal of endocrinological investigation*, 22(11), 849–851. <https://doi.org/10.1007/BF03343657>
2. Chen, G. Z., Zhang, X., Shi, W. L., Zhuang, Z. R., Chen, X., & Han, H. (2012). Systematic comparison of cervical and extra-cervical surgical approaches for endoscopic thyroidectomy. *Surgery today*, 42(9), 835–841. <https://doi.org/10.1007/s00595-011-0100-x>
3. Inabnet, W. B., 3rd, Jacob, B. P., & Gagner, M. (2003). Minimally invasive endoscopic thyroidectomy by a cervical approach. *Surgical endoscopy*, 17(11), 1808–1811. <https://doi.org/10.1007/s00464-002-8760-7>
4. Anuwong A. (2016). Transoral Endoscopic Thyroidectomy Vestibular Approach: A Series of the First 60 Human Cases. *World journal of surgery*, 40(3), 491–497. <https://doi.org/10.1007/s00268-015-3320-1>
5. Jitpratoom, P., Ketwong, K., Sasanakietkul, T., & Anuwong, A. (2016). Transoral endoscopic thyroidectomy vestibular approach (TOETVA) for Graves' disease: a comparison of surgical results with open thyroidectomy. *Gland surgery*, 5(6), 546–552. <https://doi.org/10.21037/gs.2016.11.04>
6. N., Siddhartha & Cherian, Anish & Abraham, Deepak & Mazhuvanchary Jacob, Paul. (2019). Transoral endoscopic thyroidectomy vestibular approach: early experience in a single centre. *International Surgery Journal*. 6. 2016. 10.18203/2349-2902.isj20192358.
7. McCormack, H. M., Horne, D. J., & Sheather, S. (1988). Clinical applications of visual analogue scales: a critical review. *Psychological medicine*, 18(4), 1007–1019. <https://doi.org/10.1017/s0033291700009934>
8. Valente, J. H., Jay, G. D., Schmidt, S. T., Oh, A. K., Reinert, S. E., & Zabbo, C. P. (2012). Digital imaging analysis of scar aesthetics. *Advances in skin & wound care*, 25(3), 119–123. <https://doi.org/10.1097/01.ASW.0000412907.43335.a2>
9. Dubhashi, S. P., Subnis, B. M., & Sindwani, R. D. (2013). Theodor e. Kocher. *The Indian journal of surgery*, 75(5), 383–384. <https://doi.org/10.1007/s12262-012-0469-9>
10. Gagner M. Endoscopic subtotal parathyroidectomy in patients with primary hyperparathyroidism. *Br J Surg*. 2005;83(6):875.
11. Witzel, K., von Rahden, B. H., Kaminski, C., & Stein, H. J. (2008). Transoral access for endoscopic thyroid resection. *Surgical endoscopy*, 22(8), 1871–1875. <https://doi.org/10.1007/s00464-007-9734-6>
12. Benhidjeb, T., Wilhelm, T., Harlaar, J., Kleinrensink, G. J., Schneider, T. A., & Stark, M. (2009). Natural orifice surgery on thyroid gland: totally transoral video-assisted thyroidectomy (TOVAT): report of first experimental results of a new surgical method. *Surgical endoscopy*, 23(5), 1119–1120. <https://doi.org/10.1007/s00464-009-0347-0>
13. Inabnet, W. B., 3rd, Fernandez-Ranvier, G., & Suh, H. (2018). Transoral Endoscopic Thyroidectomy-An Emerging Remote Access Technique for Thyroid Excision. *JAMA surgery*, 153(4), 376–377. <https://doi.org/10.1001/jamasurg.2017.5306>
14. Nguyen, H. X., Nguyen, H. X., Le, A. D., & Van Le, Q. (2022). Comparison of Transoral Endoscopic Thyroidectomy Vestibular Approach and Conventional Open Thyroidectomy in Benign Thyroid Tumors. *Indian journal of surgical oncology*, 13(1), 178–183. <https://doi.org/10.1007/s13193-022-01494-x>
15. Anuwong, A., Ketwong, K., Jitpratoom, P., Sasanakietkul, T., & Duh, Q. Y. (2018). Safety and Outcomes of the Transoral Endoscopic Thyroidectomy Vestibular Approach. *JAMA surgery*, 153(1), 21–27. <https://doi.org/10.1001/jamasurg.2017.3366>