



SUCCESSFUL HOMEOPATHIC TREATMENT OF "PILONIDAL SINUS OF TAILBONE" A COMPLEX SURGICAL DISEASE

Homeopathy

Dr. Vikas Singhal Homeo Saga Pvt. Ltd., Chandigarh, India.

ABSTRACT

Pilonidal sinus also refers as nest of hairs or Jeep-bottom or pilonidal cysts is an infection that arises underneath the skin near the tailbone. Pilonidal Sinus is a provocative condition involving hairs from the adjoining skin perceive the natal cleft, triggering a unfamiliar body response and leading to the creation of a sinus tract. In this paper we have presented a case study of successful treatment of pilonidal sinus of tailbone using homeopathy.

KEYWORDS

Pilonidal sinus, tailbone, homeopathy, skin, natal cleft, nest of hairs, Jeep-bottom, pilonidal cysts, Recommended Diet Plan etc....

INTRODUCTION:

Pilonidal sinus is quite a hurting situation that can occur on anybody. It is especially common in adults and people who belong to the age group of above 40 years. In this condition, a cyst-like structure develops just near the tailbone and causes a lot of discomforts.

Pilonidal Sinus is a provocative condition involving hairs from the adjoining skin perceive the natal cleft, triggering a unfamiliar body response and leading to the creation of a sinus tract. Men are 2.2 times more likely than women to suffer from pilonidal illness, which is projected to effect 26 out of 100,000 individuals.

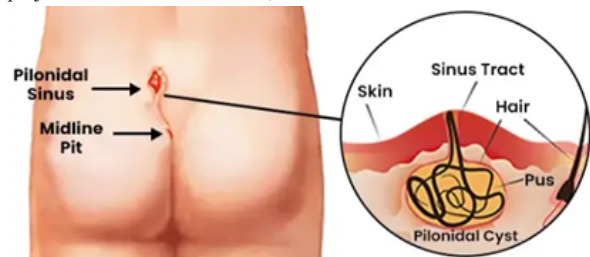


Image Of Pilonidal Sinus Of Tailbone

Symptoms Of Pilonidal Sinus Of Tailbone:

- A tiny pit or indentation in the skin, normally in the crease of the backside.
- Discomfort, painfulness, and bulging.
- A uncomfortable, pus-filled pustule that may unexpectedly grow.
- Pus or blood bleeding from an opening in the skin.
- Pain that deteriorates after be seated for a prolonged time.
- Fever.

Cause Of Pilonidal Sinus Of Tailbone:

- Wobbly hairs that develop set in in the skin
- Be seated for prolonged intervals, can force hair interested in the skin
- Excess Body Hair
- Genetic Predisposition
- Poor Hygiene
- Obesity

Homeopathic Treatment Of Pilonidal Sinus Of Tailbone:

Homeopathy is based on the theory of SIMILIA SIMILIBUS CURENTUR (TREATING LIKE WITH LIKE). Homeopathic do not take care of just the disease, but is prescribed on the base of physical, emotional and genetic condition of a person. Homeopathy do not take care of just only the disease condition but similimum medicine is prescribed on the basis of physical and emotional symptoms as well as the constitution of the patient.

Homeopathic medical science was totally unexplored and no microscope or any other sophisticated instruments could check the depth of this wonderful science. Doctor HAHNEMANN founder of homeopathy already told that and further James Tyler Kent and doctor H.C. Allen and Dr H.A. Roberts in his book "The Principles and art of cure by homeopathy" has already mentioned that this medical science homeopathy is totally unfathomable and gradually with the evolution of science scientist will prove and the time machine will tell it's efficacy and effectiveness.

Case Study:

Gender: Male

Age: 24 years

Case Description:

History Of Case:

Patients aged 24 years by profession a software engineer visited us on 5th of August 2025 for the treatment of Pilonidal sinus. for which he has undergone surgery two times in the year 2024 as well as in the year 2025. However, the problem persists and the condition was reappeared His sinus was still draining out pus continuously with lot of pain.

After few days of second surgery, patient visited out Dr Singhal homeo clinic. The patient's medical history was examined and his reports where studied. A through physical and mental examination of the patient was carried out.

Examination Of The Patient During First Consultation:

After studying the patients' medical history , we found that the symptoms of sinus originated after Covid-19 vaccination in the year 2021 and it got worsen after taking the booster vaccination of covid -19 in the year 2025.

Recommendations And Prescription:

Once the causes of Sinus were established the patient was prescribed Thuja 10M Once a day for 7 days based on origination of symptoms and was observed that within a week of taking prescribed medicines the patient got lot relief in his condition.

Recommended Diet Plan:

- Protein rich diet
- Probiotic-rich foods
- Zinc-rich foods
- High-fibre foods
- Vitamin-rich foods
- Anti-inflammatory foods
- Healthy fats rich diet.
- Keep body hydrated by drinking lot of water.

After 7 days, re-examination of patients physical condition was carried out and one more medicine was added i.e. calcarea silicata 30 in the prescription for next 30 days.

After 30 days we have observed that the condition of patient was around 60% cured and the medices prescribed was continued for next 30 days.

During the examination and follow up after 60 days it was observed that the patient got fully recovered from the pilonidal sinus of tailbone.

Present Status:

The patient got fully recovered from his condition and there was no symptoms of reoccurrence.

CONCLUSION:

From this case study we have gathered the sufficient evidence that the Homoeopathic medicine shows excellent results in the treatment of pilonidal sinus of tailbone. Homeopathic treatment further reduce any chances of complications when prescribed by the homeopathic physicians.

REFERENCES:

1. Pilonidal sinus disease: MedlinePlus Medical Encyclopedia. Available from: <https://medlineplus.gov/ency/article/003253.html>
2. Isik A, Idiz O, Firat D. Novel approaches in pilonidal sinus treatment. *Prague Med Rep.* 2016;117(3):145- 152
3. Humphries AE, Duncan JE. Evaluation and management of pilonidal disease. *Surg Clin North Am.* 2010;90(1):113-124.
4. Søndena K, Andersen E, Nesvik I, Søreide JA. Patient characteristics and symptoms in chronic pilonidal sinus disease *Int J Colorectal Dis.* 1995;10:39–42.
5. Reilly D, Mercer SW, Bikker AP, Harrison T. Outcome related to impact on daily living: Preliminary validation of the ORIDL instrument *BMC Health Serv Res.* 2007;7:139.
6. Pyon RE, Mazumder A, Almajali F, Wong S., Chronic Pilonidal Cyst with Malignant Transformation: A Case Report and Literature Review., *Cureus.* 2022 Mar 17;14(3):e23248. doi: 10.7759/cureus.23248. eCollection 2022 Mar.
7. Khanna A, Rombeau JL. Pilonidal disease *Clin Colon Rectal Surg.* 2011;24:46–53.
8. Harrison's Principal of Internal Medicines 17th Edition Davidsons Principal & practice of Medicines J.T.KENT, REPERTORY Of Homoeopathic M.M.
9. Dr. S. K. Dubey, Text Book Of Material Medica
10. DR. N.M. CHOUDHARI, A Study On Materia Medica.
11. DR. WILLIAM BOERICKE, Pocket Manual Of Homoeopathic Materia Medica & Repertory.
12. DR. H.C. ALLEN Keynotes & Characteristics With Comparisons Of Some Leading Remedies of The Materia Medica With Bowel Nosodes, 8th Edition.
13. DR. PAMEETA UNİYAL, Materia Medica For Students.
14. DR. RITU KINRA, Materia Medica For Students.
15. Davidsons's principles and practice of medicine, 24th edition.
16. Hamilton Bailey's, Physical signs. 5th edition.