



## A COMPARATIVE STUDY BETWEEN THE ROLE OF LATERAL ANAL SPHINCTEROTOMY AND LORD'S MAXIMAL ANAL DILATATION IN REDUCING POSTOPERATIVE PAIN AFTER OPEN HEMORRHOIDECTOMY

### Surgery

<b>Dr Somdeep Pattanaik</b>	Junior Resident, Department of General Surgery, Hi-tech Medical College and Hospital, Bhubaneswar
<b>Dr Biswaranjan Mohapatra</b>	Associate Professor, Department of General Surgery, Hi-tech Medical College and Hospital, Bhubaneswar
<b>Dr Laxmikant Sahoo*</b>	Resident, Department of General Surgery, Hi-tech Medical College and Hospital, Bhubaneswar *Corresponding Author
<b>Dr. Jyotiprakash Biswal</b>	Senior Resident, Department of General Surgery, SCB Medical College Cuttack.

### ABSTRACT

**Background:** Hemorrhoidectomy remains a standard surgical treatment for advanced hemorrhoids, often associated with significant postoperative pain. This study compares the effectiveness of Lateral Anal Sphincterotomy (LAS) and Maximal Anal Dilatation (MAD) in reducing post-hemorrhoidectomy pain. **Methods:** A prospective, randomized comparative study was conducted on 50 patients with Grade II-IV hemorrhoids undergoing open hemorrhoidectomy. Patients were divided into two groups: Group A (n=25) underwent LAS, and Group B (n=25) underwent MAD. Postoperative pain was assessed using the Wong-Baker Faces Pain Scale and objective analgesic requirements. Sphincter tone was evaluated on postoperative day (POD) 7. **Results:** The mean age of participants was  $36.32 \pm 9.11$  years, with a male predominance (72%). Grade III hemorrhoids were most common (72%). Postoperative pain scores were significantly lower in the LAS group compared to the MAD group ( $p < 0.05$ ). Patients in the LAS group required fewer analgesics and demonstrated a lower incidence of sphincter tone abnormalities by POD 7. **Conclusion:** LAS is superior to MAD in reducing postoperative pain following open hemorrhoidectomy, with better sphincter tone preservation. Incorporating LAS may enhance patient recovery and reduce complications.

### KEYWORDS

Hemorrhoidectomy, Lateral Anal Sphincterotomy, Maximal Anal Dilatation, Postoperative Pain, Sphincter Tone

### INTRODUCTION

Hemorrhoids are a prevalent anorectal condition, often necessitating surgical intervention for advanced grades. Open hemorrhoidectomy, though effective, is associated with considerable postoperative pain. Various adjunct procedures aim to mitigate this pain, including LAS and MAD. This study evaluates their efficacy in pain reduction and postoperative outcomes.

Hemorrhoids are vascular structures in the anal canal that become pathologically enlarged, inflamed, and symptomatic due to increased intra-abdominal pressure, straining, and vascular congestion. They are classified as:

- Internal Hemorrhoids: Located above the dentate line, painless but cause bleeding.
- External Hemorrhoids: Located below the dentate line, painful and often thrombosed.

Surgical removal (Milligan-Morgan hemorrhoidectomy) is the gold standard for grade III and IV hemorrhoids, but postoperative pain is a major concern. High internal sphincter tone contributes to pain, and techniques like Lateral Anal Sphincterotomy (LAS) and Maximal Anal Dilatation (MAD) are used to relieve it.

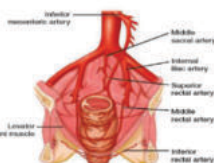
This study aims to compare LAS and MAD in reducing postoperative pain and preserving sphincter tone after open hemorrhoidectomy.

### Anatomy of the Anal Canal and Hemorrhoids

The anal canal extends from the rectum to the anus, surrounded by internal and external anal sphincters. It is lined by:

- Columnar epithelium above the dentate line (internal hemorrhoids).
- Stratified squamous epithelium below the dentate line (external hemorrhoids).

### Vascular Supply



- Superior rectal artery (branch of IMA).
- Middle & Inferior rectal arteries (branches of internal iliac artery).

### Venous Drainage:

Internal hemorrhoidal plexus → portal circulation.  
External hemorrhoidal plexus → systemic circulation.

### Lymphatic Drainage

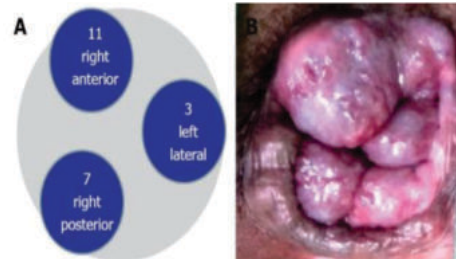
Above dentate line → Internal iliac nodes.  
Below dentate line → Superficial inguinal nodes.

### Nerve Supply:

Above dentate line → Autonomic nerves (visceral pain, less sensitive).  
Below dentate line → Somatic nerves (highly sensitive to pain, touch, temperature).

### Pathophysiology of Hemorrhoids

Hemorrhoids develop due to:  
Increased venous pressure → vascular congestion & dilation.  
Weakening of connective tissue → prolapse.  
Inflammation & thrombosis → pain, bleeding, itching.

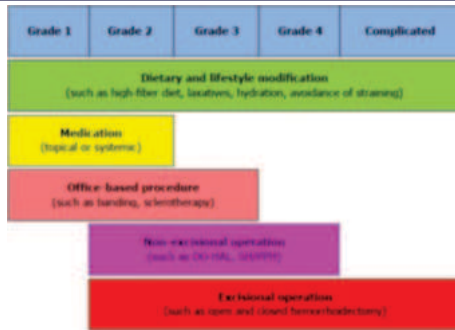


### Risk Factors:

Chronic constipation and straining.  
Prolonged sitting, obesity, pregnancy.  
Low-fiber diet, heavy lifting.

### Management :

The current approach to managing internal hemorrhoids considers their severity and prolapse grade. The image below illustrates the treatment options for various grades of hemorrhoids.



**Methods**

**Study Design:** Prospective, randomized comparative study.

**Participants:** 50 patients diagnosed with Grade II-IV hemorrhoids requiring surgery.

**Inclusion Criteria:** Patients aged 18-50 years with clinically confirmed Grade II (refractory to medical treatment), Grade III, or Grade IV hemorrhoids.

**Exclusion Criteria:** Patients with other anorectal pathologies, systemic conditions affecting wound healing, or unwillingness to participate.

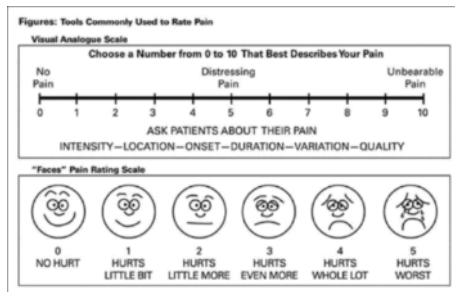
**Procedure:** All patients underwent Milligan-Morgan hemorrhoidectomy under spinal anesthesia.

Patients were randomly divided into:

- Group A (LAS, n=25) → Internal sphincterotomy after hemorrhoidectomy.
- Group B (MAD, n=25) → Maximal anal dilatation after hemorrhoidectomy.

**Outcome Measures:**

- Postoperative pain scores (Wong-Baker Faces Pain Scale)



- Analgesic requirements
- Sphincter tone assessment on POD 7

**Statistical Analysis**

Data were analyzed using one-way ANOVA, with significance set at p<0.05.

**RESULTS**

**Demographics:**

- Mean age: 36.32 ± 9.11 years
- Male predominance: 72%
- Grade III hemorrhoids: 72%

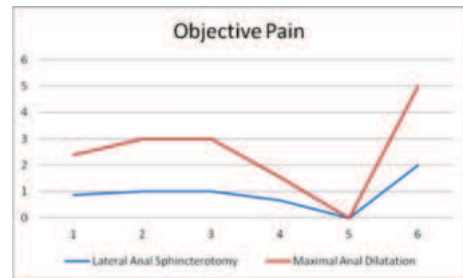
**Postoperative Pain:**

- Scoring and comparison of pain between two groups
- The tables and figures provided illustrate the pain comparison between the two groups. The analysis using one-way ANOVA reveals superior pain management with Lateral Anal Sphincterotomy compared to the group that underwent maximal anal dilatation. The ANOVA yielded significant results, indicating an F-value of 60.293, and a highly significant p-value.

**Table 6: Objective Pain**

Objective Pain	Lateral Anal Sphincterotomy	Maximal Anal Dilatation
Mean	.88	1.52
Median	1.00	2.00
Mode	1	2
Std. Deviation	.666	.872

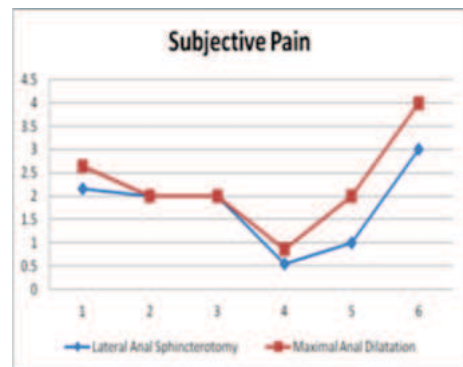
Minimum	0	0
Maximum	2	3



**Figure 6: Objective Pain**

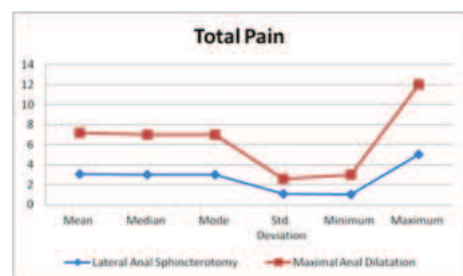
**Table 7: Subjective Pain**

Subjective Pain	Lateral Anal Sphincterotomy	Maximal Anal Dilatation
Mean	2.16	2.64
Median	2.00	2.00
Mode	2	2
Std. Deviation	.554	.860
Minimum	1	2
Maximum	3	4



**Figure 7: Subjective Pain**

Total Pain	Lateral Anal Sphincterotomy	Maximal Anal Dilatation
Mean	3.04	4.16
Median	3.00	4.00
Mode	3	4
Std. Deviation	1.060	1.546
Minimum	1	2
Maximum	5	7



**Figure 8: Total Pain**

**One-way ANOVA for Comparison of Pain Between the Two Groups**

- Lateral Anal Sphincterotomy demonstrated superior pain management compared to maximal anal dilatation, as indicated by the significant findings of the one-way ANOVA with an F-value of 60.293 and a highly significant p-value

**Table 9: One-way ANOVA for Comparison of Pain Between the Two Groups**

ANOVA	Sum of Squares	df	Mean Square	F	Sig
-------	----------------	----	-------------	---	-----

Between Groups	79.725	3	26.575	60.293	.000
Within Groups	20.275	46	.441		<0.005
Total	100.000	49			Highly Significant

- Mean total pain score: 3.04 (LAS) vs. 4.16 (MAD) ( $p < 0.05$ )
- LAS group required fewer analgesics

#### Sphincter Tone:

- Normal tone on POD 7: 66% (LAS) vs. 50% (MAD)
- High tone incidence: 18% (MAD) vs. 12% (LAS)

#### DISCUSSION

The summary of the results are as follows:

1. Hemorrhoids is a common problem of the age group between 30 and 40 years of age
2. Majority of the study population was male ( $n=36$ , 72%) and the rest were females ( $n=14$ , 28%)
3. Haemorrhoids presented to the OPD mostly as Grade III
4. Both LAS and MAD were done on equal number of subjects i.e. 25.
5. A One-Way ANOVA test was utilized to assess the correlation between Lateral Anal Sphincterotomy and postoperative pain, measured as a combined score of objective and subjective pain scores. The analysis affirmed superior pain management with LAS, demonstrating a significant ANOVA result with an F-value of 60.293 and an exceptionally significant p-value.
6. Sphincter tone was evaluated at the conclusion of Postoperative Day 7. A significant proportion of patients who received LAS reverted to a normal sphincter tone by the end of POD 7. Conversely, there was a notable occurrence of patients with elevated anal tone in the MAD group.

#### Literature Review

Prior studies, including those by

**Kanellos et al.:** LAS reduces pain post-hemorrhoidectomy ( $p < 0.05$ ).

**Medina-Gallardo et al.:** LAS improves outcomes without incontinence.

**Gennaro et al.:** LAS prevents stenosis and reduces pain.

Additionally, randomized controlled trials indicate that LAS is more effective in minimizing pain and sphincter dysfunction compared to MAD.

#### CONCLUSION

LAS is a superior adjunct to open hemorrhoidectomy compared to MAD, offering significant pain relief and better postoperative sphincter function. Its routine incorporation could enhance patient outcomes and recovery.

#### REFERENCES

1. Thomson WH. The nature and cause of hemorrhoids. Proc R Soc Med. 1975;68(9):574-5.
2. Loder PB, Kamm MA, Nicholls RJ, Phillips RK. Hemorrhoids: Pathology, pathophysiology, and etiology. Br J Surg. 1994;81(7):946-54.
3. Wang W-G, Lu W-Z, Yang C-M, Yu K-Q, He H-B. Effect of lateral internal sphincterotomy in patients undergoing excisional hemorrhoidectomy. Medicine (Baltimore). 2018;97(32):e11820.
4. Lohsiriwat V. Hemorrhoids: from basic pathophysiology to clinical management. World J Gastroenterol [Internet]. 2012 May 7 [cited 2018 Oct 24];18(17):2009-17. Available from: <http://www.ncbi.nlm.nih.gov/pubmed/22563187>
5. Hemorrhoids - Symptoms and causes - Mayo Clinic [Internet]. [cited 2018 Oct 24]. Available from: <https://www.mayoclinic.org/diseasesconditions/hemorrhoids/symptoms-causes/syc-20360268>
6. Hemorrhoid.net - Surgical Treatment Options for Hemorrhoids [Internet]. [cited 2018 Oct 25]. Available from: <http://www.hemorrhoid.net/surgery.php>
7. Agbo SP. Surgical management of hemorrhoids. J Surg Tech Case Rep [Internet]. 2011 Jul [cited 2018 Oct 25];3(2):68-75. Available from: <http://www.ncbi.nlm.nih.gov/pubmed/22413048>
8. Hemorrhoidectomy open - Surgernote [Internet]. [cited 2018 Oct 25]. Available from: <https://sites.google.com/site/surgernote/hemorrhoidectomy-open>.
9. Junior HM. Open haemorrhoidectomy with associated lateral internal sphincterotomy for treatment of haemorrhoids: advantage or disadvantage? Rev Bras Coloproctol [Internet]. 2007 [cited 2018 Oct 25];27(3):293-303. Available from: [https://www.researchgate.net/publication/262503919\\_Open\\_haemorrhoidectomy\\_with\\_associated\\_lateral\\_internal\\_sphincterotomy\\_for\\_treatment\\_of\\_haemorrhoids\\_advantage\\_or\\_disadvantage](https://www.researchgate.net/publication/262503919_Open_haemorrhoidectomy_with_associated_lateral_internal_sphincterotomy_for_treatment_of_haemorrhoids_advantage_or_disadvantage).
10. Gennaro Galizia, Eva Lieto, Paolo Castellano, Luigi Pelosio VI & CP. Lateral Internal Sphincterotomy Together with Haemorrhoidectomy for Treatment of Haemorrhoids: a Randomised Prospective Study. Eur J Surg [Internet]. 2001 [cited 2018 Oct 28];166(3):223-8. Available from: <https://www.tandfonline.com/action/showCitFormats?doi=10.3109%2F110241500750009320>.
11. Lewis AA, Rogers HS, Leighton M. Trial of maximal anal dilatation, cryotherapy and elastic band ligation as alternatives to haemorrhoidectomy in the treatment of large prolapsing haemorrhoids. Br J Surg [Internet]. 1983 Jan [cited 2018 Oct 27];70(1):54-6. Available from: <http://www.ncbi.nlm.nih.gov/pubmed/6337671>.
12. Chauhan A, Tiwari S, Mishra VK, Bhatia PK. Comparison of internal sphincterotomy with topical diltiazem for post-hemorrhoidectomy pain relief: a prospective randomized trial. J Postgrad Med [Internet]. 2009 [cited 2018 Oct 28];55(1):22-6. Available from:

<http://www.ncbi.nlm.nih.gov/pubmed/19242074>.

13. Singh B, Box B, Lindsey I, George B, Mortensen N, Cunningham C. Botulinum toxin reduces anal spasm but has no effect on pain after haemorrhoidectomy. Color Dis [Internet]. 2009 Feb 1 [cited 2018 Oct 27];11(2):203-7. Available from: <http://doi.wiley.com/10.1111/j.1463-791318.2008.01549.x>
14. Carlsson AM. Assessment of Chronic Pain. I. Aspects of the Reliability and Validity of the Visual Analogue Scale [Internet]. Vol. 16, Pain. Elsevier Biomedical Press; 1983 [cited 2018 Oct 25]. Available from: [https://s3.amazonaws.com/academia.edu.documents/35798140/Assesme nt\\_of\\_Chronic\\_Pain\\_Aspects\\_of\\_the.pdf? AWS AccessKeyId=AKIAIWO](https://s3.amazonaws.com/academia.edu.documents/35798140/Assesme nt_of_Chronic_Pain_Aspects_of_the.pdf? AWS AccessKeyId=AKIAIWO)