



## LANDZERT HERNIA : CASE REPORT WITH REVIEW OF LITERATURE

## General Surgery

**Dr. Paresh Sharma\***

Resident, General Surgery, Mahatma Gandhi Hospital, Jaipur \*Corresponding Author

**Dr. Soham Solanki**

Resident, General Surgery, Mahatma Gandhi Hospital, Jaipur

**Dr. Arshiya Gupta**

Resident, General Surgery, Mahatma Gandhi Hospital, Jaipur

**Dr. Madhur Arora**

Resident, General Surgery, Mahatma Gandhi Hospital, Jaipur

**Dr. Ajay Sharma**

Professor And Head, Gastro-Surgery Department, Mahatma Gandhi Hospital, Jaipur

## ABSTRACT

Paraduodenal hernias (PDH) are rare congenital anomalies caused by embryonic peritoneal defects and abnormal intestinal rotation. These hernias often present with nonspecific symptoms, including abdominal pain and intestinal obstruction, posing diagnostic challenges. A case of left-sided PDH in a 41-year-old patient is discussed, highlighting symptoms of abdominal distension and bowel obstruction. Diagnosis was confirmed via CT imaging, showing characteristic clustered bowel loops and mesenteric vessel displacement. Surgical management involved open reduction of the hernia sac, jejunal loop decompression, and anatomical repair, with excellent postoperative recovery. While open surgery has been the traditional approach, laparoscopic techniques are emerging as the preferred method, offering reduced recovery time and complications. Early diagnosis and timely intervention are crucial to prevent life-threatening complications like strangulation. Continued research and larger studies are necessary to refine laparoscopic techniques and establish optimal management protocols for this underreported condition.

## KEYWORDS

Paraduodenal hernia, intestinal obstruction, laparoscopic surgery, congenital anomaly

## INTRODUCTION

Paraduodenal hernias (PDH), also known as mesocolic hernias, are rare congenital anomalies resulting from embryonic peritoneal defects and abnormal intestinal rotation. These defects create potential spaces where bowel loops can herniate, leading to chronic or acute symptoms<sup>[1,2]</sup>. While they are uncommon, PDH accounts for the majority of internal hernias, often presenting with nonspecific symptoms such as chronic abdominal pain, vomiting, and occasional intestinal obstruction. The significant risk of strangulation and intestinal infarction, with mortality rates ranging from 20% to 50% in acute presentations, underscores the importance of early diagnosis and timely intervention.

## Case Study

A 41-year-old patient presented to the emergency surgical department of Mahatma Gandhi Hospital on December 4, 2024, with complaints of abdominal distension and inability to pass flatus or motion for the past three days. The abdominal distension was sudden in onset, generalized, and non-progressive, with prominence in the supra umbilical and epigastric regions. Despite conservative management in a local district hospital, which included Ryle's tube and Foley catheter insertion three days earlier, there was no relief.

## History And Examination :

## • Presenting Complaints:

- Abdominal distension for three days.
- Inability to pass flatus or motion.
- No vomiting or fever.

## • Past History:

- No significant medical or surgical history.
- No comorbidities or chronic illnesses.
- No ICU admissions or previous similar episodes.

- **Social History:** Non-smoker, occasional alcohol consumption, no drug allergies.

- **Medications:** Pantoprazole 40 mg once daily, ibuprofen as needed.

## • Examination Findings:

**General Condition:** Conscious, oriented, eupneic.

- **Vitals:** Blood pressure 140/80 mmHg bilaterally, Pulse : 98 beats per minute

**SpO2:** 94 % on room air

## • Systemic Examination :

**Cardiovascular System:** Rhythmic heart sounds, no murmurs.

**Respiratory System:** Normal Breath sounds heard bilaterally

**Abdomen:** Meteoric and distended, prominent distension in epigastric and supra umbilical regions.

Generalised tenderness to deep palpation, guarding present, no rebound tenderness or organomegaly.

**Per rectal examination:** Normal anal tone, no mass palpable, normal-coloured stool on glove.

**Limbs:** No oedema, normal peripheral pulses.

## • Investigations

**Laboratory Findings:** Leukocytosis ( $12 \times 10^9/L$ ).

**X-Ray (Day 1):** Gaseously distended bowel loops in the central abdomen.

Fecal loading in the colon.

No free air beneath the diaphragm.

No significant air-fluid levels. (Figure .1)

**Ultrasound:** Normal liver, biliary system, pancreas, spleen, kidneys, bladder, and prostate.

No free fluid in the abdomen or pelvis. Dilated small bowel loops with sluggish peristalsis suggestive of bowel obstruction.

## CT Scan (Day 2):

Cluster of non-dilated proximal and mid-jejunal loops with congested mesentery in the left upper quadrant anterior to the left kidney.

Inferior mesenteric vein passing anterior to the hernial sac. Findings suggestive of a left-sided paraduodenal internal hernia.

## • Management

## Preoperative Care:

Patient underwent preoperative preparation and was placed under general anesthesia.

## • Surgical Procedure:

(Figure 3) Upper midline laparotomy performed.

**Findings:**

Serous effusion in the abdominal cavity. A peritoneal sac containing the proximal third of the jejunum twisted inside, located left of the fourth duodenum segment and duodenojejunal junction. Distended loops of the small intestine observed.

**Intervention:**

Hernia sac opened and resected. Decompressed trapped jejunal loops with maintained vitality (normal colour and motility).

Inspection of other abdominal structures revealed no additional pathology.

Abdominal cavity rinsed with warm saline, followed by drainage and wound closure.

**Postoperative Course**

**Immediate Recovery:** Uneventful.

**Diet and Therapy:** Semi-solid diet resumed 6 hours postoperatively. Analgesic therapy provided as needed.

**Discharge:**

Discharged on postoperative day 3 in good general and local status. Wound healed primarily; sutures removed on day 8.

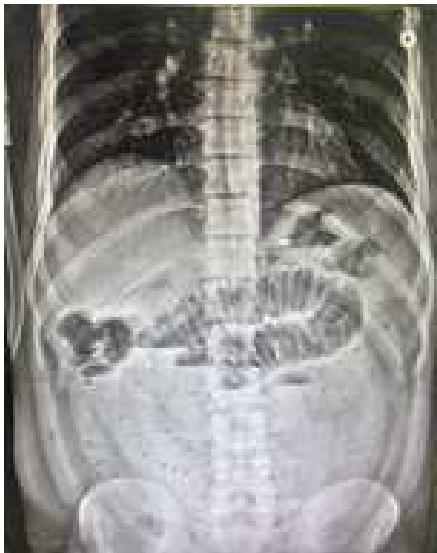**Follow-Up**

Weekly clinical examinations during the first month post-discharge, followed by monthly reviews.

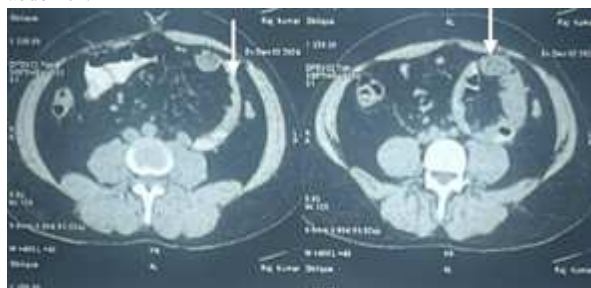The patient remained in good clinical condition without complaints during follow-up.

**Consent**

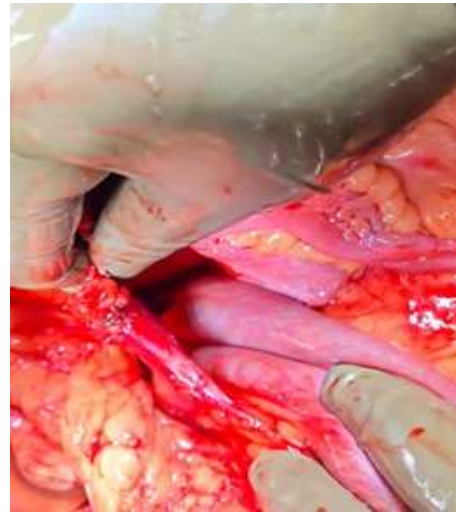
Written informed consent was obtained from the patient for the publication of this case report and accompanying images. A copy of the written consent is available for review by the Editor-in-Chief of this journal upon request.



**Figure 1:** X-Ray FPA : Gaseously distended bowel loops in the central abdomen.



**Figure 2 :** CT Abdomen : Cluster of non-dilated proximal and mid-jejunal loops with congested mesentery in the left upper quadrant anterior to the left kidney.



**Figure 3:** Intra Operative finding: herniating healthy bowel loops from defect in mesocolon

**Review of Literature**

**Diagnosis**

Computed tomography (CT) is considered the gold standard for diagnosing PDH. CT findings typically include clustered, dilated bowel segments and displaced mesenteric vessels at the hernial orifice. Despite the utility of imaging, diagnosis can be challenging in asymptomatic or chronic cases, with definitive confirmation often occurring intraoperatively. Early identification is crucial to avoid complications such as bowel strangulation or infarction.

**Surgical Management**

Surgical intervention remains the definitive treatment for PDH, with the primary goals being to reduce the hernia, restore normal anatomy, and repair the defect. Timely surgery is essential due to the high lifetime risk of incarceration or strangulation, which is estimated at 50%.

**Open Surgery**

Historically, open surgery has been the standard approach for managing PDH. While effective, it is associated with longer recovery times and a higher likelihood of postoperative complications compared to minimally invasive techniques.

**Laparoscopic Surgery**

Laparoscopic surgery has emerged as the preferred approach for PDH repair due to several advantages, including reduced postoperative pain, faster recovery, shorter hospital stays, and lower rates of postoperative ileus. Successful laparoscopic repairs have been reported for both right- and left-sided PDH. However, left-sided PDH surgeries require particular care to avoid damage to the left colic artery or inferior mesenteric vessels, which are often located near the hernial orifice.

A recent small case series comparing laparoscopic and open PDH repairs demonstrated favourable outcomes with the laparoscopic approach, including earlier resumption of a soft diet and shorter hospital stays<sup>(3)</sup> Despite these promising results, larger studies are needed to validate these findings and establish robust management protocols.

**Prognosis And Outcomes**

Advancements in imaging and surgical techniques have significantly improved the prognosis for patients with PDH. Early diagnosis and intervention reduce the risk of severe complications, while minimally invasive approaches have further enhanced postoperative outcomes. Nonetheless, the condition remains underreported, and continued research is necessary to refine diagnostic and therapeutic strategies.

**CONCLUSIONS :**

Paraduodenal hernias pose a significant diagnostic and therapeutic challenge due to their rarity and nonspecific clinical presentation. While CT imaging has improved preoperative diagnosis, definitive confirmation often occurs during surgery. Laparoscopic repair offers

substantial benefits and is becoming the preferred treatment modality, though its application requires surgical expertise and careful consideration of anatomical structures. Further large-scale studies are essential to solidify the role of minimally invasive techniques and optimise management guidelines for this rare but potentially life-threatening condition.

**REFERENCES:**

- [1] M.A. Khan, A.Y. Lo, D.M. Vande Maele, Paraduodenal hernia, *Am. Surg.* 64 (1998) 1218–1222.
- [2] I. Okan, O.V. Ozkan, M. Sahin, G. Bas, O. Alimoglu, Left paraduodenal hernia diagnosed preoperatively, *ANZ J Surg.* 80 (2010) 116, <https://doi.org/10.1111/j.1445-2197.2009.05191.x>.
- [3] G.G. Ghahremani, Internal abdominal hernias, *Surg. Clin. North Am.* 64 (1984) 393–406.