



A STUDY ON EFFICACY OF PLATELET RICH PLASMA IN TYMPANOPLASTY AND MYRINGOPLASTY

Otorhinolaryngology

Dr Diksha Singh Baghel	Post Graduate Student In Department Of ENT And Head And Neck Surgery, Gandhi Medical College, Bhopal M.P.
Dr. Yashveer JK	Associate Professor And Head, Department Of ENT And Head And Neck Surgery, Gandhi Medical College, Bhopal M.P.
Dr. Smita Soni	Professor And Head, Department Of ENT And Head And Neck Surgery, Gandhi Medical College, Bhopal M.P.
Dr. Barkha Singh	Post Graduate Student In Department Of ENT And Head And Neck Surgery, Gandhi Medical College, Bhopal M.P.

ABSTRACT

Aims-To evaluate the Graft take up, bone conduction and complications in patients with inactive mucosal type of chronic otitis media disease. **Material And Methods-** The study was conducted as prospective study on patients with chronic otitis media with having central perforation in pars tensa with dry middle ear cavity, presenting to the Department of Otorhinolaryngology, Hamidia Hospital, Bhopal for tympanoplasty and myringoplasty, during the study period of 18 months. Myringoplasty or tympanoplasty was done by a single senior surgeon and PRP was prepared at the time of placing graft. All the patients were followed up at 1 month, 2 month and 3 month after surgery and were observed for closure and healing of tympanic membrane using otoscopy. At each follow up, pure tone audiometry was also done and findings were documented. **Results-** We found graft uptake in 90.9%, 98.2% and 98.2% cases at 1 month, 2 month and 3 months respectively. Mean time for graft uptake was 25.44±3.71 days. Overall PTA and ABG improved over the period of 3 months ($p < 0.05$). We observed graft displacement in 1 case (1.8%). Complications in the form of discharge and residual perforation was noted in 1 case (1.8%). **Conclusions-** Use of platelet rich plasma in type I tympanoplasty improve the graft uptake rate and promote fast recovery and reduce the risk of graft displacement. Due to presence of various growth factors, PRP aid in closure of tympanic membrane and improve the audiological outcome in terms of pure tone audiograms and air bone gap.

KEYWORDS

PRP, myringoplasty, perforation, inactive CSOM, graft uptake.

INTRODUCTION

Perforation of tympanic membrane is one of the common condition associated with hearing loss, for which patients seeks care in Department of Otorhinolaryngology[1]. Perforated tympanic membrane is not able to perform the normal function and may lead to hearing loss[2,3]. Depending upon the duration of perforation, they are typically categorized as acute and chronic perforation. Acute perforations have tendency to heal spontaneously whereas chronic perforation is managed by surgical procedure. The perforation of tympanic membrane could be due to infection (repeated attacks of acute otitis media causing chronic suppurative otitis media, Aspergillus niger associated otitis externa), direct trauma to tympanic membrane (by inserting object or iatrogenic), barotrauma (due to scuba diving, sudden negative pressure, air travel) noise induced trauma, or head trauma. Amongst these, trauma and acute otitis media are most common cause of perforations [2].

Tympanoplasty and myringoplasty are surgical procedure for repair of perforated tympanic membrane, which may be performed along with ossicular reconstruction (ossiculoplasty) so as to prevent the reinfection as well as to restore hearing[4]. Wullstein and Zollner in 1950 popularized the technique of tympanoplasty using the overlay graft for reconstruction of perforated tympanic membrane[5]. As per Wullstein Classification, 5 types of tympanoplasties have been classified. Type I tympanoplasty is done when only tympanic membrane is perforated and middle ear is normal. This technique is also termed as myringoplasty and in this technique only tympanic membrane repair is done[6].

The graft material used for reconstruction of tympanic membrane is an important determinant of success of myringoplasty and tympanoplasty [7]. The use of autologous graft, mainly temporalis fascia is the gold standard method for repair of tympanic membrane perforation. Other commonly used autologous graft materials are tragal/ conchal perichondrium, fascia lata, periosteum and canal skin. The advantages of these autologous grafts are they are readily available, inexpensive and biocompatible[4]. Alloplastic grafts such as absorbable gelatin sponge and acellular dermal matrix have also been used. Though, they are associated with less morbidity and improved cosmetic outcome, but they are costly and may be associated with risk of transmitting infectious diseases. Thus autologous grafts are commonly preferred as

compared to alloplastic grafts.

Recently, the growth factors have been used for augmenting the healing of perforated tympanic membrane[8]. Platelet-rich plasma (PRP) is an autologous product, which have been derived from one's own blood by the process of gradient density centrifugation. The following seven growth factors are found in high concentrations in platelet-rich plasma (PRP) as compared to whole blood, namely, transforming growth factor β , platelet-derived growth factor, platelet-derived epidermal growth factor, insulin-like growth factor 1, vascular endothelial growth factor, fibroblast growth factor, and epidermal growth factor. These GFs are known to modulate the proliferation of various tissues and promote wound healing[8]. Its first use in clinical settings was demonstrated by Ferrari et al in mid 1980 in open heart surgery and since then it has been used effectively in many surgical procedures[9]. In animal studies, Erkilet et al demonstrated the utility of autologous PRP in accelerated healing of tympanic membrane in rats[10].

The activated proteins of PRP act by binding to transmembrane receptors of the target cells, thereby activating the intracellular signal proteins, leading to expression of gene sequence responsible for osteoid production, cellular proliferation, and collagen synthesis, thus promoting tissue repair[11]. The advantages associated with the use of PRP include less risk of immunological reaction and transmission of infections, rapid healing, less risk of graft rejection[12]. PRP was classified into four main types by Dohan et al. based upon the fibrin architecture and cellular content. The four types of PRP are Pure Platelet Rich Plasma (P-PRP), Leucocyte-PRP (L-PRP), Pure Platelet-Rich Fibrin (P-PRF) and Leucocyte-PRF (L-PRF). Pure Platelet Rich Plasma (P-PRP) is preparation with a low-density fibrin network after activation. Leucocyte-PRP (L-PRP) products are preparations with leucocytes and with a low-density fibrin network after activation. Pure Platelet-Rich Fibrin (P-PRF) is a high-density fibrin network. The Leucocyte-PRF (L-PRF) or second-generation PRP products are preparations with leucocytes and with a high-density fibrin network[13].

With the above background, the present study was done to evaluate the use of activated platelet rich plasma placed on both side of temporalis fascia graft in patients with inactive mucosal type of chronic otitis

media disease. In post operative period we assessed the Graft take up, bone conduction and incidence of secondary perforation.

METHODS

The present study was conducted as an prospective study on patients with chronic otitis media with having central perforation in pars tensa with dry middle ear cavity, presenting to the Department of Otorhinolaryngology, Gandhi Medical College &Hamidia Hospital, Bhopal for tympanoplasty and myringoplasty, during the study period of 18 months i.e. from 1st August 2022 to 30th january 2024. All the patients with central perforation in pars tensa, with dry middle ear cavity and belonging to more than 12 years of age were included whereas patient with Signs of cholesteatoma or ossicular necrosis, marginal perforation and retraction pocket in TM, platelet dysfunction syndrome and low platelet count were excluded from the study.

This observational study was conducted after obtaining ethical clearance from Institute's ethical committee. All the patients satisfying the inclusion criteria were enrolled and written consent was obtained from all of them. Using the proforma, sociodemographic data including patient's name, age, sex, occupation, address etc. was noted. Detailed history regarding clinical complaints along with past medical and surgical history was documented. Apart from this, drug history, family history and persona history was obtained and documented in proforma.

All the patients were then subjected to general and systemic examination and findings were noted. Following this, local examination of both the ears was done. The examination included inspection of pinna, pre auricular region, post auricular region, and external auditory canal. Examination of tympanic membrane was also done and Mastoid tenderness was assessed. Based upon the findings of history and examination, provisional diagnosis was established.

All the cases prior to surgery were subjected to routine blood investigations including coagulation profile and PTA. In every case autologous PRP was prepared freshly in the operation theatre itself using a centrifugation machine. Blood begins to coagulate as soon as it comes in contact with glass surface. Hence, blood was drawn and centrifuged just before PRF/PRP is needed for application to surgical site. For PRP preparation, 5 ml blood was drawn via venipuncture and collected in sterile tubes without anticoagulant. Then blood was centrifuged using low RPM "soft spin" i.e. 15000rpm for 8minutes. The RBCs are seen to be sedimented at the bottom. The supernatant plasma is transferred using a sterile syringe to another sterile tube. The second tube was centrifuged at hard spin i.e. 36000rpm for 5 minutes. This spin leads to sedimentation of all cells which are predominantly platelets. Platelet pellet was seen at the bottom of the tube and overlying Platelet poor plasma (PPP). Upper 2/3rd of PPP was removed and remaining platelet rich fibrin is utilised.




Figure 1 Platelet rich fibrin cut in smaller pieces to be placed on graft

Myringoplasty or tympanoplasty was done by a single senior surgeon at the scheduled date. Myringoplasty/ tympanoplasty was done using the underlay technique and graft material used was temporalis fascia graft. After the graft positioning and repositioning of tympanomeatal flap, freshly prepared PRP was inserted into EAC on the lateral surface of graft and TM remnant. Gel foam were inserted filling the medial part of EAC to support PRP. Thus, PRP were placed on either side of the graft. All the patients were followed up at 1 month, 2 month and 3 month after surgery and were observed for closure and healing of tympanic membrane using otoscopy. At each follow up, pure tone audiometry was also done and findings were documented.

Statistical Analysis

Data was compiled using MsExcel and analysis was done using IBM

SPSS software version 20. Categorical data was expressed as frequency and percentage whereas continuous data was expressed as mean and standard deviation. The improvement in postoperative period was assessed and compared with pre-operative data using chi square test for categorical variables and paired t test or one way ANOVA for continuous variables. P value of less than 0.05 was considered statistically significant.

RESULTS

The present study was conducted on a total of 55 cases with chronic otitis media with central perforation in the pars tensa.

Table 1- Distribution Of Cases According To Baseline Variables

Baseline variables		Frequency (n=55)	Percentage
Age (years)	≤20	4	7.3
	21-30	23	41.8
	31-40	18	32.7
	41-50	7	12.7
	>50	3	5.5
Sex	Male	22	40.0
	Female	33	60.0
Clinical features	Otorrhoea	40	72.7
	Hearing loss	48	87.3
Ear affected	Right	25	45.5
	Left	30	54.5
External auditory canal	Dry	55	100.0
Tympanic membrane	Large central perforation	21	38.2
	Medium central perforation	26	47.3
	Small central perforation	8	14.5

Mean age of patients with chronic otitis media was 32.18±9.69 years and majority of cases belonged to age group of 21 to 30 years (41.8%). We reported slight female predominance for chronic otitis media in our study with female:male ratio of 1.5:1. Most common presenting complaint was hearing loss (87.3%), followed by otorrhoea (72.7%). Left ear was affected in 54.5% cases. Majority of cases had medium central perforation (47.3%) (Table 1). All patients underwent type 1 tympanoplasty and were followed up at 1 month, 2 month and 3 months. We found graft uptake in 90.9%, 98.2% and 98.2% cases at 1 month, 2 month and 3 months follow up respectively (Figure 2). Mean time for graft uptake was 25.44±3.71 days, ranging from 19 days to 36 days.

Figure 2- Distribution of cases according to graft uptake at various follow up

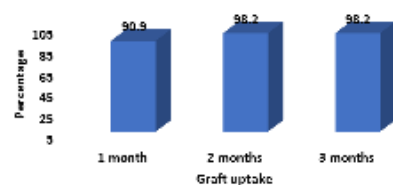
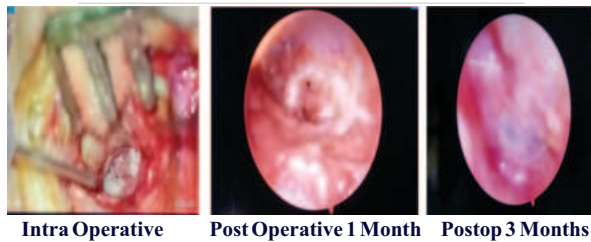
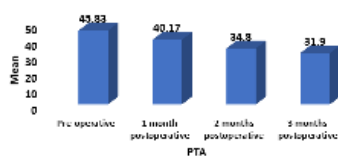Table 2- Improvement in PTA, ABG in cases with COM following surgery

PTA and ABG	Follow up	Mean value		Improvement		P value
		Mean	SD	Mean	SD	
PTA	Pre-operative	45.83	10.4	-	-	0.001
	1 month	40.17	9.44	5.66	3.47	
	2 months	34.8	7.49	11.03	4.91	
	3 months	31.9	6.12	13.87	6.8	
ABG	Pre-operative	28.69	9.30	-	-	0.001
	1 month	24.06	8.25	4.63	2.24	
	2 months	15.52	5.63	13.17	6.21	
	3 months	13.53	4.52	15.15	7.06	

In our study, mean PTA at baseline was 45.83±10.4 dB, which improved to 40.17 at 1 month, 34.8 dB at 2 months and 31.9 dB at 3 months. Overall PTA improved by 13.87±6.8 dB after 3 months. The observed improvement was found to be statistically significant (p<0.05). Mean ABG at baseline was 28.69±9.30, which over the period of 3 months improved to 13.53±4.52 and the observed improvement was found to be statistically significant (p<0.05) (Table 2).

Figure 3-Improvement in PTA in cases with COM following surgery



Out of 55 cases, we observed graft displacement in 1 case (1.8%) and graft uptake was successful in 98.2% cases (Figure 4).

Figure 4 Distribution according to graft displacement

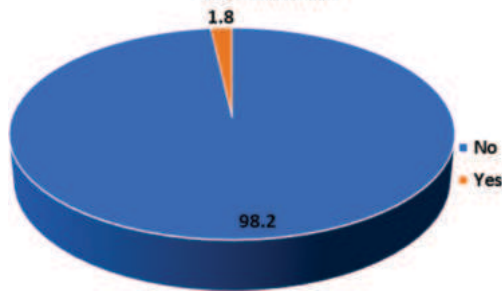


Table 3- Distribution Of Cases According To Complications

Complications	Frequency (n=55)	Percentage
Discharge	1	1.8
Residual perforation	1	1.8

Out of 55 cases, complications in the form of discharge and residual perforation was noted in 1 case (1.8%) (Table 3).

DISCUSSION

Tympanoplasty involving tympanic membrane repair with grafting with or without ossicular reconstruction is the procedure of choice depending upon the extent of involvement of middle and inner ear[6]. Various graft materials including autologous grafts and alloplastic grafts have been used for reconstruction of tympanic membrane with their own advantages and disadvantages[4,7]. Recently, platelet rich plasma, an autologous product is being used commonly for augmenting the healing of perforated tympanic membrane as this product is rich in following seven growth factors namely TGF- β , PDGF, IGF-1, VEGF, platelet-derived epidermal growth factor, epidermal growth factor and fibroblast growth factor[8]. Thus higher concentration of growth factors present in PRP aid in healing of not only the soft tissues but also of joints. In addition to promoting angiogenesis, it accelerates the synthesis of collagen and the repair of soft tissues, reduces dermal scarring, and enhances the hemostatic response to damage. It also speeds up epidermal, endothelial, and epithelial regeneration. PRP is bactericidal because of the high concentration of WBCs in it. PRP is safe and easy to extract, requiring no additional ingredients and a straightforward process. In addition to preventing issues related to an EAC pack, PRP protects the surgical site, maintains the graft in place, and stops the posterior wall of the ear canal from collapsing[14, 15]

Following surgery, we followed up patients at monthly interval for a period of 3 months to assess the success rate of surgery and uptake of graft. Overall, graft uptake rate was 98.2% in our study at 2 as well as 3 months, and among this, graft uptake could be appreciated during first month follow up itself in 90.9% cases. The mean duration of graft uptake in our study was 25.44 \pm 3.71 days. Graft uptake could not take place in 1 case in our study.

Our study findings were concordant with the findings of Vignesh et al in which the authors reported graft uptake in 97.4% cases at 1st as well

as 3 months, and it was reported to be significantly higher as compared to control groups (89.5%; $p < 0.05$)[16]. The graft uptake rate in a study of Yadav et al was 95% in PRP group, which was significantly higher as compared to control group (85%) indicating better healing as a result of autologous PRP graft[17]. Purushottam et al reported graft uptake rate in 92.5% cases in group managed with myringoplasty with autologous platelet rich plasma as compared to 25% in control group ($p < 0.05$)[18].

STUDY	UPTAKE IN CASES	UPTAKE IN CONTROL
Yadav SP et al (2018)	95%	85%
Purushottam PK (2020)	92.5%	25%
Taneja MK (2020)	95.1%	85.3%
Ersozlu T et al (2020)	100%	83.87%
Vignesh R et al(2022S)	97.4%	89.5%
Our Study	98.2%	-

Tympanoplasty and myringoplasty with PRP rich autologous graft was found to be effective in improving the hearing as evidenced from improvement in pure tone audiometry from 45.83 \pm 10.4 dB preoperatively to 40.17 \pm 9.44 dB at 1 month (with mean improvement of 5.66 \pm 3.47 dB), 34.8 \pm 7.49 dB (mean improvement 11.03 \pm 4.91 dB) at 2 month follow up and finally to 31.9 \pm 6.12 dB at 3 months with overall mean improvement of 13.87 \pm 6.8dB from baseline values. The observed improvement in hearing was found to be significant ($p < 0.05$). Similarly, mean PTA at baseline in PRP group in a study of Vignesh et al was 33.63 dB, which reduced to 27.71 at 1 month and 25.61 dB at 3 months, with average improvement of more than 10 dB in 14 out of 38 cases. The improvement in pure tone audiometry was significantly higher in cases (PRP group) as compared to control group ($p < 0.05$)[16]. Yadav et al reported mean improvement in hearing by 18.62 dB in cases managed with PRP and 13.15 dB in control group with as significant difference between the groups ($p < 0.01$)[17].

Mean air bone gap in cases with COM before surgery in our study was 28.69 \pm 9.30, which decreased to 24.06 \pm 8.25 at 1 month, 15.52 \pm 5.63 at 2 month and 13.53 \pm 4.52 at 3 months follow up, with mean improvement of ABG of 15.15 \pm 7.06 ($p < 0.05$). Our study findings were supported by findings of Vignesh et al, in which the authors reported significant reduction in mean ABG in PRP as well as control group. The mean ABG at baseline in PRP group was 23.68 at baseline which reduced by 8.68 \pm 4.8 to 14.74 at final follow up ($p < 0.05$). Though ABG improvement was significant in control group as well, but the improvement was 6.05 \pm 4.05, which was significantly lower than case group ($p < 0.05$)[16]. The air bone gap in a study of El-Anwar et al was 16 \pm 3.83 dB before the procedure which improved significantly to 7 \pm 2.9 dB postoperatively ($p < 0.001$)[19]. Purushottam et al documented mean air bone gap improvement of 17.37 in PRP group as compared to 16.75 in control group[18].

Complications were noted in 1 case in our study in which we reported graft displacement. The complication in this case was residual perforation and it was associated with discharge. Anwar et al reported higher graft failure rate in their study (11.42%) in cases managed with myringoplasty with autologous PRP[20]. Purushottam et al documented postoperative infection in 2.5% cases in PRP group, similar to present study[18].

The graft rejection rate in a study of Taneja et al was 4.9% following myringoplasty with PRP[21]. Previous studies suggests that any substance that promote fast growth in an effective way may help in preventing the migration and displacement of graft and thereby improving the graft uptake rate[21].

Our study had certain limitations, first, the lack of comparison group is a limiting factor in our study as comparison of the PRP group with myringoplasty/tympanoplasty without PRP would have revealed the superiority of adding autologous PRP in better terms. Second, the sample size of the study was small and patients were followed up till 3 months only, however, study with larger sample size with prolonged follow up would have revealed the long term complications of the procedure.

CONCLUSIONS

Use of platelet rich plasma in type 1 tympanoplasty improve the graft uptake rate and promote fast recovery as evidenced from graft uptake within a month in more than 90% of the participants and reduce the risk of graft displacement. Due to presence of various growth factors, PRP aid in closure of tympanic membrane and improve the audiological

outcome in terms of pure tone audiograms and air bone gap. As PRP is autologous in nature, the adverse effects are almost nil.

Conflict Of Interest – none.

REFERENCES

- Ghimire, B., Basnet, M., Aryal, G. R., & Shrestha, N. (2022). Tympanic membrane perforation among patients presenting to department of otorhinolaryngology of a tertiary care hospital: a descriptive cross-sectional study. *JNMA: Journal of the Nepal Medical Association*, 60(247), 246. doi: 10.31729/jnma.7269
- Dolhi, N., & Weimer, A. D. (2023). Tympanic Membrane Perforation. In *StatPearls* [Internet]. StatPearls Publishing. Available from: <https://www.ncbi.nlm.nih.gov/books/NBK557887/>
- Lim, D. J. (1995). Structure and function of the tympanic membrane: a review. *Acta otorhino-laryngologica belgica*, 49(2), 101-115.
- Indorewala, S., Adedeji, T. O., Indorewala, A., & Nemade, G. (2015). Tympanoplasty outcomes: a review of 789 cases. *Iranian journal of otorhinolaryngology*, 27(79), 101.
- Neudert, M., & Zahnert, T. (2017). Tympanoplasty—news and new perspectives. *GMS current topics in Otorhinolaryngology, head and neck surgery*, 16. doi: 10.3205/cto000146
- Merkus, P., Kemp, P., Ziyilan, F., & Yung, M. (2018). Classifications of mastoid and middle ear surgery: A scoping review. *The journal of international advanced otology*, 14(2), 227. doi: 10.5152/iao.2018.5570
- Yung, M., Vivekanandan, S., & Smith, P. (2011). Randomized study comparing fascia and cartilage grafts in myringoplasty. *Annals of Otolaryngology, Rhinology & Laryngology*, 120(8), 535-541. <https://doi.org/10.1177/000348941112000808>
- Shiomi, Y., & Shiomi, Y. (2020). Surgical outcomes of myringoplasty using platelet-rich plasma and evaluation of the outcome-associated factors. *Auris Nasus Larynx*, 47(2), 191-197. <https://doi.org/10.1016/j.anl.2019.06.005>
- Ferrari, M., Zia, S., Valbonesi, M., Henriquet, F., Venere, G., Spagnolo, S., & Panzani, I. (1987). A new technique for hemodilution, preparation of autologous platelet-rich plasma and intraoperative blood salvage in cardiac surgery. *The International journal of artificial organs*, 10(1), 47-50. <https://doi.org/10.1177/039139888701000111>
- Erkilet, E., Koyuncu, M., Atmaca, S., & Yarim, M. (2009). Platelet-rich plasma improves healing of tympanic membrane perforations: experimental study. *The Journal of Laryngology & Otology*, 123(5), 482-487. doi:10.1017/S0022215108003848
- Carlson, E. R. (2000). Bone grafting the jaws in the 21st century: the use of platelet-rich plasma and bone morphogenetic protein. *The Alpha omegan*, 93(3), 26-30.
- Prakash, S., & Thakur, A. (2011). Platelet concentrates: past, present and future. *Journal of maxillofacial and oral surgery*, 10(1), 45-49. <https://doi.org/10.1007/s12663-011-0182-4>
- Ehrenfest, D. M. D., Rasmusson, L., & Albrektsson, T. (2009). Classification of platelet concentrates: from pure platelet-rich plasma (P-PRP) to leucocyte-and platelet-rich fibrin (L-PRF). *Trends in biotechnology*, 27(3), 158-167. <https://doi.org/10.1016/j.tibtech.2008.11.009>
- Bielecki, T. M., Gazdzik, T. S., Arendt, J., Szczepanski, T., Krol, W., & Wielkoszynski, T. (2007). Antibacterial effect of autologous platelet gel enriched with growth factors and other active substances: an in vitro study. *The Journal of Bone & Joint Surgery British Volume*, 89(3), 417-420. <https://doi.org/10.1302/0301-620X.89B3.18491>
- Jang, C. H., Park, H., Cho, Y. B., & Choi, C. H. (2008). The effect of anti-adhesive packing agents in the middle ear of guinea pig. *International journal of pediatric otorhinolaryngology*, 72(11), 1603-1608. <https://doi.org/10.1016/j.ijporl.2008.07.012>
- Vignesh, R., Nirmal Coumare, V., Gopalakrishnan, S., & Karthikeyan, P. (2022). Efficacy of autologous platelet-rich plasma on graft uptake in myringoplasty: a single-blinded randomized control trial. *The Egyptian Journal of Otolaryngology*, 38(1), 6. <https://doi.org/10.1186/s43163-021-00190-x>
- Yadav, S. P. S., Malik, J. S., Malik, P., Sehgal, P. K., Gulia, J. S., & Ranga, R. K. (2018). Studying the result of underlay myringoplasty using platelet-rich plasma. *The Journal of Laryngology & Otology*, 132(11), 990-994. doi:10.1017/S0022215118001846
- Purushothaman PK, Kennedy PJ, Balaji CR. A study on efficacy of autologous platelet rich plasma usage in myringoplasty. *Medpulse*. Available from https://medpulse.in/ENT/html_12_3_5.php Last accessed on 23rd December 2023.
- El-Anwar, M. W., Elnashar, I., & Foad, Y. A. (2017). Platelet-rich plasma myringoplasty: a new office procedure for the repair of small tympanic membrane perforations. *Ear, Nose & Throat Journal*, 96(8), 312-326. <https://doi.org/10.1177/014556131709600818>
- Anwar, F. M., Shenoy, V. S., Kamath, P. M., Sreedharan, S., Deviprasad, D., & Domah, H. A. (2020). Study on use of platelet-rich plasma in myringoplasty. *Indian Journal of Otolaryngology*, 26(2), 71-74. DOI: 10.4103/indianjotol.INDIANJOTOL_103_18
- Taneja, M. K. (2020). Role of platelet rich plasma in tympanoplasty. *Indian Journal of Otolaryngology and Head & Neck Surgery*, 72(2), 247-250. <https://doi.org/10.1007/s12070-020-01815-y>