



ELASTOGRAPHY MEETS HISTOPATHOLOGY: REDEFINING BREAST LESION EVALUATION

Radio-Diagnosis

- Dr Manoj D** 3rd year resident, Department of Radiodiagnosis and Imaging, Government Medical College, Surat.
- Dr Sindhuja R** Senior Resident, Department of Radiodiagnosis and Imaging, Government Medical College, Surat.
- Dr Bhagvati Ukani** Associate professor, Department of Radiodiagnosis and Imaging, Government Medical College, Surat.

ABSTRACT

Breast cancer screening is used to identify women with asymptomatic cancer with the goal of enabling women to undergo less invasive treatments that lead to better outcomes, ideally at earlier stages, and before the cancer progresses. Elastography is a technique that can be used as a complementary tool to conventional ultrasound (US) in evaluating breast masses found on screening USG.(1) USG provides morphological grayscale images, while elastography assesses tissue elasticity, aiding in lesion characterization and therapy monitoring.(2) USG combined with elastography has higher sensitivity in detecting malignant lesions compared to mammography alone, with strain ratio proving to be a valuable non-invasive tool for diagnosing breast malignancies. (3)

KEYWORDS

Elastography, strain ratio, breast lesions.

INTRODUCTION

Elastography images enhance diagnostic information by incorporating data related to tissue elasticity. Breast elastography has become a key complementary technique. A modality in the framework of breast pathology, complementary of B-mode imaging and colour doppler analysis.(4) Our study aims to evaluate the role of qualitative ultrasound scoring, quantitative mass strain ratio (SR), in differentiation between benign and malignant breast lesions. Elastography being noninvasive could reduce the need of unnecessary biopsies of low suspicion category masses.

MATERIALS AND METHOD:

We have included 39 patients who presented to the Tertiary Health Care Centre of South Gujarat with breast lesions for whom biopsies were performed as a part of treatment protocol.

Inclusion Criteria:

Patients referred for ultrasonography of the breast with palpable breast lump

- 1. Female patients aged 18 years and above

Exclusion Criteria:

- 1. Lack of consent to participate in the study
- 2. Patients who have clinical impression of infection or breast abscess
- 3. Patients with breast implants
- 4. All BIRADS US I and BIRADS VI lesion

Imaging Methods:

Ultrasonography and strain wave elastography were performed with Philips affinity 50g and Philips affinity 70g using the linear probe of 7.5MHz.

Data such as age, number of masses, BI-RADS category, and the size of lesion (mm) were also noted.

All the collected data was entered in an excel sheet.

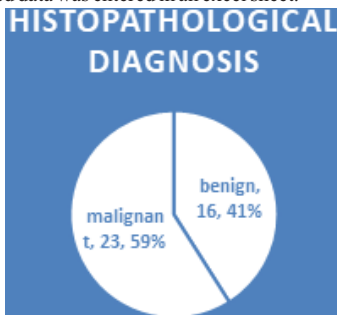


Figure 1 PIE Chart Based On Histopathological Diagnosis

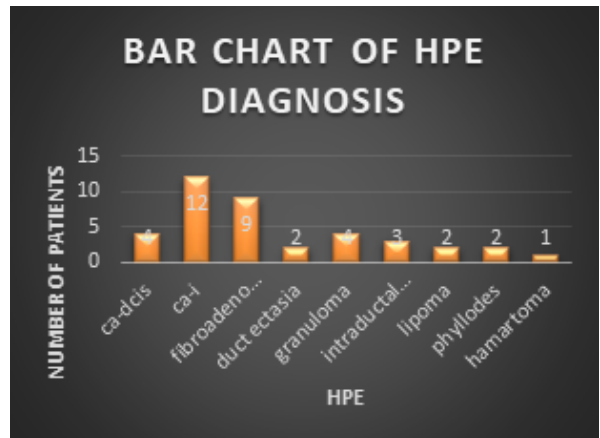
Imaging Technique

USG is done based on which BIRADS score is given and additionally Strain ratio is also calculated using Strain wave elastography results.

Out of 39 patients, 23 were malignant and 16 were benign.

Table 1 Descriptive Analysis Of Histopathological Diagnosis In The Study Population (N=39)

Histopathological Diagnosis	Frequency
DCIS- ductal carcinoma in situ	4
Invasive carcinoma	12
Fibroadenoma	9
Duct ectasia	2
Granuloma	4
Intraductal papilloma	3
Lipoma	2
Phyllodes	2
Hamartoma	1



Case Study

In the present study, the Data was entered into an Excel worksheet and double-checked. IBM SPSS software is used for statistical analysis. Quantitative Elastography findings in this study when considering lesions with the strain ratio less than 3.0 as benign and lesions with a strain ratio more than or equal to 3.0 as malignant.

Association Of Final Histopathological Diagnosis (HPE) With Strain Elastography Ratio Of The Study Population (N=39)

Strain elastography	Final HPE		Chi-square	P-value
	Malignant	Benign		
Strain ratio<3	2	13	20.9863	<.00001

Strain ratio>3	21	3		
----------------	----	---	--	--

Association Of Final Histopathological Diagnosis (HPE) With BIRADS Score Of Study Population (N=39)

BIRADS	Final HPE		Chi-square	P-value
	Malignant	Benign		
BIRADS 2,3	2	14	24.2195	<.00001
BIRADS 4,5	21	2		

DISCUSSION

The overall diagnostic accuracy of Sono-elastography in the evaluation of breast masses is **87.18%** (95 CI 72.57% to 95.70%).

The comparison of the Final Diagnosis between HPE and Sonoelastography average strain ratio is statistically significant (P value<0.05).

Sono-elastography is a cheaper, non-invasive tool than histopathology but is highly operator-dependent.

The combined usage of both Sono mammography and strain elastography can provide a more accurate diagnosis than Sono mammography or strain elastography alone.

LIMITATIONS:

Interobserver variations.

Adequate training for radiologists in Strain elastography techniques not present.

CONCLUSIONS

Ultrasound elastography (US) offers valuable insights for distinguishing between benign and malignant lesions. By considering lesion stiffness, it can enhance positive predictive values and reduce the number of unnecessary benign biopsies. The benefits of SE include a short examination time, real-time imaging, immediate interpretation, cost-effectiveness, and clinically relevant criteria for image assessment. We recommend that elastographic imaging be performed alongside standard ultrasound for a more comprehensive evaluation of breast masses, aiding in planning diagnostic and management strategies for each case.

Conflicts Of Interest: There are no conflicts of interest.

REFERENCES:

- 1) Waleed, Rabiey, Mohammed., Amr, Mahmoud, Zied., Hussein, Montaser, Roshdy. Value of breast elastography in evaluation of breast masses detected on screening ultrasound. *al-azhar medical journal*, (2021).;50(2):1539-1552. doi: 10.21608/AMJ.2021.158640
- 2) Yulin, Fang., Yanjun, Zhou. Diagnosis of breast cancer lesion using ultrasound images, elastography, and Ki-67 protein cell proliferation index.. *Cellular and Molecular Biology*, (2023).;69 4(4):16-23. doi: 10.14715/cmb/2023.69.4.3
- 3) R., Thomas., Sudha, Kiran, Das., Gurumurthy, Balasubramanian., Anupama, Chandrappa. Correlation of Mammography, Ultrasound and Sonoelastographic Findings With Histopathological Diagnosis in Breast Lesions. *Cureus*, (2022).;14 doi: 10.7759/cureus.32318
- 4) Dominique, Amy. Breast Elastography. (2022). doi: 10.5772/intechopen.102445