



NEW DEVELOPMENTS IN DERMOSCOPIC FEATURES OF ALOPECIA AREATA

Dermatology

Dr. Gargi Gaikwad Junior Resident, Department Of Dermatology, Venereology And Leprology, Santosh Medical College And Hospital, Santosh Deemed To Be University, Ghaziabad

Dr. V. K. Garg HOD And Professor, Department Of Dermatology, venereology And Leprology, Santosh Medical College And Hospital, Santosh Deemed To Be University, Ghaziabad

ABSTRACT

Background: Alopecia areata (AA) is an autoimmune disease that results in well defined, circular patches of hair loss, affecting both sexes equally, with a lifetime risk of 1.7%. The disease is characterized by the immune privilege destruction of the hair follicle leading to T-lymphocyte infiltration and premature hair follicle cycling. Dermoscopy has become an essential tool for diagnosing AA, with specific trichoscopic features aiding in its recognition. **Aim:** To assess the trichoscopic characteristics of alopecia areata **Objectives:** To record new developments in trichoscopic features in Alopecia areata **Methods:** This was a prospective and an observational study which was conducted on 60 patients with AA over the course of one year (June 2023 - June 2024). Participants underwent a comprehensive clinical evaluation, including demographic data, medical history, and detailed examination of alopecic patches. Trichoscopic images were obtained using a Dino-lite Edge digital trichoscope. **Results:** The study observed a prevalence of specific trichoscopic features, including black dots (95%), yellow dots (77.5%), and vellus hair (67.5%). Other findings included broken hair (39%), tapering hair (42.5%), exclamation mark hair (27.5%), and trichoptilosis (20%). Trichoptilosis, a longitudinal split in the hair shaft, was particularly noteworthy, as it is traditionally associated with Trichotillomania. This finding highlights the potential overlap in features between AA and other hair disorders. **Limitations:** Genetic studies for patients belonging to this particular area who demonstrated an increase in the frequency of trichoptilosis was not done. **Conclusion:** The study demonstrates how trichoscopy aids in diagnosing Alopecia areata and highlights the significance of emerging features such as trichoptilosis. These findings prove that the loss of immune privilege in AA may lead to hair shaft abnormalities, prompting a reconsideration of the differential diagnosis between alopecia areata and other hair disorders such as trichotillomania. Further research is necessary to investigate the underlying mechanisms and clinical significance of these findings.

KEYWORDS

Alopecia areata, dermoscopy, trichoptilosis

INTRODUCTION

Alopecia areata is an autoimmune disorder with a chronic course with a 1.7% lifetime risk.(1) with a prevalence of approximately 1 in 1000 (2) It affects both sexes equally, with patients often presenting with well defined, circular, non-cicatricial well-demarcated patches of hair loss over the scalp but can involve any part of the body (3) The disease disrupts the immune privilege of hair follicles(4) A reduction in MHC I expression significantly lowers the likelihood that CD8+ T cells will recognize autoantigens. Histological analysis of alopecia areata (AA) lesions supports this, typically revealing a pattern of T-cell infiltration around hair follicles—often described as a "swarm of bees" appearance—as well as an early shift from the active anagen phase to the non-growth catagen and telogen phases. (5) Up to 80% of individuals with patchy AA may see spontaneous hair regrowth; however, treatment options include topical minoxidil, corticosteroids, and Janus kinase (JAK) inhibitors such as tofacitinib. (6)

Dermoscopy helps diagnose AA by detecting characteristic findings like: (7,8):

Yellow Dots: Yellow dots represent dilated follicular openings clogged with sebum, keratin, and degenerative material

Black Dots: Black dots are broken hairs located at the follicular openings. These hair have been broken at the level of stratum corneum.

Broken Hair/ Cadaverised Hair: Hair broken at a level higher than the stratum corneum.

Exclamation-mark Hair: These hairs have a thin, proximal end and a thick, pigmented distal end.

Coudability Hair: These hair have a kink and are bent at an angle. Usually leads to broken hair.

Vellus Hairs: Fine, short, unpigmented hairs that may appear during the regrowth phase.

Pigtail Hair: curved vellus hair

Tulip Hair: Hairs with a pigmented bulbous distal end resembling a tulip

Pohl-pinkus Constriction: Constrictions along the hair shaft caused by metabolic or mitotic arrest.

As trichoscopy aids diagnosing alopecia areata, this study was undertaken to examine the trichoscopic characteristics of Alopecia Areata, with a specific objective of identifying any new characteristics that could enhance the understanding of the disease.

MATERIALS AND METHODS

Type Of Study:

The study was designed as a prospective and observational investigation, done to understand the specific clinical and trichoscopic features associated with Alopecia Areata in a defined patient population.

Place Of Study:

The research was conducted at Santosh Medical College and Hospital, located in Ghaziabad, Uttar Pradesh, India, a tertiary care center catering to a diverse patient demographic.

Sample Size And Study Duration:

A total of 60 patients diagnosed with Alopecia Areata were enrolled in this study. The recruitment and data collection were carried out over a period of one year, specifically from June 2023 to June 2024.

Inclusion Criteria:

The Study Included Individuals Who Fulfilled The Following Criteria:

- Adults aged 18 or older
- Both male and female participants were considered eligible
- Individuals with active disease persisting for at least six months prior to enrollment
- Patients without any signs of secondary scalp infection
- Those who had not received any topical or systemic treatment for alopecia in the preceding four weeks

Exclusion Criteria:

These Participants Were Excluded From The Study:

- Patients who had used any form of topical or systemic therapy for Alopecia Areata within the four weeks prior to enrollment
- Individuals who refused to provide informed consent
- Patients presenting with clinically active inflammation of the scalp that could interfere with the assessment
- Patients using any kind of hair grooming practices
- Patient with history of any kind of mental disorder

Study Design And Methodology:

After obtaining written informed consent from each participant, a comprehensive clinical evaluation was performed. This included collection of demographic details (such as age, sex, occupation), a detailed treatment history, and documentation of the characteristics of alopecic patches, including their number, size, and location.

Each participant underwent **trichoscopic examination of the patch in patients presenting with a single patch and the recent most patch in case multiple patches** using a **Dino-Lite Edge digital trichoscope**, which provided high-resolution images of the scalp and hair. These trichoscopic images were evaluated for specific diagnostic features relevant to Alopecia Areata. The entire procedure was conducted following standard clinical protocols to confirm that the results are precise and replicable

RESULTS

In this study, a total of 60 patients diagnosed with Alopecia Areata were evaluated. Among these, 38 patients (63.3%) were male, while 22 patients (36.6%) were female, which points to a higher prevalence of the condition among males in this study population. Participants were between 18 and 55 years old, representing a broad spectrum of adult patients affected by the disease.

The length of time participants had been affected by Alopecia Areata showed considerable variation, spanning from just 15 days to as long as 8 months, reflecting the inclusion of both recent and relatively chronic cases of the disease. This variability helped provide insights into different stages of disease progression.

Clinically, the majority of the patients presented with a single patch of hair loss, with 34 out of 60 patients (56.6%) exhibiting solitary alopecic lesions. This finding underscores the fact that patchy Alopecia Areata remains a common clinical presentation, especially in early or less severe cases.

The main trichoscopic findings in our study group were Yellow dots, black dots, broken hair, coudability hair, exclamation mark hair, pig tail hair, vellus hair and trichoptilosis. These features have been shown from figure 1 to figure 11.

Black dots were the most common trichoscopic finding in our group of patients. This was followed by yellow dots and vellus hair. Other features that were observed in our study group included tapering hair, coudability hair, broken hair, exclamation mark hair, pig tail hair. Trichoptilosis was present in 20% patients. This had been depicted in table 1 and 2.

Yellow Dots:




Fig 1: Yellow dots represent dilated follicular openings engorged with sebum, keratin, and degenerative material. They are highly sensitive markers of AA but are not specific, as they are occasionally also observed in androgenetic alopecia and other conditions. Their density is greater in chronic or severe cases of AA.

Black Dots:

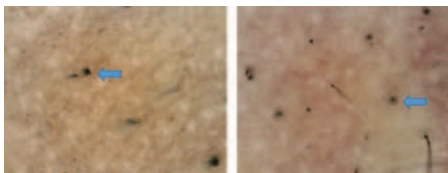


Fig 2: Black dots are pigmented broken hairs located at the follicular openings. Hair are broken at the level of stratum corneum. These are considered hallmark features of AA and signify active disease.

Broken Hair:




Fig 3: Short, fragmented hairs with irregular distal ends, broken at a

level above the stratum corneum. These reflect damage to hair shafts due to follicular inflammation and are common in acute AA

Exclamation Mark Hair:




Fig 4 : These hairs have a thin, proximal end with decreased pigmentation and a thick, pigmented distal end. Exclamation mark hairs are characteristic of the active phase of alopecia areata and are typically found at the periphery of bald patches. Their presence indicates active inflammation, while their disappearance suggests remission.

Tulip Hair:




Fig 5: Hairs with a pigmented distal bulbous end resembling a tulip. These are less commonly seen but are considered markers of ongoing disease activity

Pohl-Pinkus Constriction:



Fig 6: Constrictions along the hair shaft caused by metabolic or mitotic arrest. These are indicative of severe follicular damage and may be observed in chronic cases

Coudability Hair:



Fig 7: These are hairs that bend easily when pressure is applied to the scalp. They have a kink and are bent at an angle and precede the stage of broken hair. Coudability hairs are an early indicator of disease activity and are often noted around the edges of active lesions

Vellus Hair:




Fig 8: Fine, short, unpigmented hairs that may appear during the regrowth phase. The existence of vellus hairs is a positive sign of remission and indicates the regrowth of hair follicles

Pig-Tail Hair:




Fig 9: Vellus hair that grow in circular fashion and resemble the tail of a pig.

White Hair:




Fig 10: The phenomenon of “going white overnight” in patients of alopecia areata.

Trichoptilosis:

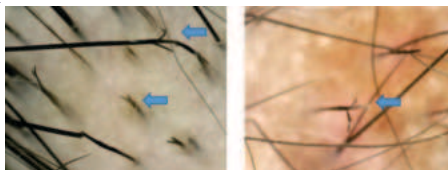
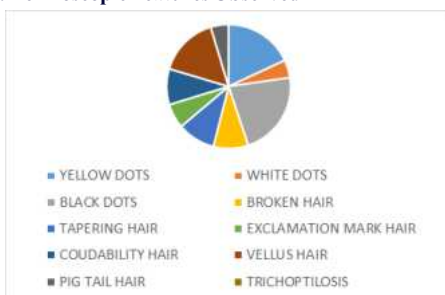


Fig 11: Longitudinal spilt in the hair shaft

Table 1: Dermoscopic Features Observed

DERMOSCOPIC FEATURES	Number of patients	Percentage of patients
Yellow dots	31	77.5 %
White dots	8	20%
Black dots	38	95%
Broken hair	16	39%
Tapering hair	17	42.5%
Exclamation mark hair	11	27.5%
Coudability hair	16	40 %
Vellus hair	27	67.5 %
Pig tail hair	8	20%
Trichoptilosis	8	20%

Table 2: Dermoscopic Features Observed



DISCUSSION

Alopecia Areata (AA) is a chronic, relapsing autoimmune condition that leads to non-scarring hair loss. It typically appears as well-defined, round or oval bald patches on the scalp, though it can affect any area of the body with hair.(3) It is classified as an autoimmune condition, where the body's immune system erroneously targets the anagen hair follicles, particularly affecting pigmented hair, leading to their premature transition into the catagen and telogen phases. Clinically, Alopecia Areata may present with a wide spectrum of severity, ranging from isolated patches to total scalp (Alopecia Totalis) or entire body (Alopecia Universalis) hair loss. The disease course is unpredictable, with periods of spontaneous regrowth and exacerbation. (4)

While the diagnosis of Alopecia Areata is primarily clinical, it is essential to differentiate it from other dermatological conditions that present with similar patterns of hair loss. Trichotillomania, a psychiatric impulse control disorder marked by recurrent hair pulling,

and tinea capitis, a fungal infection of the scalp, are two of the most common differential diagnoses. These conditions may mimic Alopecia Areata in early stages, particularly in children and young adults, making accurate diagnosis crucial for appropriate management.(9)

In cases where the clinical presentation was ambiguous or inconclusive, a biopsy of the scalp was performed to confirm the diagnosis. Histopathological examination typically reveals the characteristic “swarm of bees” appearance, which refers to the dense peribulbar lymphocytic infiltrate, predominantly composed of CD8+ cytotoxic T lymphocytes, surrounding the anagen hair follicles. (5)This distinctive histological pattern is considered diagnostic of active Alopecia Areata, particularly in early stages when follicular destruction is not yet prominent.(23)

However, due to the invasive nature of a biopsy and the potential for discomfort or cosmetic concerns, especially in young patients, clinicians sought a non-invasive alternative to assist in diagnosis. This led to the introduction of trichoscopy—a form of dermoscopy dedicated solely to study the disorders of hair—as a valuable diagnostic tool. In 2004, Lacarrubba et al. first described the use of trichoscopy in patients with Alopecia Areata, highlighting its ability to detect specific diagnostic features such as broken hair, black dots, yellow hair, exclamation mark hairs and coudability hair. Trichoscopy has since become an essential adjunct to clinical evaluation, helping to distinguish Alopecia Areata from other causes of alopecia, assess disease activity, and monitor treatment response—all without the need for a biopsy.(10)

Among the most frequently observed findings are yellow dots, which appear as yellowish structures representing dilated follicular openings filled with keratin and sebum. Yellow dots are considered one of the hallmark features of Alopecia Areata and are particularly prominent in chronic and severe cases. (24) Black dots, on the other hand, are pigmented residues of hairs broken at the scalp level and are indicative of active disease and follicular destruction. White dots may also be observed and often correspond to empty follicular openings or perifollicular fibrosis. (12)

Broken hairs are another commonly encountered feature and represent damaged or fractured hair shafts, frequently seen in areas of active hair loss. These are often associated with heightened hair fragility resulting from inflammation at the follicular level. (25) Vellus hairs, which are thin, short, regrowing hairs, are typically seen during phases of partial recovery and are associated with a more favorable prognosis. (26) Pigtail hairs—short, coiled regrowing hairs—are also suggestive of incipient regrowth in affected patches.(24)

In addition to these findings, several hair shaft abnormalities are considered diagnostic of AA. Coudability hairs are those that bend easily under minimal pressure, particularly at the periphery of the patches, and signify ongoing inflammation affecting the hair shaft. (27) Exclamation mark hairs, which exhibit a tapered proximal end and a thicker distal shaft, are considered pathognomonic of Alopecia Areata and suggest acute hair follicle miniaturization. (28) Another less common but significant finding is Pohl-Pinkus constrictions, which are narrowing along the hair shaft due to temporary growth arrest, often associated with fluctuating disease activity.(29)

More recently, novel trichoscopic features have been described in contemporary studies, further expanding the diagnostic landscape. In particular, studies by Mani et al. and Vijay et al. have drawn attention to additional hair shaft abnormalities, including "Trichoptilosis", which is defined as a longitudinal splitting of the hair shaft, commonly referred to as split ends. (13,14)Although trichoptilosis is often associated with mechanical or chemical trauma, its presence in patients with AA—especially in the absence of grooming damage—may suggest disease-related fragility of hair shafts, possibly due to structural weakening caused by chronic inflammation or disrupted hair growth cycles. (15)

Interestingly, trichoptilosis, was traditionally recognized as a distinctive and characteristic trichoscopic feature associated with Trichotillomania. Trichotillomania is a psychological and behavioral disorder that falls under the spectrum of obsessive-compulsive and related disorders, and it is primarily characterized by persistent, recurrent, and uncontrollable urges to pull out one's own hair. (16)This compulsive hair-pulling behavior typically involves body regions that

are easy to access such as the scalp, eyebrows, eyelashes, and sometimes the pubic or facial hair, leading to visible patchy hair loss and significant psychological distress.(16)

The mechanical trauma resulting from repetitive hair pulling causes direct physical damage to the hair shaft, which in turn leads to a variety of structural abnormalities. One of the most commonly observed consequences is trichoptilosis, which manifests as a distal end splitting of the hair in a longitudinal direction. Under trichoscopy, this appears as a feathered or frayed appearance of the hair tips. This condition arises due to repeated tension, torsion, and mechanical stress applied to the hair, which weakens the integrity of the cuticle and cortex, eventually resulting in breakage and splitting.(17)

It is not exclusive to pathological hair-pulling behavior. Similar structural damage to the hair shaft has been reported in individuals who frequently subject their hair to aggressive grooming or styling practices. These include excessive combing, brushing, tight hairstyles (like braids or ponytails), and frequent use of thermal devices such as hair straighteners, curling irons, and blow dryers. Additionally, chemical treatments including bleaching, perming, and coloring can further compromise the strength of the hair, leading to fragility and longitudinal shaft splitting. Hence, trichoptilosis is also prevalent among people who engage in excessive hair manipulation for cosmetic reasons.(18)

For many years, the presence of trichoptilosis on trichoscopy served as an important differential diagnostic marker in distinguishing Trichotillomania from other causes of alopecia, particularly Alopecia Areata. Alopecia Areata typically lacks the signs of mechanical trauma seen in Trichotillomania. Therefore, trichoptilosis was considered to occur exclusively in Trichotillomania, and its presence was often used to clinically and dermoscopically differentiate between the two conditions. But in recent studies, this feature is seen to be prevalent in Alopecia areata patients as well, with no history of hair grooming practices or mental disorders.

In our study, black dots emerged as the most commonly observed trichoscopic finding among patients with Alopecia Areata, followed by yellow dots and vellus hairs. These findings are consistent with the results reported by Mani et al. (2023) and Vijay et al. (2020), who also identified yellow dots and black dots as the most frequent trichoscopic features in their respective studies (13,14)

With regard to tapering hairs, we observed them in 42.5% of our patients, which is notably lower than the 64% prevalence reported by Mani et al. (13) Tapering hairs are considered a marker of active disease and are often seen at the periphery of alopecic patches, reflecting the weakening of hair shafts due to inflammation.

Interestingly, trichoptilosis—a longitudinal splitting of the hair shaft—was present in 20% of our patients. This is significantly higher than the prevalence reported by Mani et al. (6%) and Khunket et al. (5.8%) (21), but lower than the 33.8% observed in the study by Vijay et al. (2020). Traditionally associated with mechanical hair trauma, trichoptilosis has more commonly been linked to conditions such as Trichotillomania or excessive grooming practices. However, its notable presence in our Alopecia Areata cohort suggests that external environmental factors, frequent hair manipulation, or local hair care habits may play a contributory role. (20)

The relatively higher frequency of trichoptilosis in our population may also be influenced by regional factors such as climatic stress, pollution, or cultural grooming practices, as well as potential genetic predispositions affecting hair shaft strength and resilience. However, these aspects were beyond the scope of our current study and warrant further investigation to better understand their impact.

DERMOSCOPIC FEATURES	Present study	Mani et al, 2023	Vijay et al, 2020
Yellow dots	77.5 %	48%	72.7%
Black dots	95%	96%	36.5%
Broken hair	39%	10%	59.2%
Tapering hair	42.5%	64%	38.5%
Coudability hair	40 %	24%	26.9%
Vellus hair	67.5 %	40%	64.6%
Pig tail hair	20%	32%	-
Trichoptilosis	20%	6%	33.84%

CONCLUSION

New developments in trichoscopy helps us to understand the disease better but, the discovery of trichoptilosis in Alopecia areata in recent studies needs to be studied as this would mean that the underlying pathology of loss of immune privilege in Alopecia areata leads to the weakening of the hair shaft and can give rise to a number of hair shaft abnormalities including trichoptilosis.(20) This also leads to the conclusion that the presence of this feature cannot be used to differentiate between these conditions, even though trichoptilosis occurs in a larger percentage in trichotillomania than in Alopecia areata.

REFERENCES

- Safavi KH, Muller SA, Suman VJ, Moshell AN, Melton LJ 3rd. Incidence of alopecia areata in Olmsted County, Minnesota, 1975 through 1989. *Mayo Clin Proc.* 1995 Jul;70(7):628-33. doi: 10.4066/70.7.628. PMID: 7791384.
- Pratt CH, King LE, Messenger AG, Cristiano AM, Sundberg JP. Alopecia areata. *Nat Rev Dis Primers.* 2017 Mar 16;3:17011
- Pender MP. CD81 T-cell deficiency, Epstein-Barr virus infection, vitamin D deficiency, and steps to autoimmunity: a unifying hypothesis. *Autoimmune Dis* 2012;2012:189096
- Petukhova L, et al. Genome-wide association study in alopecia areata implicates both innate and adaptive immunity. *Nature* 2010;466(7302):113–7.
- Whiting DA. Histopathologic features of alopecia areata: a new look. *Arch Dermatol.* 2003 Dec;139(12):1555-9. doi: 10.1001/archderm.139.12.1555. PMID: 14676070.
- Alopecia Areata New Treatment Options Including Janus Kinase Inhibitors Caiwei Zheng, BAA, Antonella Tosti, MD
- Kaya G, Tak AY. Evaluation of SALT score severity in correlation with trichoscopic findings in alopecia areata: a study of 303 patients. *Arch Dermatol Res.* 2025 Mar 7;317(1):523. doi: 10.1007/s00403-025-04026-z. PMID: 40055222; PMCID: PMC11889066.
- Comparison of Dermoscopic Patterns at the Center and Periphery of Alopecia Areata Patch - A Cross-sectional Study in 100 Patients Bhushan Amol Darkase, Siddhi B Chikhalkar and Uday S Khopkar
- Seetharam KA. Alopecia areata: An update. *Indian J Dermatol Venereol Leprol* 2013;79:563-575
- Lacarrubba, F, Dall'Oglio, M.R. Nasca, G. Micali. Videodermoscopy enhances diagnostic capability in some forms of hair loss. *Am J Clin Dermatol.* 5 (2004), pp. 205-208 <http://dx.doi.org/10.2165/00128071-200405030-00009>
- Waskiel-Burnat A, Rakowska A, Sikora M, Olszewska M, Rudnicka L. Trichoscopy of alopecia areata in children. A retrospective comparative analysis of 50 children and 50 adults. *Pediatr Dermatol.* 2019 Sep;36(5):640-645. doi: 10.1111/pde.13912. Epub 2019 Jul 11. PMID: 31294493.
- Inui S, Nakajima T, Itami S. Coudability hairs: a revisited sign of alopecia areata assessed by trichoscopy. *Clin Exp Dermatol.* 2010 Jun;35(4):361-5. doi: 10.1111/j.1365-2230.2009.03510.x. Epub 2009 Oct 23. Erratum in: *Clin Exp Dermatol.* 2010 Jun;35(4):457. PMID: 19874321.
- Trichoscopy in Alopecia Areata and Trichotillomania in Skin of Colour: A Comparative Study:Siddharth Mani ^{1,2*}, Aradhana Raut ¹, Shekhar Neema ¹, Manish Khandare ¹, Prateksha Golas ¹, Summet Sandhu ¹, Rohit Kohhari ¹, Gopalsing R Rajput ¹, Bhavni Oberoi ¹
- Trichoscopic Evaluation of Alopecia Areata of the Scalp and Clinical Correlation of These Findings with Disease Activity and Severity:Vijay, Anita; Kumari, Pramila; Mohta, Alpana; Vyas, Kapil; Kushwaha, Ramesh Kumar; Jain, Suresh Kumar ²
- Ankad BS, Naidu MV, Beergouder SL, Sujana L. Trichoscopy in trichotillomania: a useful diagnostic tool. *Int J Trichology.* 2014 Oct;6(4):160-3. doi: 10.4103/0974-7753.142856. PMID: 25368471; PMCID: PMC4212291.
- Franklin ME, Zagrabbe K, Benavides KL. Trichotillomania and its treatment: a review and recommendations. *Expert Rev Neurother.* 2011 Aug;11(8):1165-74. doi: 10.1586/ern.11.93. PMID: 21797657; PMCID: PMC3190970.
- Gadzhigoroeva A. Alopecia Areata vs Trichotillomania. *Differential Diagnosis According to Trichoscopy.* *Curr Pediatr.* 2020;19(6). doi: 10.15690/vsp.v19i6.2158
- Govindarajulu SM, Srinivas RT, Kuppaswamy SK, Prem P. Trichoscopic Patterns of Nonscarring Alopecia's. *Int J Trichology.* 2020 May-Jun;12(3):99-106. doi: 10.4103/ijtr.ijt_1_19. Epub 2020 Aug 14. PMID: 33223733; PMCID: PMC7659741.
- Khare S, Behera B, Ding DD, Lallas A, Chauhan P, Enechukwu NA, Slawinska M, Akay BN, Ankad BS, Bhat YJ, Jha AK, Kaliyadan F, Kelati A, Neema S, Parmar NV, Stein J, Usatine RP, Vinay K, Errichetti E. Dermoscopy of Hair and Scalp Disorders (Trichoscopy) in Skin of Color - A Systematic Review by the International Dermoscopy Society "Imaging in Skin of Color" Task Force. *Dermatol Pract Concept.* 2023 Oct 1;13(4 S1):e2023310S. doi: 10.5826/dpc.1304S1a310S. PMID: 37874991; PMCID: PMC10824328.
- Chiramel MJ, Sharma VK, Khandpur S, Sreenivas V. Relevance of trichoscopy in the differential diagnosis of alopecia: A cross-sectional study from North India. *Indian J Dermatol Venereol Leprol* 2016;82:651-658
- Khunkhet S, Vachiramon V, Suchonwanit P. Trichoscopic clues for diagnosis of alopecia areata and trichotillomania in Asians. *Int J Dermatol.* 2017 Feb;56(2):161-165. doi: 10.1111/ijd.13453. PMID: 28074524.
- Park J, Kim JI, Kim HU, Yun SK, Kim SJ. Trichoscopic Findings of Hair Loss in Koreans. *Ann Dermatol.* 2015 Oct;27(5):539-50. doi: 10.5021/ad.2015.27.5.539. Epub 2015 Oct 2. PMID: 26512168; PMCID: PMC4622888.
- Erratum: Alopecia areata incognita and diffuse alopecia areata: clinical, trichoscopic, histopathological, and therapeutic features of a 5-year study (Dermatology Practical and Conceptual (2019) 9:4 (272–277)). doi:10.5826/dpc.0904a05. *Dermatol Pract Concept.* 2020;10. doi:10.5826/dpc.1001a27
- Dermatol.* 2016;23:20–7103.6. Peter D, George L, Pulimood SA. Trichoscopic features of various types of alopecia areata in India: Application of a hand-held dermoscope. *Australas J Dermatol.* 2013;54:198–200.
- DERMOSCOPIC EVALUATION OF THERAPEUTIC RESPONSE IN ALOPECIA AREATA Arun Achar1, Loknath Ghoshal2, Smriti Chowdhury3
- Trichoscopy in Alopecia Areata Tricoscopia en la alopecia areata H. Gómez-Quispe^a, Muñoz Moreno Arrones^{a,b}, A. Hermosa-Gelbard^{a,b}, S. Vaño-Galván^{a,b}, D. Saceda-Corralo^{a,b}
- S. Inui, T. Nakajima, S. Itami. Coudability hairs: a revisited sign of alopecia areata assessed by trichoscopy, *Clinical and Experimental Dermatology*, Volume 35, Issue 4, 1 June 2010, Pages 361–365, <https://doi.org/10.1111/j.1365-2230.2009.03510.x>
- Tobin DJ, Fenton DA, Kendall MD. Ultrastructural study of exclamation-mark hair shafts in alopecia areata. *J Cutan Pathol.* 1990 Dec;17(6):348-54. doi: 10.1111/j.1600-0560.1990.tb00111.x. PMID: 2074281.
- Tobin DJ, Fenton DA, Kendall MD. Ultrastructural study of exclamation-mark hair shafts in alopecia areata. *J Cutan Pathol.* 1990 Dec;17(6):348-54. doi: 10.1111/j.1600-0560.1990.tb00111.x. PMID: 2074281.