



## SURGICAL OUTCOME OF DISTAL END RADIUS INTRA ARTICULAR FRACTURE MANAGED WITH VARIABLE ANGLE LOCKING COMPRESSION PLATE

### Orthopaedics

**Dr. Satyanarayana Murthy K** Post- Graduate

**Dr. Suman NV** Professor

**Dr. Devendrappa H** Professor

**Dr. Arun KN\*** Professor \*Corresponding Author

### ABSTRACT

Distal radius fractures (DRFs) are among the most common orthopedic injuries, often resulting from high-energy trauma or falls. The advent of variable angle locking compression plates (VALCPs) has revolutionized the surgical management of these fractures, offering enhanced fixation, especially in complex fracture patterns. This article delves into the surgical outcomes associated with the use of VALCPs in managing distal end radius fractures, drawing insights from recent studies and clinical experiences. This prospective study was conducted over 18 months (February 2023 to November 2024) at the Department of Orthopaedics, Navodaya Medical College Hospital and Research Centre. Twenty six patients (21 males, 5 females) with distal radius fractures were treated with open reduction and internal fixation using a variable angle locking compression plate. Functional outcomes were assessed using the modified Cooney, Green, and O'Brien wrist scoring system. Results indicated that 20 patients (80%) achieved excellent outcomes, 4 (13.3%) had good outcomes, and 2 (6.67%) had fair outcomes. These findings suggest that open reduction and internal fixation with a locking plate is an effective treatment modality for distal radius fractures, yielding favorable functional results.

**Conclusion:** This study reaffirms that VALCPs, when combined with proper surgical technique and postoperative care, are an effective modality for treating complex distal radius fractures. The Modified Henry approach further enhances outcomes by providing safe and efficient access to the fracture site with minimal soft tissue compromise.

### KEYWORDS

modified henry approach, Frykman's classification, variable angle locking compression plate

### INTRODUCTION

Fractures of the distal end of the radius are among the most frequently encountered injuries in orthopedic practice, comprising nearly 16% of all fractures and over 75% of all forearm fractures treated in emergency departments [1]. These fractures exhibit a bimodal distribution, commonly affecting younger individuals through high-energy trauma (e.g., road traffic accidents, falls from height) and elderly populations through low-energy injuries, often secondary to osteoporotic changes [1,2]. In women over the age of 60, the incidence is particularly high due to postmenopausal osteoporosis [1].

Among the types of distal radius fractures, intra-articular fractures are more complex and present greater challenges due to articular incongruity, risk of joint stiffness, and long-term disability if not treated optimally [3]. Restoration of articular surface congruity is crucial, as failure to do so can result in post-traumatic arthritis, reduced grip strength, and chronic pain [3,4].

Historically, a range of treatment methods has been employed, including closed reduction and cast immobilization, percutaneous pinning, external fixation, and open reduction with internal fixation (ORIF) using dorsal or volar plates [4,5]. While dorsal plating was previously favored for unstable fractures, its association with extensor tendon irritation and rupture led to the increased use of volar plates [5,6].

The development of locking plate technology, particularly variable angle volar locking compression plates (VA-VLCPs), has significantly enhanced the ability to stabilize comminuted intra-articular fractures [6,7]. These implants allow angular stability, customizable screw trajectories, and minimally invasive application on the volar aspect of the radius, reducing the risk of soft tissue complications. Their utility is especially pronounced in osteoporotic bone, where traditional methods often fail to provide adequate fixation [7,8].

Several recent studies have demonstrated encouraging functional and radiological outcomes using VA-VLCPs, with early mobilization leading to improved patient satisfaction and quicker return to daily activities [1,8–10]. However, the literature remains limited, particularly in terms of prospective data and standardized comparisons across populations. This study aims to contribute to the evidence base by evaluating the functional outcomes, radiological parameters, and complication rates of patients with intra-articular distal radius fractures managed surgically using variable angle volar locking

compression plates.

### MATERIALS AND METHODS:

The study included patients with intra-articular distal end radius fractures seen as both outpatient and in-patient fulfilling the inclusion criteria. Collection of data for patients presenting with fracture of distal radius are as follows:-

- Clinical examination, both local and systemic.
- Radiological examination and other imaging modalities.
- Investigation baseline and others.
- Diagnosis – Clinical and Radiological

### Inclusion Criteria:

- Patients with partial and total intra-articular fractures of distal end radius.
- All skeletally mature patients (>18 years of age)
- Closed intra-articular distal end radius fractures.

### Exclusion Criteria:

- Patients below 18 years of age
- Severely comminuted fractures and associated neurovascular injuries.
- Polytrauma and multiple fractures
- Open fractures with extensive soft tissue damage
- Pathological fractures.

Various modalities of surgical management include external fixation, percutaneous pinning, nails, ligamentotaxis and combination of implants.

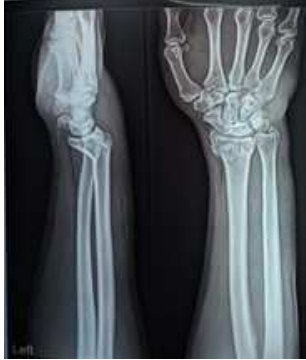**Surgical Procedures:** Anesthesia The operations were performed under general anesthesia or under regional block.

**Position And Tourniquet:** The patient was positioned supine arm on armboard on the operating table. The affected limb was elevated for a brief period of 4-5 minutes, followed by the application of a mid-arm pneumatic tourniquet. The limb was positioned on a side arm board with the shoulder abducted, facilitating comfortable access for the operating surgeon and assistant on either side of the hand table.

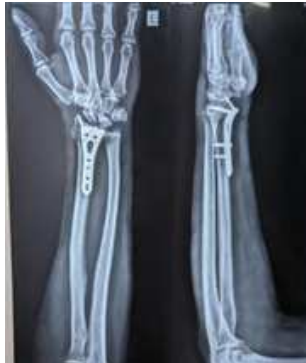### Surgical Procedure

**Modified Henry's Approach:** With the forearm in supination, make a longitudinal incision over the interval between the brachioradialis and the flexor carpi radialis muscles Identify and protect the sensory

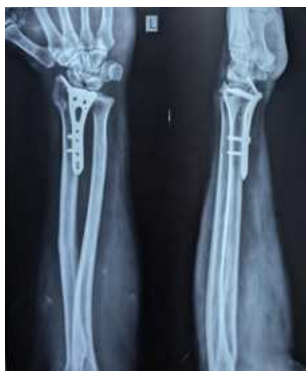branch of radial nerve, which lies beneath brachioradialis muscle. Open both Volar and dorsal sheath of flexor carpi radialis tendon and retract FCR tendon towards ulna Identify and retract flexor pollicis longus towards ulna Identify and make Inverted L shaped incision over pronator quadratus and retract muscle towards ulna The fracture line is now clearly visualised and reduced by manipulation and ligamentotaxis and confirmed the same under c-arm Provisional k-wires may be used to maintain reduction The appropriate plate with 2.7mm and 3.5mm screws is applied. Pronator quadratus sutured covering the distal end of plate to prevent tendon irritation. The plate functions in two ways – buttress the distal fragment and maintains metaphyseal reduction



Pre Operative Radiograph



Postoperative Radiograph



6 Months Follow Up



Clinical Images

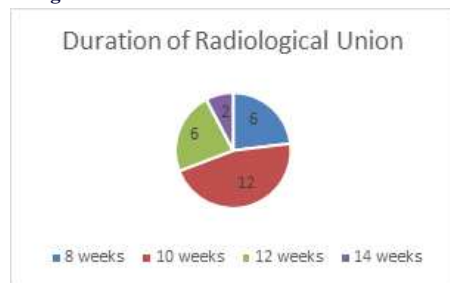


Figure 1: Duration of radiological union

**RESULTS**

This prospective study included 26 patients with closed intra-articular distal end radius fractures treated using VALCP. The cohort included 21 males and 5 females, with road traffic accidents being the most common mode of injury (81%).

Most patients achieved radiological union within 10-12 weeks (Figure 1). No cases of nonunion or malunion were reported.

Functional outcomes were measured using the Modified Cooney, Green, and O'Brien wrist scoring system, reflecting parameters such as

pain, functional mobility, grip strength, and return to work/activities. Results were excellent in 20 patients (80%), good in 4 (13.3%) and fair in 2 patients (6.67%).

Restoration of radial height, volar tilt, and ulnar variance were consistently achieved.

All cases demonstrated proper alignment without loss of fixation on follow-up imaging.

No cases of deep infection, implant loosening, or tendon rupture. A few patients reported mild stiffness, which improved with physiotherapy.

## DISCUSSION

The findings of our study reinforce the growing consensus that variable-angle volar locking compression plates (VA-VLCPs) offer excellent functional and radiological outcomes in the management of intra-articular distal radius fractures. Our results, particularly in terms of range of motion, grip strength, Modified Mayo Wrist Score (MMWS), and radiographic alignment, are consistent with existing literature.

A key feature of VA-VLCPs is the ability to place screws at various trajectories, which allows for better capture and stabilization of comminuted articular fragments. This adaptability is especially important in intra-articular fractures, where small volar lunate or radial styloid fragments may otherwise be difficult to secure with fixed-angle implants [8]. As Chen et al. reported, VA-LCPs demonstrated superior maintenance of volar tilt and articular alignment when compared to fixed-angle devices, likely due to this design feature [8].

Functionally, most of our patients achieved excellent to good results as measured by the Modified Mayo Wrist Score, similar to outcomes reported by Pradeep et al. (72% excellent, 24% good) and Kuppan et al. (71.4% excellent, 28.6% good) [1,9]. Additionally, the early return to activities of daily living observed in our cohort mirrors the findings by MacFarlane et al., who noted early return to work and low complication rates in a long-term follow-up study [11].

Another strength of VA-VLCPs is their compatibility with early mobilization protocols. The volar approach permits plate placement beneath the pronator quadratus, offering a well-padded environment that reduces the likelihood of flexor tendon irritation, a complication more commonly associated with dorsal plating [5,6]. In our series, as in the study by Xavier et al., the majority of patients initiated wrist mobilization within the first post-operative week, leading to faster recovery of function [2].

Complication rates in our study were low. Only minor soft tissue complications were noted, and no instances of tendon rupture, hardware failure, or nonunion were recorded. This is in line with reports by Patel et al. and Gaonkar et al., who highlighted the safety and reliability of VA-LCPs in both young and elderly populations [7,10]. Additionally, the comparative study by Gaonkar et al. suggested superior forearm rotation and reduced soft tissue irritation with VA-LCPs over conventional Ellis plates [7].

It is worth noting that although volar locking plates show advantages in early recovery and implant-related outcomes, long-term functional superiority remains a subject of debate. Chaudhry et al., in a meta-analysis comparing VLCPs and K-wires, found statistically better DASH scores at 3 and 12 months in the VLCP group, but the differences did not exceed the threshold for clinical relevance [12]. This highlights the importance of patient selection, fracture classification, and surgical expertise in optimizing outcomes.

A limitation of our study is the absence of a control group, such as patients treated with K-wires or external fixation. Additionally, the sample size and follow-up duration may limit generalizability. Future randomized controlled trials with larger cohorts and long-term follow-up are essential to validate these results and refine treatment guidelines.

In conclusion, our findings support the use of variable-angle volar locking compression plates in managing intra-articular distal radius fractures. The technique provides stable fixation, early mobilization, minimal complications, and favorable functional outcomes. With proper patient selection and adherence to rehabilitation protocols, VA-

VLCPs appear to be a superior option for managing these complex injuries.

## CONCLUSION

The use of Variable Angle Locking Compression Plates in the management of intra-articular distal end radius fractures has demonstrated excellent outcomes in terms of anatomical alignment, functional recovery, and patient satisfaction. The ability to customize screw trajectories provides superior fixation, especially in comminuted fractures, which translates into reliable union and early rehabilitation.

This study reaffirms that VALCPs, when combined with proper surgical technique and postoperative care, are an effective modality for treating complex distal radius fractures. The Modified Henry approach further enhances outcomes by providing safe and efficient access to the fracture site with minimal soft tissue compromise.

Despite the small sample size and lack of long-term follow-up, the high rate of excellent and good outcomes suggests that VALCPs should be considered a first-line surgical treatment for eligible patients. As surgical technology evolves, continued research with larger patient populations and comparative studies will further clarify the definitive role of VALCP in the orthopedic management of distal radius fractures.

## REFERENCES:

1. Pradeep E, Singh PPB, Janeson JDJ, Kumar KVA, Sheik M, Gopi P. Clinico-radiological Outcome of Variable Angle Volar Locking Plate in the Management of Distal Radius Fractures. *J Orthop Case Rep.* 2025;15(4):270-6.
2. Xavier CRM, Dal Molin DC, dos Santos RMM, dos Santos RDT, Ferreira Neto JC. Surgical treatment of distal radius fractures with a volar locked plate: Correlation of clinical and radiographic results. *Rev Bras Ortop.* 2011;46(5):505-13.
3. Fok MWM, Klausmeyer MA, Fernandez DL, Orbay JL, Bergada AL. Volar plate fixation of intra-articular distal radius fractures: A retrospective study. *J Wrist Surg.* 2013;2(3):247-54.
4. Smith WR, Ziran B, Anglen J, Stahel P. Locking plates: Tips and tricks. *J Bone Joint Surg Am.* 2007;89(10):2298-307.
5. MacFarlane RJ, Miller D, Wilson L, Meyer C, Kerin C, Ford DJ, Cheung G. Functional outcome and complications at 2.5 years following volar locking plate fixation of distal radius fractures. *J Hand Microsurg.* 2015;7(1):18-24.
6. Chaudhry H, Kleinlugtenbelt YV, Mundi R, Risteovski B, Goslings JC, Bhandari M. Are volar locking plates superior to percutaneous K-wires for distal radius fractures? A meta-analysis. *Clin Orthop Relat Res.* 2015;473(9):3017-27.
7. Gaonkar N, Patil N, Kolekar A. Intra-articular distal end radius fractures treated with volar locking plate variations. *J Pharm Bioall Sci.* 2023;15(Suppl 1):S1030-2.
8. Chen M, Gittings DJ, Yang S, Liu G, Xia T. Variable-angle locking compression plate fixation of distal radius volar rim fractures. *Iowa Orthop J.* 2019;39(2):55-60.
9. Kuppan N. Functional outcome of distal end radius fractures managed with variable-angle locking plates: A prospective study. *J Orthop Dis Traumatol.* 2022;5(3): [pagination not available].
10. Patel S, Deshmukh A, Yadav P, Phalak M, Gurnani S, Yadav S, Anand A. Assessment of functional and radiological outcomes of comminuted intra-articular distal radius fracture treated with locking compression plate. *Cureus.* 2022;14(1):e21398.
11. MacFarlane RJ, Miller D, Wilson L, Meyer C, Kerin C, Ford DJ, Cheung G. Functional outcome and complications at 2.5 years following volar locking plate fixation of distal radius fractures. *J Hand Microsurg.* 2015;7(1):18-24.
12. Chaudhry H, Kleinlugtenbelt YV, Mundi R, et al. Are volar locking plates superior to percutaneous K-wires for distal radius fractures? A meta-analysis. *Clin Orthop Relat Res.* 2015;473(9):3017-27.