



DIFFUSE LARGE B-CELL LYMPHOMA PRESENTING AS A PALATAL ULCER: A RARE CASE REPORT AND COMPREHENSIVE REVIEW OF ORAL NON-HODGKIN LYMPHOMA

Otorhinolaryngology

Dr. Sunil Bajoliya	Associate Professor & Head Of Department, Department Of ENT, Nandkumar Singh Chouhan Government Medical College, Khandwa, Madhya Pradesh, India
Dr. Shivam Singh*	Senior Resident, Department Of ENT, Nandkumar Singh Chouhan Government Medical College, Khandwa, Madhya Pradesh, India *Corresponding Author
Dr. Sweta Sharma	Post Graduate Resident, Department Of ENT, Nandkumar Singh Chouhan Government Medical College, Khandwa, Madhya Pradesh, India

ABSTRACT

Non-Hodgkin lymphoma (NHL) is a diverse group of hematolymphoid malignancies, which rarely present in the oral cavity. Despite its uncommon occurrence, early recognition of oral NHL is crucial due to its aggressive nature and potential for systemic spread. We report the case of a 57-year-old female presenting with a persistent, painful ulcer on the soft palate, ultimately diagnosed as diffuse large B-cell lymphoma (DLBCL). The patient underwent a combination of immunochemotherapy and radiotherapy with successful remission. This report emphasizes the importance of including NHL in the differential diagnosis of chronic oral lesions and highlights the role of histopathology and immunohistochemistry in establishing a definitive diagnosis. We also discuss the pathogenesis, diagnostic challenges, and current therapeutic approaches for oral NHL based on a review of the literature.

KEYWORDS

INTRODUCTION

Lymphomas are unusual malignant neoplasms that involves the lymphoreticular system, comprising about 14% of all head and neck malignancies [1]. They are broadly classified into two sub-types, Hodgkin lymphoma (HL) and non-Hodgkin lymphoma (NHL), which differ in histology, clinical features, and the prognosis. Around 97% of lymphomas are NHL. HL typically appears as a nodal disease, and NHL appears as a nodal and extra-nodal disease [2].

Non-Hodgkin lymphoma (NHL) encompasses a heterogeneous group of lymphoid neoplasms, exhibiting a broad spectrum of clinical behavior ranging from indolent to highly aggressive and potentially life-threatening forms. While the majority of NHL cases arise within lymph nodes, extranodal involvement is observed in approximately 20–30% of cases [3]. Common extranodal sites include the gastrointestinal tract, lungs, orbit, paranasal sinuses, thyroid, tonsils, salivary glands, breast, testes, and kidneys. Waldeyer's ring represents the second most frequent site of extranodal NHL after the gastrointestinal tract. In contrast, primary lymphomas of the oral cavity are rare, with reported incidence rates ranging from 0.1% to 5% [4]. Nonetheless, lymphoma remains the third most common malignancy in this region, following squamous cell carcinoma and salivary gland tumors [5].

The etiology of non-Hodgkin lymphoma (NHL) is multifactorial, with a strong correlation to certain viral infections. The average age at diagnosis is approximately 66 years, with a slight male predominance [6]. NHL comprises over 40 major subtypes, each characterized by distinct genetic, morphological, and clinical profiles [7]. In HIV-positive populations, lymphomas predominantly affect younger males. Clinically, patients may present with localized or diffuse soft tissue swelling, pain, mucosal ulceration or discoloration, paresthesia, anesthesia, and loosening of teeth [8]. Among immunocompetent individuals, diffuse large B-cell lymphoma (DLBCL) is the most frequently encountered subtype. However, other variants such as mantle cell lymphoma, marginal zone B-cell lymphoma, Burkitt lymphoma, lymphoblastic lymphoma, peripheral T-cell lymphoma, and anaplastic large cell lymphoma are also observed [9].

Oral non-Hodgkin lymphoma (NHL) typically presents as a progressively enlarging mass, which may be covered by either intact or ulcerated mucosa. Radiographically, the lesion may initially resemble a periapical pathology due to its location and appearance; however, its infiltrative nature often results in ill-defined borders [10]. Given its rarity and non-specific clinical features, oral NHL can be easily mistaken for inflammatory odontogenic or periodontal conditions, contributing to diagnostic challenges and potential delays in treatment [11].

The evaluation of chronic oral ulcerations remains particularly difficult due to the significant overlap in clinical presentations among

various conditions. Therefore, histopathological examination through biopsy is essential to achieve a definitive diagnosis [12].

Case Report

A 57-year-old female presented to the ENT department with a primary complaint of a painful ulcer on the left soft palate that had persisted for four months. The pain intensified during mastication and mouth opening. Concurrently, she developed swelling on the left side of her neck, which began around the same time as the throat pain. Over the preceding week, the symptoms worsened with the onset of odynophagia and reduced oral intake; she was unable to tolerate solid food and had switched to a semi-solid and liquid diet. Additionally, she experienced intermittent low-grade fever without associated chills, rigors, or night sweats, which subsided with paracetamol. Her medical history was unremarkable for malignancy, weight loss, or chronic cough. She did not smoke or consume alcohol but had a positive history of tobacco use.

On general examination, the patient appeared moderately nourished, well-hydrated, and clinically stable. Vital signs were within normal limits, and there were no signs of anemia or sepsis. A single, palpable upper cervical lymph node was noted on the left side, measuring approximately 3 × 2 cm. No lymphadenopathy was detected in the axillary or inguinal regions. Cranial nerve function was intact.

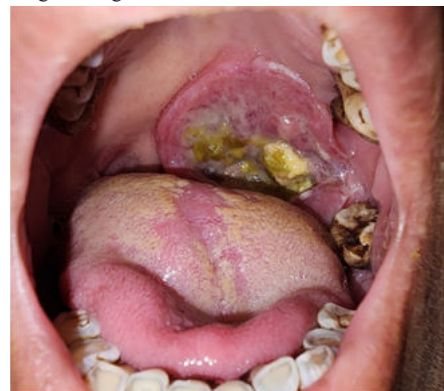

Fig. 1 : A single, irregularly edge ulcer with necrotic base over the left soft palate involving anterior tonsillar pillar at presentation.

Intraoral examination revealed an ulcer with irregular margins on the left soft palate, extending laterally to the left tonsillar fossa and involving the anterior tonsillar pillar. The lesion measured around 5 × 4 cm, with the uvula deviated toward the right. The ulcer had sloping edges and a necrotic base. It was tender to palpation but did not exhibit contact bleeding. Flexible nasopharyngolaryngoscopy showed no abnormalities.

Initial laboratory investigations, including viral markers, were performed. Due to the chronicity of the ulcer, an incisional biopsy was obtained. Histopathological analysis revealed hyperplastic stratified squamous epithelium with mild dysplasia and koilocytosis. The subepithelial tissue showed sparse chronic inflammatory infiltrates consisting of lymphocytes, plasma cells, and histiocytes. As the findings were non-diagnostic, a repeat biopsy from a more representative area was recommended. The patient was prescribed a two-week course of antibiotics and analgesics for symptom relief.

Upon return, a second biopsy was performed. Histopathology revealed hyperplastic stratified squamous epithelium overlying subepithelial stroma infiltrated by large lymphoid cells with round to irregular nuclei, findings suggestive of non-Hodgkin lymphoma. Immunohistochemical staining was positive for Ki-67, with co-expression of CD45, CD20, BCL-2, and BCL-6, supporting a diagnosis of diffuse large B-cell lymphoma (DLBCL) with a high proliferative index. Peripheral blood examination showed normal leukocyte counts, and bone marrow biopsy revealed no evidence of lymphomatous infiltration. A systemic workup identified no additional foci of lymphoma beyond the left upper cervical lymphadenopathy. The parotid and submandibular glands were bilaterally normal.

The patient was referred to the oncology department, where she underwent six cycles of immunochemotherapy with the R-CHOP regimen (rituximab, cyclophosphamide, doxorubicin, vincristine, and prednisolone) at three-week intervals. She was counseled on oral hygiene and prescribed chlorhexidine mouthwash for daily use. Following chemotherapy, she received adjunctive radiotherapy.

Post-treatment follow-up revealed complete resolution of the oral ulcer. However, significant fibrosis of the left soft palate was noted, resulting in narrowing of the ipsilateral fauces. Her symptoms had markedly improved, and she resumed normal oral intake. At the one-year follow-up, the patient remained in remission with no evidence of disease progression.

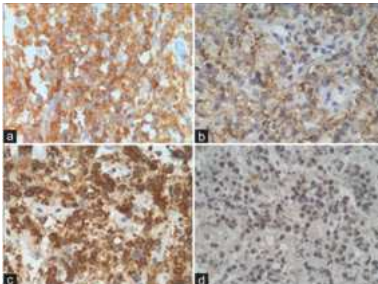


Fig. 2 : Immunohistochemical analysis showing the co-expression of CD45 (a), CD20 (b), BCL-2 (c), and BCL-6 (d) associated to a high proliferative index to Ki-67 and the negativity for the other markers

DISCUSSION

Lymphomas are malignant neoplasms of lymphoid origin, characterized by a broad spectrum of clinical presentations and histopathological features. They are primarily classified into two major types: Hodgkin lymphoma (HL) and non-Hodgkin lymphoma (NHL), each exhibiting distinct biological behavior and treatment responses. Approximately two-thirds of NHL cases present with nodal involvement—typically in regions such as the cervical, axillary, or inguinal lymph nodes. The remaining third arises in extranodal locations, including Waldeyer's ring, oral cavity, oropharynx, gastrointestinal tract, testes, thyroid, skin, breast, bone, brain, or other visceral organs [13].

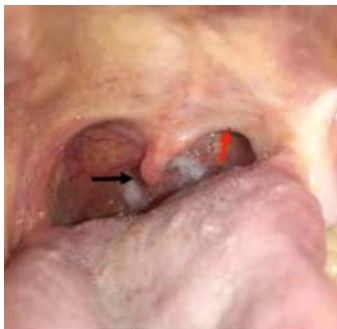

Fig. 3 : A completely healed ulcer with fibrosis on the soft palate causing narrowing of the fauces (red arrow) and slight uvula deviation to the right (black arrow) post-completion 6 cycles of R-CHOP.

In the head and neck region, extranodal NHL most commonly affects Waldeyer's ring. When the oral cavity is involved, lesions may appear in the maxilla, mandible, hard and soft palates, gingiva, or tongue. Among 98 reported cases of oral NHL, the alveolar ridge and gingiva were most frequently affected, followed by the palate. Some studies, however, found the palate to be more commonly involved, possibly due to its anatomical proximity to Waldeyer's ring. In general, soft tissue involvement is more prevalent than bony lesions [14]. When jaw bones are affected, imaging often reveals ill-defined radiolucencies or hypodense areas with cortical expansion and destruction [5]. Clinically, NHL typically presents as persistent, painless lymphadenopathy, although some patients may exhibit systemic symptoms such as night sweats, prolonged fever, and unexplained weight loss [15]. Intraoral lesions may mimic common dental pathologies like abscesses or periodontal infections, often presenting with tooth mobility, localized ulceration, unexplained dental pain, or osseous destruction—leading to frequent misdiagnosis [4].

The etiology of NHL remains multifactorial and not fully understood. Immunosuppression is the most recognized risk factor, particularly in individuals with HIV. Epstein-Barr virus (EBV) is also strongly implicated, especially in B-cell lymphomas [6]. EBV-positive large B-cell lymphomas tend to present in nodal sites in younger patients, whereas extranodal involvement is more common in the elderly. Other potential contributing factors include genetic predisposition, autoimmune and allergic conditions, infections (e.g., hepatitis C virus, *Helicobacter pylori*), lifestyle factors (e.g., smoking, alcohol, body mass index), and occupational exposures [7]. However, the patient described in this case report did not present with any known predisposing conditions.

The definitive diagnosis of oral NHL relies on histopathological analysis of a biopsy specimen [15]. Accurate diagnosis requires an adequate tissue sample, as morphological features can overlap with other malignancies such as undifferentiated carcinomas, sarcomas, plasmacytomas, and malignant melanomas. Immunohistochemistry is essential for accurate classification [6]. Diffuse large B-cell lymphoma (DLBCL) typically shows positivity for CD45 and pan B-cell markers such as CD19, CD20, CD22, CD79, and PAX5, and may express other markers including CD10, BCL2, BCL6, Ki-67, IRF4/MUM1, and p53 [16]. Importantly, DLBCL is negative for epithelial markers, CD3, CD138, myeloperoxidase, desmin, and S100, ruling out the aforementioned lesions included in the histological differential diagnosis [6]. Given the heterogeneity and complexity of lymphomas, diagnosis and classification often necessitate multidisciplinary collaboration between hematologists, oncologists, surgeons, and pathologists.

DLBCL is an aggressive subtype of NHL that requires prompt intervention. Treatment often involves systemic chemotherapy, radiotherapy, or a combination of both [16]. The most widely used chemotherapy protocol is the R-CHOP regimen, which includes rituximab, cyclophosphamide, doxorubicin, vincristine, and prednisone. It is typically administered in six 21-day cycles, although variations may be employed depending on disease stage and patient condition. For early-stage disease (Stage I/II), three to four cycles followed by radiotherapy may be adequate. In this case, six cycles of R-CHOP followed by radiotherapy were administered, resulting in significant regression of cervical lymphadenopathy with no new nodal or extranodal involvement. Follow-up imaging indicated a partial response (>50% reduction in lesion size), consistent with non-progressive disease requiring routine surveillance [17].

Maheshwari et al. reported disease-free survival of 19 months following six cycles of cyclophosphamide, vincristine, and prednisone (CVP) combined with 50 Gy radiotherapy over five weeks [18]. Van der Waal et al. advocated radiotherapy (28–40 Gy) alone for Stage I disease and a combination approach for more advanced stages, using CHOP for aggressive variants and chlorambucil (with or without prednisolone) for indolent forms. Their study observed a mean survival of 38 months with no disease-related mortality [19].

Recent advancements include the integration of monoclonal antibodies targeting CD20 (rituximab) with CHOP, which has improved initial response rates and reduced relapse rates in adults. Similar therapeutic strategies are under investigation for pediatric B-cell lymphomas. Trials exploring antibodies against CD30 and small molecule ALK inhibitors are also underway, offering promise for

future targeted therapies [3].

The prognosis of NHL is influenced by disease stage, histological subtype, and comorbid conditions such as HIV. Aggressive B-cell lymphomas like DLBCL and Burkitt's lymphoma tend to have rapid progression, while indolent types such as follicular lymphoma exhibit a more chronic course. Among T-cell lymphomas, anaplastic large cell lymphoma demonstrates aggressive behavior, whereas mycosis fungoides is relatively indolent. HIV-positive individuals typically have poorer outcomes due to accelerated disease progression and increased susceptibility to opportunistic infections. Reported median survival is approximately 9 months in HIV-positive patients, compared to 34 months in immunocompetent individuals [20].

CONCLUSION :

Although, non-Hodgkin's lymphoma is relatively rare within the oral cavity, it should remain a key consideration in the differential diagnosis of intraoral malignancies. In many cases, the initial detection of oral NHL may be made by an ENT specialist. Early and accurate diagnosis is crucial for favorable outcomes, especially given the availability of effective treatment options such as chemoimmunotherapy. Although oncologists primarily oversee treatment, ongoing assessment and surveillance by ENT surgeons play a vital role in identifying recurrences or emerging local complications.

Acknowledgments

The authors express their gratitude to the oncology and pathology departments for their collaborative efforts in diagnosis and management.

Declaration Of Patient Consent

The authors certify that appropriate patient consent was obtained for publication of this case report and related images.

Financial Support And Sponsorship

None.

Conflicts Of Interest

The authors declare no conflicts of interest.

REFERENCES

- Deng D, Wang Y, Liu W, Qian Y. Oral and maxillofacial non-Hodgkin lymphoma. *Medicine (Baltimore)*. 2107;96(35): 7891-99. doi:10.1097/MD.00000000000007890
- Trebouet A, Marchand T, Lemal R, Gyan E, Broussais-Guillaumont F, Guillermin Y, Monjanel H, Salles G, Le Gouill S, Godmer P, Fruchart C, Damaj G, Feugier P, Thieblemont C, Maynadié M, Monnereau A, Troussard X, Rossille D, Lamy T, Houot R. Lymphoma occurring in patient over 90 years of age: Characteristic, outcomes, and prognostic factors. A retrospective analysis of 234 cases from the LYSA. *Ann Oncol*. 2013;24(10):2612-18. doi: 10.1093/annonc/mdt282
- Sahoo SR, Misra SR, Mishra L, Mishra S. Primary diffuse large B-cell lymphoma in the anterior hard palate: A rare case report with review of literature. *J Oral Maxillofac Pathol*. 2014;18:102-6. doi: 10.4103/0973-029X.131927. PubMed PMID: 24959047; PubMed Central PMCID: PMC4065424.
- Reddy I, Sreenath G, Reddy YR, Prakash AR, Swathi TR. Non-Hodgkin's lymphoma in buccal vestibule- case report. *J Clin Diagn Res*. 2014;8:QD01-2. doi: 10.7860/JCDR/2014/8396.4740. PubMed PMID: 25302245; PubMed Central PMCID: PMC4190770.
- Triantafyllidou K, Dimitrakopoulos J, Iordanidis F, Gkagkalis A. Extranodal non-hodgkin lymphomas of the oral cavity and maxillofacial region: A clinical study of 58 cases and review of the literature. *J Oral Maxillofac Surg* 2012;70:2776-85.
- Hussein MRA. Non-Hodgkin's lymphoma of the oral cavity and maxillofacial region: A pathologist viewpoint. *Expert Rev Hematol* 2018;11:737-48.
- Chihara D, Nastoupil JJ, Williams JN, Lee P, Koff JL, Flowers CR. New insights into the epidemiology of non-Hodgkin lymphoma and implications for therapy. *Expert Rev Anticancer Ther* 2015;15:531-44.
- Parrington SJ, Punnia-Moorthy A. Primary non-Hodgkin's lymphoma of the mandible presenting following tooth extraction. *Brit Dent J* 1999;187:468-70.
- Hicks MJ, Flaitz CM. External root resorption of a primary molar: Incidental histopathological finding of clinical significance. *Oral Surg Oral Med Oral Pathol Oral Radiol Endod* 2001;92:4-8.
- Mortazavi H, Baharvan M, Rezacifar K. Periapical lymphoma: Review of reported cases in the literature. *J Stomatol Oral Maxillofac Surg* 2020;121:404-7.
- Sirsath NT, Lakshmaiah KC, Das U, Lokanatha SP, Chennagiri SP, Ramarao C. Primary extranodal non-Hodgkin's lymphoma of oral cavity--A single centre retrospective study. *J Cancer Res. Ther* 2014;10:945-50.
- Minhas S, Sajjad A, Kashif M, Taj F, Waddani HA, Khurshid Z. Oral ulcers presentation in systemic diseases: An update. *Open Access Maced J Med Sci*. 2019; 7(19): 3341-47. doi: 10.3889/oamjms.2019.689.
- Epstein JB, Epstein JD, Le ND, Gorsky M. Characteristics of oral and paraoral malignant lymphoma: A population-based review of 361 cases. *Oral Surg Oral Med Oral Pathol Oral Radiol Endod*. 2001;92(5): 519-25. doi: 10.1067/moe.2001.116062.
- Kusuke N, Custódio M, Sousa SCOM. Oral lesion as the primary diagnosis of non-Hodgkin's lymphoma: A 20-year experience from an oral pathology service and review of the literature. *Eur Arch Otorhinolaryngol* 2019;276:2873-9.
- Ansell SM. Non-hodgkin lymphoma: Diagnosis and treatment. *Mayo Clin Proc* 2015;90:1152-63.
- Jayapalan CS, Pynadath MK, Mangalath U, George A, Aslam S, Hafiz A. Clinical diagnostic dilemma in an uncharacteristic rapidly enlarging swelling of the anterior maxilla: extranodal diffuse large B cell lymphoma. *BMJ Case Rep*. 2016; 2016: 1-5. doi: 10.1136/bcr-2015-213141.
- Zou H, Yang H, Zou Y, Lei L, Song L. Primary diffuse large B-cell lymphoma in the

- maxilla. *Medicine*. 2018;97(20):10707-12. doi: 10.1097/MD.00000000000010707.
- Maheshwari GK, Baboo HA, Gopal U, Wadhwa MK. Primary extra-nodal non-Hodgkin's lymphoma of the cheek. *J Postgrad Med*. 2000;46:211-2. PubMed PMID: 11298474.
- Van der Waal RI, Huijgens PC, van der Valk P, van der Waal I. Characteristics of 40 primary extranodal non-Hodgkin lymphomas of the oral cavity in perspective of the new WHO classification and the International Prognostic Index. *Int J Oral Maxillofac Surg*. 2005;34:391-5. doi: 10.1016/j.ijom.2004.08.009. PubMed PMID: 16053848.
- Cattaneo C, Facchetti F, Re A, Borlenghi E, Majorana A, Bardellini E, et al. Oral cavity lymphomas in immunocompetent and human immunodeficiency virus infected patients. *Leuk Lymphoma*. 2005;46:77-81. doi: 10.1080/10428190400007789. PubMed PMID: 15621784.