



## TO ASSESS MICROBIOLOGICAL AND THERAPEUTIC MANAGEMENT OF PAROTID ABSCESES

### Otorhinolaryngology

<b>Dr Monika Negi</b>	Post graduate student in Department of ENT and head and neck surgery, Gandhi Medical college, Bhopal(M.P.)
<b>Dr Diksha Singh Baghel</b>	Post graduate student in Department of ENT and head and neck surgery, Gandhi Medical college, Bhopal(M.P.)
<b>Dr Nikhil Jaiswal</b>	Post graduate student in Department of ENT and head and neck surgery, Gandhi Medical college, Bhopal(M.P.)

### ABSTRACT

**Background & Methods:** The aim of the study is to assess microbiological & therapeutic management of parotid abscesses. Parotid abscess is a rare clinical condition & ideally required radiologic examinations for establish its diagnosis. The proper management such as administration of broad-spectrum antibiotics & surgical drainage provide a good result. **Results:** The chi-square statistic is 0.1527. The p-value is .595943. The result is not significant at  $p < .05$ . The chi-square statistic is 3.6849. The p-value is .041303. The result is not significant at  $p < .05$ . **Conclusion:** Obtaining a microbiological specimen in order to modify antibiotic therapy if necessary & a histopathological specimen to rule out a tumorous etiology is obligate. Among the different imaging methods used for the study of the parotid gland, sonography represents the method of most frequent use, for its non-invasiveness, the wide distribution, rapid & easy to perform & the low cost. It allows a detailed morphological evaluation of the gland & has an important value, complementary to clinical examination, in the study of parotid inflammatory diseases, defining the characteristics of the lesion and, in a large number of cases, also its nature.

### KEYWORDS

microbiological, therapeutic, parotid & abscesses.

#### INTRODUCTION

After an ascending infection from bacteremia or viremia via the parotid duct Stensen's duct, parotitis (PT) is an infection or inflammation of the PG [1]. As a consequence of parotitis, a parotid abscess (PA) may develop from the progressive involvement of the PG parenchyma lymph nodes in the PG & adjacent lymph nodes [2].

The parotid gland, a large salivary gland located in the retromandibular fossa, can become infected due to bacteremia, viremia, or ascending infection through Stensen's duct. Suppurative alterations can occur in the formation of an abscess if the glandular parenchyma or the intraparotid & periparotid lymph nodes are infected with bacteria or, less frequently, viruses. In the event that the process proceeds, pus will break through the capsule, infiltrate the surrounding tissue, & spread outward into the skin of the face, backward into the external auditory canal, or downward into the deep fascial planes of the neck [3].

The quick onset of erythematous swelling in the parotid region, discomfort, fever, facial asymmetry, facial nerve palsy, and, less commonly, pus or blood in the mouth cavity & dysphagia are all signs of an acute infection of the parotid gland. Abscesses, which are defined by their liquid or semiliquid composition & can result in a fistula toward the gland's surface or deepest layers, are often the result of acute inflammation. Because the infection can migrate to the head & neck, where abscesses can occur, a parotid abscess can occasionally be a potentially fatal condition [4-7].

#### MATERIAL & METHODS

All patients received a follow-up visit including sonographic re-evaluation one month after discharge from the clinic. The evaluated treatment period of this monocentric study covers a total experience period of three years. All cases of parotid abscess undergoing surgical treatment or ultrasound-guided needle aspiration (20 gauge needle) were included in this study. Surgical drainage was carried out either in local or general anesthesia (patients' choice). Surgical incisions (1 to 3 cm) were placed superficially to the sonographically identified abscess & carried out parallel to the estimated course of the relevant facial nerve branches. The abscess cavity was then identified & opened via blunt dissection. Easy flow drainages were subsequently introduced. Drainages were removed after purulent secretion had ceased.

In addition to information on patient characteristics such as age, sex, presumed disease etiology, or comorbidities, data on the abscess of the parotid gland such as imaging approach at diagnosis, localization & extent, clinical symptoms, therapy outcome (duration of hospitalization, microbiological findings were collected.

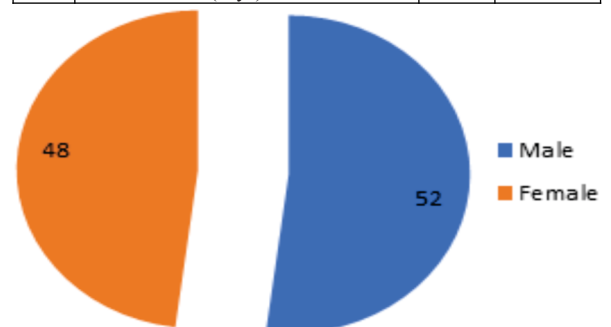
#### Exclusion Criteria:

Abscesses not involving the parotid gland or managed by conservative treatment alone.

#### RESULT

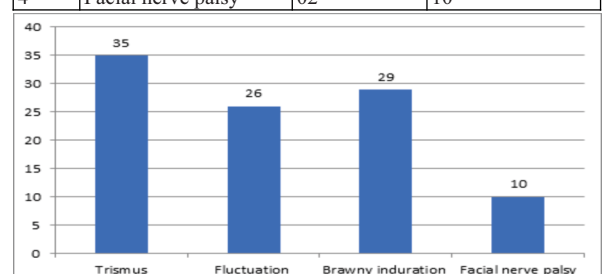
**Table No. 1: Demographic Profile**

S. No.	Gender	No.	Percentage
1	Male	11	52
2	Female	09	48
S. No.	Type of procedure	No.	Percentage
1	Surgical incision	18	93
2	Ultrasound-guided needle aspiration	02	07
3	Insertion of wound drain	19	96
4	Drain duration (days) Mean SD	3.1±2.9	



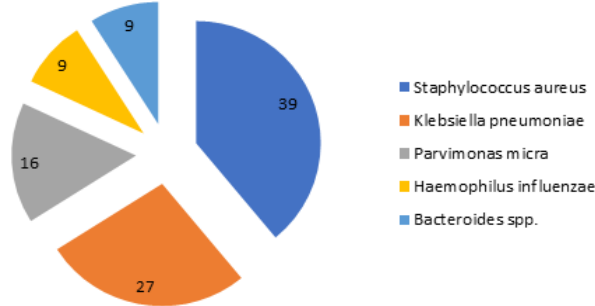
**Table No. 2: Clinical Presentation**

S. No.	Clinical	No.	Percentage
1	Trismus	07	35
2	Fluctuation	05	26
3	Brawny induration	06	29
4	Facial nerve palsy	02	10



**Table No. 3: Microbiological Profile.**

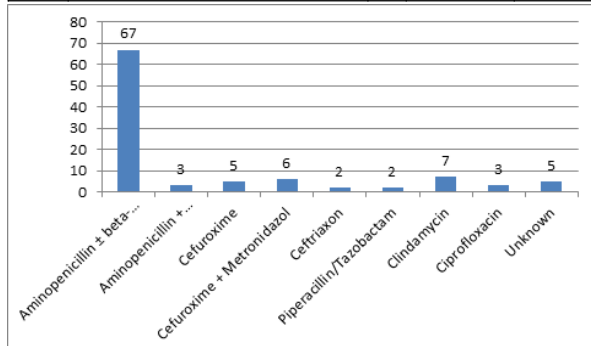
S. No.	Microbiological profile.	No.	Percentage	P Value
1	Staphylococcus aureus	08	39	.595943
2	Klebsiella pneumoniae	05	27	
3	Parvimonas micra	03	16	
4	Haemophilus influenzae	02	09	
5	Bacteroides spp.	02	09	



The chi-square statistic is 0.1527. The p-value is .595943. The result is not significant at  $p < .05$ .

**Table No. 4: Antibiotic Therapy**

S. No.	Microbiological profile.	No.	Percentage	P Value
1	Aminopenicillin ± beta-lactamase inhibitor	12	67	.041303
2	Aminopenicillin + Metronidazol	01	03	
3	Cefuroxime	01	05	
4	Cefuroxime + Metronidazol	01	06	
5	Ceftriaxon	01	02	
6	Piperacillin/Tazobactam	01	02	
7	Clindamycin	01	07	
8	Ciprofloxacin	01	03	
9	Unknown	01	05	



The chi-square statistic is 3.6849. The p-value is .041303. The result is not significant at  $p < .05$ .

**DISCUSSION**

Among the several PG illnesses are bacterial & viral infections, autoimmune conditions as well as salivary gland cancers. Thus, they can be roughly divided into two categories: neoplastic & non-neoplastic. The different microorganisms originate from the saliva generated by the salivary glands, viruses & other microbes that are present in the mouth cavity's interior. After bacteremia or viremia via the parotid duct-Stensen's duct, PT, an infection or inflammation of the PG, typically follows an ascending infection. The PA is a consequence of the continuous PT, & acute PT can develop into an abscess [8]. The development of a PT & a PA is influenced by numerous predisposing variables. The primary cause is inadequate dental hygiene. Oral cavity trauma & infection are additional significant factors.

While treatment complication rates were unevenly distributed across the three groups under study, treatment success rates overlapped across various management approaches. While some individuals treated with incision & drainage encountered complications, the most common of which was facial nerve injury, no difficulties were recorded in patients treated with aspiration or medicinal therapy [9]. Consequently, aspiration or exclusive medical therapy is typically preferred over incision & drainage due to a different complication rate, even though the success rates are identical. A more cautious first approach to PA

may appear prudent, even if this observation needs additional prospective support. With conservative treatment, the right antibiotic selection would enable sufficient medication availability, with incision & drainage serving as a fallback option for patients who do not respond to first-line therapy [10].

Salivary microbes play a significant part in the illness. PT & PA are caused by a variety of germs & viruses. Common paramyxoviruses (which cause mumps), coxsackie viruses, Epstein-Barr viruses, influenza A virus para-influenza viruses, herpes simplex virus, & cytomegalovirus are the viruses that cause PT. PT & PA are also linked to the human immune deficiency virus. The most frequent bacterium linked to acute bacterial PT & PA in both adults & children is Staphylococcus aureus. The most often isolated microbes are Streptococcus species. Anaerobic bacteria, Hemophilus, & pseudomonas are also commonly responsible for PT [11].

There are two important limitations to our study. First of all, the results are underpowered, particularly when it comes to aspiration & exclusive medical therapy, which is a reflection of the small number of patients included. On the other hand, although wide-focus case series with one or a small number of PA patients offer a thorough assessment of the literature, they also present a potential reporting bias. Second, we found that patient samples & medical treatments varied significantly. Even though we know that certain patient/disease-specific factors, like the size of the abscess, the location of the superficial versus deep lobes, the involvement of the facial nerves, co-existing sepsis, & immune status, affect treatment decisions & results, we were unable to thoroughly investigate their role because these significant factors are only occasionally & inconsistently mentioned in the reviewed articles [12]. The originally intended meta-analysis may have been deceptive due to this heterogeneity. In order to compare various studies & to question the drainage schedule, important factors are needed for management decision-making, including the location of the abscess (deep or superficial lobe), the amount of the collection, & the risk of fistulization or septicaemic sequelae.

**CONCLUSION**

Obtaining a microbiological specimen in order to modify antibiotic therapy if necessary & a histopathological specimen to rule out a tumorous etiology is obligate. Among the different imaging methods used for the study of the parotid gland, sonography represents the method of most frequent use, for its non-invasiveness, the wide distribution, rapid & easy to perform & the low cost. It allows a detailed morphological evaluation of the gland & has an important value, complementary to clinical examination, in the study of parotid inflammatory diseases, defining the characteristics of the lesion and, in a large number of cases, also its nature.

**REFERENCES**

1. Tan VE, Goh BS Parotid abscess: a five-year review— clinical presentation, diagnosis & management. J Laryngol Otol (2007)121:872–879.
2. Kishore R, Ramachandran K, Ngoma C, Morgan NJ Unusual complication of parotid abscess. J Laryngol Otol (2004) 118:388–390.
3. Prasad KC, Sreedharan S, Chakravarthy Y, Prasad SC Tuberculosis in the head & neck: experience in India. J Laryngol Otol (2007) 121:979–985.
4. Ouididi A, Ridal M, Hachimi H, El Alami MN Tuberculosis of the parotid gland. Rev Stomatol Chir Maxillofac (2006) 107:152–155.
5. Sethi A, Sareen D, Sabherwal A, Malhotra V Primary parotid tuberculosis: varied clinical presentations. Oral Dis (2006) 12:213–215.
6. Brook I. Diagnosis & management of parotitis. Arch Otolaryngol Head Neck Surg. (1992) 118:469–71. doi: 10.1001/archotol.1992.01880050015002.
7. Srivanthapoom C, Yata K. Clinical characteristics that predict parotid abscess: an observational cohort study. Ann Med Surg (Lond). (2021) 64:102230. doi: 10.1016/j.amsu.2021.102230.
8. Chi TH, Yuan CH, Chen HS. Parotid abscess: a retrospective study of 14 cases at a regional hospital in Taiwan. B-ENT 2014;10:315–8.
9. Tan VES, Goh BS. Parotid abscess: a five-year review—clinical presentation, diagnosis & management. J Laryngol Otol 2007;121:872–9.
10. Ganesh R, Leese T. Parotid abscess in Singapore. Singapore Med J 2005;46:553–6.
11. Vorrasi J, Zimberg G. Concomitant Suppurative Parotitis & Condylar Osteomyelitis. J Oral Maxillofac Surg. 2017;75:543–9. https://doi.org/10.1016/j.joms.2016.08.043.
12. Kristensen RN, Hahn CH. Facial nerve palsy caused by parotid gland abscess. J Laryngol Otol. 2012;126:322–4. https://doi.org/10.1017/S0022215111002635.