



AN OBSERVATIONAL STUDY IN MANAGEMENT OF PROXIMAL HUMERUS FRACTURE IN ELDERLY BY CONSERVATIVE METHOD AND OPERATIVE METHOD

Orthopaedics

Dr. Gopikrishnan. Junior Resident, Sri Siddhartha Medical College and Hospital, BH Road, Tumkur , Karnataka

Dr. Ravishankar J Professor, Sri Siddhartha Medical College and Hospital, BH Road, Tumkur, Karnataka

ABSTRACT

Background: Proximal humerus fractures are common in the elderly and often result from low-energy trauma. Their management remains controversial, with conservative methods avoiding surgical risks but potentially leading to stiffness, while operative fixation provides anatomical alignment but carries complication risks. **Methods:** This prospective observational study included 74 patients aged ≥ 60 years with Neer's type 2 or 3 proximal humerus fractures. Group A (n=39) underwent ORIF with PHILOS plating, while Group B (n=35) was managed conservatively with immobilization and rehabilitation. Functional outcomes were assessed using Constant-Murley Score (CMS), Visual Analogue Scale (VAS), and Quick DASH score at 6, 12, and 24 weeks. Statistical analysis was performed using Student's t-test and chi-square test. **Results:** At 24 weeks, 72.9% of operative patients achieved CMS >75 versus 55% in conservative patients (p=0.04). Operative group showed significantly greater improvement in Quick DASH (mean reduction 34.2 vs 24.1, p=0.03) and faster pain reduction (VAS mean 1.9 vs 3.1, p=0.02). Range of motion was superior in the operative group for flexion (135° vs 115°, p=0.01), abduction (130° vs 110°, p=0.02), and external rotation (45° vs 30°, p=0.01). Complications were more frequent in the operative group (15.3% vs 5.7%). **Conclusion:** Operative fixation yields faster functional recovery and pain reduction but carries higher complication rates. Conservative treatment remains a valid option for minimally displaced fractures or medically unfit patients. Individualized decision-making is essential in elderly fracture care.

KEYWORDS

INTRODUCTION

Proximal humerus fractures are the third most frequent osteoporotic fractures in the elderly, after hip and distal radius fractures, accounting for 4–5% of all fractures. These injuries can affect quality of life. Management strategies range from conservative (immobilization, physiotherapy) to operative (ORIF, arthroplasty). While operative fixation may provide better early outcomes, its benefit in long-term recovery remains debated, especially in elderly patients with comorbidities. In India, resource constraints, limited access to advanced rehabilitation, and socioeconomic challenges make treatment choices especially important. This study aimed to compare operative and conservative management outcomes in elderly Indian patients with proximal humerus fractures.

MATERIALS AND METHODS

This was a prospective observational study conducted at Sri Siddhartha Medical College Hospital, Tumkur, from March 2023 to February 2025. Seventy-four patients aged ≥ 60 years with Neer's type 2 or 3 proximal humerus fractures were included. Exclusion criteria were open or pathological fractures, polytrauma, or prior ipsilateral shoulder pathology.

Group A (operative, n=39) underwent open reduction and internal fixation (ORIF) using PHILOS plating. Group B (conservative, n=35) was managed with immobilization using an abduction brace followed by rehabilitation. Follow-up was conducted at 6, 12, and 24 weeks.

Primary outcome was functional recovery measured by Constant-Murley Score (CMS). Secondary outcomes included pain (VAS), disability (Quick DASH), range of motion, and complications. Statistical analysis was performed using Student's t-test for continuous variables and chi-square test for categorical outcomes. A p-value < 0.05 was considered significant.

RESULTS

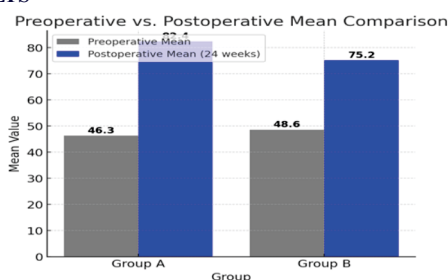


Figure 1. Preoperative vs. Postoperative Functional Score Change (Constant-Murley Score)

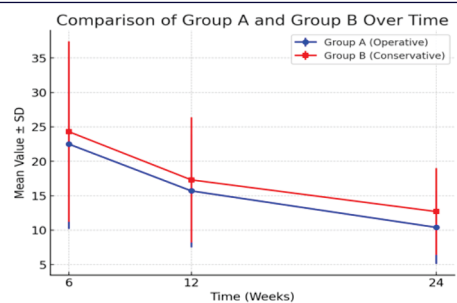


Figure 2. DASH Score (Disabilities of Arm, Shoulder, and Hand)

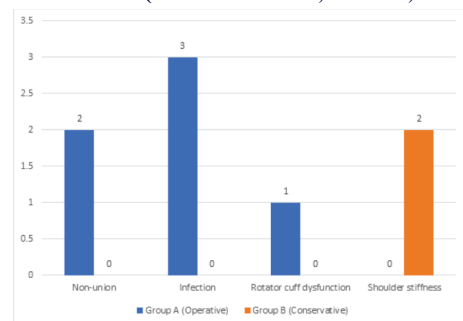


Figure 3. Complication Rates

At 24 weeks, functional recovery was significantly better in the operative group. CMS >75 was achieved by 72.9% vs 55% (p=0.04). VAS scores showed lower mean pain (1.9 vs 3.1, p=0.02), and Quick DASH indicated greater disability reduction (34.2 vs 24.1, p=0.03). ROM was significantly higher in flexion, abduction, and external rotation for operative patients. Complications were higher in the operative group, including nonunion (2), infection (3), and rotator cuff dysfunction (1). Conservative patients reported shoulder stiffness (2 cases).

DISCUSSION

Our findings confirm that operative fixation with PHILOS plating results in better short-term outcomes compared to conservative treatment in elderly patients. The significant improvement in functional scores, pain relief, and ROM highlights the advantage of surgical stabilization.

Indian literature has shown mixed outcomes. Pandey et al. (2018)

reported that plating offered better early mobility, though long-term results were similar. Tharwat (2020) observed high rates of stiffness and poor function with conservative treatment, while Japatti et al. (2021) found that although PHILOS fixation allowed early rehabilitation, conservative management produced comparable long-term outcomes with fewer complications. Our results align with these studies, emphasizing the benefit of surgery in early recovery but acknowledging complication risks.

Socioeconomic context in India also plays a role. Many elderly patients lack access to advanced rehabilitation, making conservative treatment attractive despite its limitations. Cost and availability of implants are further barriers. Therefore, individualized treatment considering patient fitness, fracture pattern, and socioeconomic background is essential.

Limitations of our study include the observational design, lack of randomization, and relatively short follow-up. Larger randomized controlled trials in Indian populations are needed to determine long-term comparative outcomes.

CONCLUSION

Operative management provides superior early functional recovery and pain reduction in elderly patients with proximal humerus fractures, but carries higher complication risks. Conservative treatment remains suitable for minimally displaced fractures or patients unfit for surgery. Decisions should be individualized, balancing expected benefits against risks.

Ethical Considerations

The study was approved by the Institutional Ethics Committee, Sri Siddhartha Medical College Hospital, Tumkur. Informed consent was obtained from all participants. No external funding was received, and authors declare no conflicts of interest.

REFERENCES

1. Court-Brown CM, Garg A, McQueen MM. The epidemiology of proximal humeral fractures. *Acta Orthop Scand*. 2001;72(4):365-71.
2. Handoll HH, Brorson S. Interventions for treating proximal humeral fractures in adults. *Cochrane Database Syst Rev*. 2015;(11):CD000434.
3. Rangan A, Handoll H, Brealey S, Jefferson L, Keding A, Martin BC, et al. Surgical vs nonsurgical treatment of adults with displaced fractures of the proximal humerus: the PROFHER randomized clinical trial. *JAMA*. 2015;313(10):1037-47.
4. Lanting B, MacDermid J, Drosdowech D, Faber KJ. Proximal humeral fractures: a systematic review. *J Shoulder Elbow Surg*. 2008;17(1):42-54.
5. Gupta AK, Harris JD, Erickson BJ, Abrams GD, Bruce B, McCormick F, et al. Surgical management of complex proximal humerus fractures. *J Orthop Trauma*. 2015;29(1):54-9.
6. Pandey R, Tripathy SK, Srivastava A, et al. Comparative study of operative vs conservative management of proximal humerus fractures in elderly. *Indian J Orthop*. 2018;52(6):588-94.
7. Tharwat M. Conservative management of proximal humerus fractures in elderly: outcomes and complications. *Int J Orthop Sci*. 2020;6(1):50-5.
8. Japatti SR, et al. Functional outcome of PHILOS plating vs conservative management in 4-part proximal humerus fractures. *J Clin Orthop Trauma*. 2021;12(4):745-50.
9. Dabhi AS, et al. Long-term outcomes of PHLIP fixation in elderly proximal humerus fractures. *Indian J Orthop*. 2019;53(4):567-73.
10. Rotman M, et al. Mortality in elderly proximal humerus fracture patients: conservative vs reverse shoulder arthroplasty. *J Shoulder Elbow Surg*. 2018;27(4):588-95.
11. Yamada K, et al. Neutral rotation brace for proximal humerus fracture: outcomes in elderly patients. *J Bone Joint Surg Am*. 2018;100(8):648-55.
12. Ramachandran S, et al. PHILOS plating in osteoporotic bone: functional outcomes. *Indian J Orthop Surg*. 2019;5(2):110-5.
13. Rikli D, et al. Conservative management algorithm for proximal humerus fractures. *Eur J Orthop Surg Traumatol*. 2020;30(6):1101-9.
14. Spolia N, Ghani S. Radiological and functional outcomes of conservative management of proximal humerus fractures in elderly. *Cureus*. 2021;13(7):e16420.
15. Walter WL, et al. Trends and complications of operative vs non-operative management of proximal humerus fractures. *Bone Joint J*. 2023;105-B(1):45-53.