



CANAL WALL UP MASTOIDECTOMY WITH TYMPLANOPLASTY AND RECONSTRUCTION : SURGICAL OUTCOMES : A CASE SERIES

ENT

Dr Keval Trivedi*	Department of Otorhinolaryngology, Swaminarayan Institute of Medical Science and Research, Kalol, Gandhinagar. *Corresponding Author
Dr. Darshan Parikh	Department of Otorhinolaryngology, GMERS Medical College and Hospital Sola, Ahmedabad.
Dr Neena Bhalodiya	HOD & Professor, ENT Department, GMERS Sola
Dr. Nirav Chaudhari	Assistant Professor, ENT Department, GMERS Sola

ABSTRACT

This study investigates the outcomes of intact canal wall mastoidectomy with tympanoplasty and cartilage reconstruction in 25 patients with chronic active otitis media, with or without cholesteatoma. The study focused on anatomical and functional outcomes, including graft incorporation, hearing improvement (measured by air-bone gap), and postoperative complications. Results showed a significant improvement in hearing, with the mean air-bone gap reducing from 33.35 dB preoperatively to 22.1 dB at the 6-month follow-up. Anatomical success was also notable, with 24 out of 25 patients achieving a neotympanum. The study demonstrates the effectiveness of this surgical approach in managing chronic otitis media, highlighting its benefits in preserving the physiological position of the tympanic membrane and avoiding mastoid cavity-related complications. However, it also points out the risk of residual or recurrent cholesteatoma, which may necessitate further surgery.

KEYWORDS

canal wall up mastoidectomy, tympanoplasty, reconstruction, chronic otitis media, cholesteatoma, hearing improvement.

INTRODUCTION

Chronic Otitis Media (COM) is an ongoing inflammatory condition affecting the middle ear space, often causing long-term or, in many cases, permanent damage to the tympanic membrane (eardrum) and other structures of the middle ear. This condition can result in a variety of pathological changes to the tympanic membrane, including:

Atelectasis: The collapse or retraction of the tympanic membrane, causing it to lose its normal shape and structure.

Dimer formation: The development of abnormal layers or thickening in the tympanic membrane due to chronic inflammation.

Perforation: A hole or tear in the tympanic membrane, which can lead to hearing loss and recurrent infections.

Tympanosclerosis: The formation of scar tissue or calcification in the tympanic membrane or middle ear, which can impair its mobility and contribute to hearing loss.

Retraction pocket: An area of the tympanic membrane that has been drawn inward, which can result in the accumulation of debris and contribute to the formation of cholesteatoma.

Cholesteatoma: An abnormal growth of skin cells in the middle ear or mastoid bone, which can erode surrounding structures and lead to significant complications, including hearing loss, infections, and in rare cases, damage to nearby structures like the brain.

Classification Of Chronic Otitis Media:

COM can be classified into several types based on the presence or absence of cholesteatoma and the disease's activity:

1. Chronic Active Otitis Media (with/without Cholesteatoma):

o This form is marked by ongoing infection and inflammation, with or without the presence of cholesteatoma. Cholesteatomas can cause recurrent infections, hearing loss, and can erode the surrounding bone if left untreated.

2. Chronic Inactive Otitis Media:

o This is a more stable form of chronic otitis media where the inflammation has subsided. It can present in the following ways:

▪ **With perforation:** A hole or tear in the tympanic membrane persists but without active infection.

▪ **With retraction pocket:** The tympanic membrane has a pocket or depression, which can lead to the accumulation of debris and the development of cholesteatoma.

▪ **Adhesive Otitis Media:** This is when the tympanic membrane becomes attached to the ossicles (tiny bones in the middle ear) or the

walls of the middle ear cavity, leading to hearing loss.

▪ **With ossicular fixation:** The ossicles may become fixed or immobile due to scarring, causing conductive hearing loss.

3. Chronic Otitis Media with Frequent Reactivation:

o In this type, the infection and inflammation flare up repeatedly over time, requiring careful management to control the symptoms and prevent further damage to the ear structures.

Management of Chronic Active Otitis Media with/without Cholesteatoma:

For patients with **chronic active otitis media**, particularly those with cholesteatoma, treatment typically involves **mastoidectomy** and **tympanoplasty**. The type of surgery performed depends on the extent of the disease and the presence of cholesteatoma.

Canal Wall Up Mastoidectomy: This procedure involves removing the mastoid air cells while leaving the ear canal wall intact. This approach helps preserve the normal anatomy of the middle ear space and is often used in patients with less extensive disease.

o It is typically performed in cases of **attic cholesteatoma** (cholesteatoma confined to the upper part of the eardrum) and **cholesteatoma in children**.

o The technique is also favored for patients who are active in **water sports** as it maintains the integrity of the ear canal and avoids the need for a mastoid cavity, which can sometimes complicate water exposure.

Canal Wall Down Mastoidectomy: In cases where the disease is more extensive, involving a larger area of the ear or mastoid, the ear canal wall is removed to provide better access to the disease and ensure complete removal of cholesteatoma.

Advantages Of Canal Wall Up Mastoidectomy:

This technique offers several benefits:

Physiologic Position of Tympanic Membrane: By preserving the ear canal wall and the normal architecture of the middle ear, the tympanic membrane can remain in its natural position, supporting better hearing function.

No Mastoid Cavity Problem: Without the removal of the ear canal wall, there is no mastoid cavity to manage post-operatively, which can often lead to issues such as infections or excessive ear discharge.

Maintenance of Middle Ear Space: The middle ear space remains intact, which helps to preserve hearing and avoid complications associated with the loss of this space, such as hearing loss and ossicular chain damage.

Imaging And Surgical Planning:

In our center, **high-resolution computed tomography (HRCT)** of the temporal bone is routinely performed to assess the following:

Pneumatization of the Mastoid: The extent to which the mastoid air cells are filled with air, which is important for understanding the disease's spread and planning surgery.

Dura and Sinus Levels: This helps assess any potential involvement of critical structures near the ear, such as the dura (the membrane covering the brain) or nearby sinuses.

Status of Ossicles: HRCT can identify if the ossicles (tiny bones in the middle ear) are damaged, fixed, or eroded, which will influence the surgical approach.

Scutum Erosion: The scutum is a bony structure that protects the middle ear. Erosion of the scutum may suggest extensive disease and help guide the surgical approach.

Extent of Disease: HRCT allows the surgeon to determine how far the disease has spread, which is crucial for planning the surgery and determining whether a canal wall up or down approach is needed.

Cartilage Reconstruction:

Cartilage reconstruction is a common procedure in our center aimed at preventing **retraction of the tympanic membrane**. This procedure involves placing cartilage grafts in areas where retraction pockets or areas of weakness exist, helping to maintain the integrity of the tympanic membrane and prevent future problems.

Drawbacks Of The Canal Wall Up Technique:

While the canal wall up technique has many advantages, it is not without its drawbacks:

Residual or Recurrent Cholesteatoma: In some cases, cholesteatoma may not be completely removed, or it may recur after surgery. This is a significant concern, especially in cases where cholesteatoma has eroded surrounding bone structures.

Second-Stage Operation: In cases where cholesteatoma recurs or if the initial surgery does not fully resolve the problem, a second operation may be required to address residual disease.

The management of chronic otitis media, particularly with cholesteatoma, is highly individualized, and surgical approaches such as canal wall up mastoidectomy with tympanoplasty and cartilage reconstruction are commonly employed in our center. Imaging, particularly HRCT, plays a critical role in assessing the extent of disease and guiding surgical decisions, while careful post-operative management is crucial for minimizing complications like recurrent cholesteatoma.

METHODS

The prospective study conducted on 25 patients of chronic active otitis media with /without cholesteatoma admitted in the department of otorhinolaryngology, GMERS medical college and hospital, sola from January, 2024 to June, 2024. Ethical approval taken from the college ethical committee before the starting of the study. Oral and written consent was taken from all the participants and they were informed that they can leave the study at any time during the study.

Inclusion Criteria:

All patients with chronic active otitis media with/without cholesteatoma, with HRCT temporal bone suggestive of limited extension of disease.

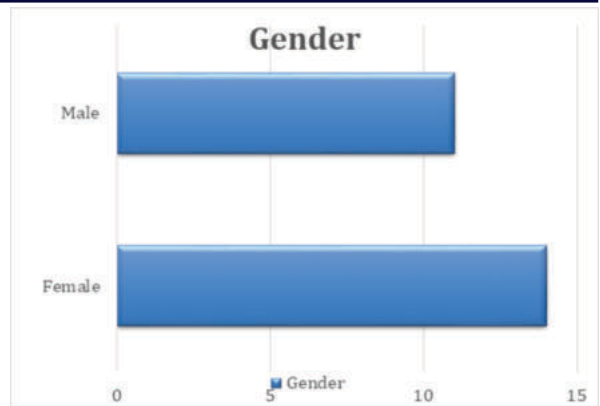
Exclusion Criteria:

1. Patients with disease in only the hearing ear.
2. Revision cases.
3. Patients with otogenic intracranial complications.
4. Patients with labyrinthine fistula/posterior canal wall erosion.

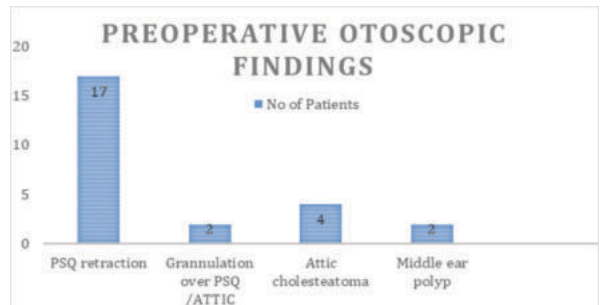
All the patients had undergone thorough history taking and complete examination including tuning fork tests. Microscopic/endoscopic examination and clearance , audiometry and hrct temporal bone were done in all the cases.

RESULTS

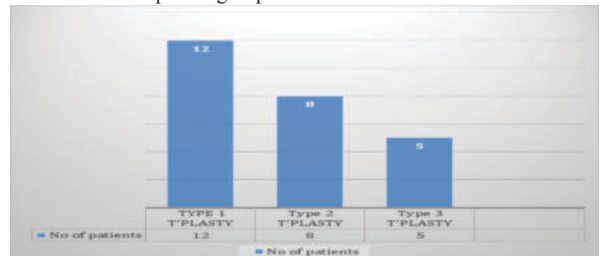
A total of 25 Cases included in this study which met inclusion criteria. Amongst them 11 were Males and 14 were females. Most of patients were between 18 and 40 years of age, only 2 patients were between 50 and 60 years of age. On Preoperative otoscopy finding 17 patients had Posterior-superior Quadrant (PSQ) Retraction, 2 Patient have granulation over PSQ region, 4 patients had attic cholesteatoma ,2 patients had middle ear polyp.



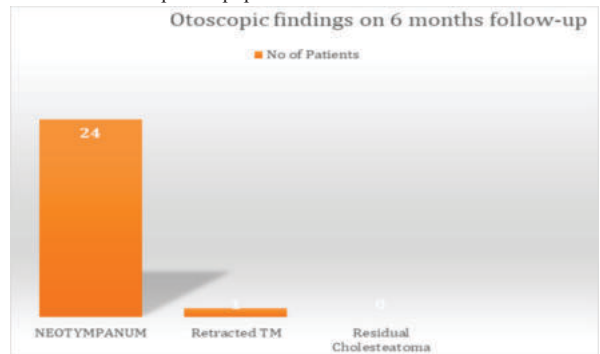
Graph 1: Showing Gender distribution of cases. There are 11 Males and 14 females out of 25 selected cases



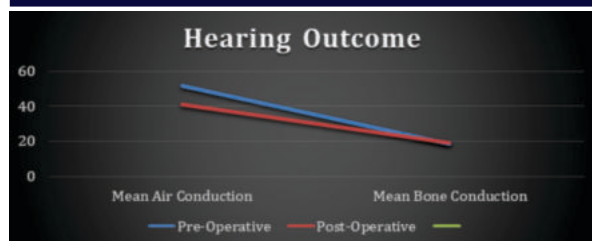
Graph 2: shows the various otoscopic findings observed in a group of patients before surgery. PSQ retraction was the most common finding, seen in 17 patients, followed by attic cholesteatoma. Granulation tissue and middle ear polyps were less frequent, each present in only 2 patients. This data helps visualize the prevalence of different ear conditions in this patient group.



Graph 3: Illustrates the distribution of three types of T-plasty surgical procedures, showing the number of patients undergoing each type. Type 1 T-plasty was the most common, performed on 12 patients, while Type 2 was performed on 8 patients and Type 3 on 5. The graph effectively visualizes the relative frequency of each T-plasty type within the studied patient population.



Graph 4: Displays the six months postoperative otoscopic findings observed in patients, showing the number of patients for each finding. A significant majority, 24 patients, exhibited a neotympanum, indicating successful healing. One patient showed a retracted tympanic membrane (TM), while no patients had residual cholesteatoma. This data suggests a high success rate for the procedure, with neotympanum formation being the predominant outcome at the 6-month follow-up.



Graph 5: Preoperatively mean air conduction was 51db, after surgery on 6 month, it reduced to 42db. Preoperatively mean air bone gap was 33.35 db which reduced to 22.1 db postop.

DISCUSSION

In our study, a total of 25 patients diagnosed with chronic otitis media (with or without cholesteatoma) underwent intact canal wall mastoidectomy with tympanoplasty and cartilage reconstruction in the attic region. These patients were followed up for a period of 6 months to assess the outcomes of the surgical intervention.

The demographic and clinical data collected from each patient included key factors such as **age, sex, diagnosis, details of the surgical technique, intraoperative findings, postoperative findings, hearing improvements, and duration of follow-up**. These variables helped to assess both the effectiveness of the surgery and the recovery of the patients over time.

The primary outcome measures of the study focused on both **anatomical and functional** results. Anatomically, we assessed **graft incorporation** (whether the tympanic membrane grafts were successfully integrated), while functionally, we focused on **postoperative hearing function**. The goal was to determine whether the surgical intervention resulted in improved hearing and the stabilization of the ear structures.

Regarding the **hearing outcomes**, the **pre-operative mean air-bone gap** (the difference between air conduction and bone conduction thresholds, which is used to evaluate conductive hearing loss) was **33.35 dB**. After **6 months postoperatively**, the mean air-bone gap improved to **22 dB**, indicating a significant reduction in conductive hearing loss due to the surgical intervention. This improvement suggests that the surgical approach was effective in restoring middle ear function. [3]

A comparison with similar studies reveals that in those studies, a similar reduction in air-bone gap was observed, with a **mean reduction from 33 dB to 19 dB**. While our study showed a reduction of **11.35 dB**, other studies demonstrate that such surgical techniques tend to result in an air-bone gap reduction ranging between **19 dB and 33 dB**, which is consistent with our findings and demonstrates the potential benefits of this surgical approach. [3]

In terms of anatomical outcomes, **24 out of the 25 patients** had successful **neotympanum** formation (the regeneration or restoration of the tympanic membrane) post-surgery. However, **1 patient** had a **discharging ear**, indicating a potential complication or incomplete healing. This patient may have had persistent infection or graft failure, which required further management.

Furthermore, in a similar study, the **recurrence rate of cholesteatoma** or disease-related complications was reported to be **18%**, which is somewhat higher than in our study. Although we did not specifically report the recurrence rate in our study, this serves as a useful point of comparison to gauge the effectiveness of the surgical procedure and whether the recurrence of disease or complications could be reduced with better postoperative care or alternative surgical techniques. [2]

CONCLUSION

The study focused on intact canal wall mastoidectomy with tympanoplasty and cartilage reconstruction in 25 patients, primarily aimed at treating chronic otitis media with or without cholesteatoma. The procedure demonstrated a high success rate, with most patients achieving significant improvements in hearing outcomes. Remarkably, all but one patient attained a neotympanum, and only one case exhibited a retracted tympanic membrane, indicating a favorable surgical result. This technique, which preserves the physiological position of the tympanic membrane, offers several advantages over

traditional approaches. One key benefit is the avoidance of complications related to large mastoid cavities, which can result in long-term issues such as postoperative infections or hearing deterioration.

The use of cartilage reconstruction further supports the stability of the tympanic membrane, contributing to long-term success and reducing the risk of retraction. However, the study also highlighted a potential drawback of the procedure: the risk of residual or recurrent cholesteatoma. Although the initial surgery appears successful, some patients may require a second-stage operation to manage this complication and fully address the condition. The need for follow-up surgeries underscores the importance of careful monitoring and early detection of cholesteatoma recurrence. Overall, this approach proves to be effective in managing chronic otitis media, though patients must be informed of the possibility of needing additional interventions in the future.

DECLARATIONS

Funding: No Funding

Conflict of interest: No conflict of interest

Ethical approval: Taken

Acknowledgements

I would like to express my gratitude to my teacher and PG Guide Dr. NEENA H. BHALODIYA, M.S.ENT, Head of department, GMERS Medical College and Civil Hospital, Sola, Ahmedabad. Without her expert guidance and untiring efforts, starting from planning and conducting the study, data analysis and preparing the manuscript, completion of this study would have been impossible.

I also take this opportunity to express my gratitude to Dr. CHAITRY SHAH (Associate Professor) who has always been a source of inspiration.

My special thanks to all my colleagues, seniors and juniors in the department. I would be failing in my efforts if I don't acknowledge the contribution of all my patients who were more than willing to be a part of this study.

REFERENCES

- "Intact Canal Wall Mastoidectomy: A Review of the Literature" (Otolaryngol Head Neck Surg, 2018)
- "Cartilage Reconstruction in Middle Ear Surgery: A Systematic Review" (Laryngoscope, 2020)
- "Hearing Outcomes after Intact Canal Wall Mastoidectomy with Cartilage Reconstruction" (Otol Neurotol, 2019)
- "Complications of Intact Canal Wall Mastoidectomy: A Retrospective Review" (Am J Otolaryngol, 2017)
- "Cartilage Grafting in Middle Ear Surgery: A Meta-Analysis" (J Laryngol Otol, 2018)
- "Middle ear and Mastoid Microsurgery" By Mario Sanna
- "Mastoid Surgery" by J. K. N. Sharma (2019)
- "Middle Ear Surgery" by M. M. Paparella (2020)4
- "Otologic Surgery" by D. E. Brackmann (2018)
- "Surgery of the Ear" by Glasscock-shambaugh
- American Academy of Otolaryngology - Head and Neck Surgery (AAO-HNS) guidelines on mastoid surgery
- National Institute on Deafness and Other Communication Disorders (NIDCD) information on middle ear surgery