



SKIN FRAGILITY–WOOLLY HAIR SYNDROME: A RARE GENODERMATOSIS

Dermatology

Dr. Bommaka Sruthi*

Junior Resident. *Corresponding Author

Dr. Suresh Kumar K

Professor and HOD.

Dr. Rajashekar T. S Professor

Dr. Madhukiran C Assistant Professor

ABSTRACT

Skin Fragility–Woolly Hair Syndrome (SF-WHS) is an exceptionally rare autosomal recessive genodermatosis caused by mutations in the desmoplakin (DSP) gene, a key component of desmosomes and intermediate filament anchorage. The condition is characterized by the coexistence of trauma-induced skin fragility and woolly, tightly curled hair. To date, only a few dozen cases have been documented worldwide, with very few reported from India. We report the case of a 27-year-old female who presented with early-onset woolly hair and recurrent erosions following minor trauma, without cardiac or mucosal involvement. Recognition of such cases is essential to broaden the phenotypic spectrum of desmoplakin-related disorders and to aid in genetic counseling and early intervention.

KEYWORDS

Skin fragility- woolly hair syndrome, Desmoplakin

INTRODUCTION

Skin Fragility–Woolly Hair Syndrome (SF-WHS) is an extremely rare inherited disorder caused by biallelic mutations in the DSP gene, which encodes desmoplakin, a structural protein essential for desmosome-mediated adhesion between keratinocytes(1,2). Clinically, SF-WHS is characterized by a unique combination of trauma-induced skin blistering or erosions and short, tightly curled “woolly” hair. Some patients exhibit cardiac abnormalities, as desmoplakin also plays a crucial role in myocardial integrity (3) however, cutaneous-only variants are increasingly recognized(4). Only a limited number of SF-WHS cases have been reported globally, and reports from India remain scarce(2) making each case valuable for understanding the clinical variability and natural history of this disorder.

CASE STUDY

A 27-year-old female born out of second degree consanguineous marriage presented with early-onset woolly, tightly curled scalp hair since infancy, and a history of recurrent blisters and erosions appearing after minor trauma. The lesions typically healed with post-inflammatory dyspigmentation, suggestive of cutaneous fragility.

Cutaneous examination revealed multiple crusted erosions over the lower abdomen, medial, anterior, posterior aspects of both thighs, and buttocks. A few erosions were also noted on the medial thighs. The scalp hair appeared short, tightly curled, and irregular, giving a wool-like appearance. Nails, teeth, and mucosae were normal.

Systemic evaluation, including cardiac assessment, revealed no abnormalities. Histopathological examination of lesional skin demonstrated epidermal cleavage with features consistent with a desmosomal defect, correlating with a desmoplakin mutation-related pathology.

Based on the clinical phenotype, absence of cardiac involvement, and histopathologic findings, a diagnosis of Skin Fragility–Woolly Hair Syndrome was established.

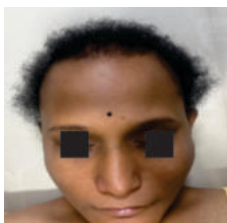

Figure 1 short, tight and irregularly curled hair giving wool like appearance present over scalp.

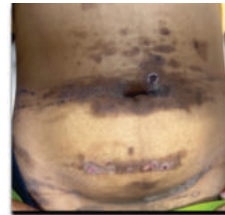

Fig 2 Multiple crusted erosions present over lower abdomen, multiple post inflammatory hyper pigmented macules present over abdomen.

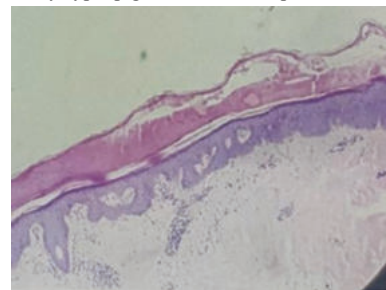


Figure 3 Shows: Epidermis showing subcorneal blistering containing coagulated plasma, degenerated inflammatory cells. Perivascular and interstitial mixed inflammatory cells which includes lymphocytes, neutrophils and few eosinophils in upper dermis.

DISCUSSION

Skin Fragility–Woolly Hair Syndrome (SF-WHS) is an extremely rare autosomal recessive genodermatosis, first described by Whittock et al. in 2002, resulting from biallelic mutations in the desmoplakin (DSP) gene, located on chromosome 6p24(1). Desmoplakin is a critical desmosomal protein that anchors keratin intermediate filaments to desmosomal plaques, thereby maintaining epidermal cohesion, hair shaft integrity, and cardiac muscle stability(3). Mutations in this gene disrupt cell adhesion, leading to the characteristic combination of cutaneous fragility and woolly hair.

Clinically, SF-WHS manifests as early-onset tightly curled, woolly scalp hair and recurrent erosions or blisters arising from minor trauma(2,4). Lesions typically heal with post-inflammatory dyspigmentation or atrophy, reflecting mechanical fragility of the epidermis. Unlike related desmosomal disorders, such as Carvajal or Naxos syndrome, which show cardiomyopathy and palmoplantar keratoderma, SF-WHS may present as an isolated cutaneous phenotype without extracutaneous involvement (3,4). The absence of nail, mucosal, or cardiac abnormalities in our patient expands the phenotypic spectrum of desmoplakin-related disorders.

Histopathologically, skin biopsies in SF-WHS show **epidermal cleavage within the lower spinous layer**, consistent with **desmosomal detachment**, along with **mild acantholysis** and **minimal inflammatory infiltrate** (3). **Electron microscopy** reveals **reduction or absence of desmosomes** and **tonofilament aggregation**, confirming a structural defect in desmoplakin. When available, **genetic testing for DSP mutations** can provide definitive diagnosis and allow for **carrier detection** and **genetic counselling** (4). The **differential diagnoses** for SF-WHS include other **woolly hair syndromes** (such as familial woolly hair, Naxos disease, Carvajal syndrome) and **epidermolysis bullosa simplex**. However, the combination of **trauma-induced erosions**, **histologic evidence of desmosomal cleavage**, and **absence of systemic findings** helps establish the diagnosis.

Management is primarily **symptomatic and preventive**. Patients should be advised to **avoid frictional trauma**, use **non-irritant cleansers**, and apply **emollients** to maintain barrier function. Secondary bacterial infection should be treated promptly with **topical or systemic antibiotics**. **Gentle hair care practices** are encouraged to prevent hair breakage. **Genetic counseling** remains a key aspect, especially for families with consanguinity or known carrier status.

Although SF-WHS is **non-progressive**, **long-term follow-up** is recommended to monitor for any **late-onset cardiac involvement**, given the shared desmosomal pathogenesis with arrhythmogenic right ventricular cardiomyopathy (ARVC).

This case is significant as it demonstrates an **isolated cutaneous variant** of SF-WHS in an adult female with **no systemic features**, contributing to the **broader phenotypic understanding** of **desmoplakin mutation disorders** and underscoring the role of **hair anomalies as diagnostic clues** to underlying genodermatoses.

CONCLUSION:

Skin Fragility–Woolly Hair Syndrome represents a **distinct desmosomal disorder** characterized by the **coexistence of trauma-induced skin fragility and woolly hair**. The present case highlights an **isolated dermatological phenotype** without cardiac or mucosal involvement, emphasizing the **clinical variability** of **DSP mutations**. Recognition of such cases is crucial for **accurate diagnosis**, **appropriate counseling**, and **anticipatory guidance**, including **periodic cardiac evaluation**.

Early identification and reporting of such **rare genodermatoses** enrich the current understanding of **desmosomal biology** and aid in improving **genotype–phenotype correlations**.

REFERENCES:

1. Whittock NV, Bower C, Ashton GH, O'Toole EA, Attwood A, Blaydon DC, et al. Compound heterozygosity for nonsense and missense mutations in desmoplakin underlies skin fragility–woolly hair syndrome. *J Invest Dermatol.* 2002;118(2):232–s8.
2. Peter DCV, AlAboud K, George S, Thomas M. Skin fragility, woolly hair syndrome with a desmoplakin mutation: a case from India. *Int J Dermatol.* 2018;57(10):1236–39.
3. Al-Owain M, Wakil SM, Al-Fadhel M, Al-Ghamdi MH, Al-Dossari H, Al-Sayed M. Novel homozygous mutation in DSP causing skin fragility–woolly hair syndrome. *Clin Genet.* 2011;80(4):377–80.
4. Yang M, Zhang X, Li Y, Chen H, Wang J, Liu Y. Novel compound heterozygous variants of DSP causing skin fragility–woolly hair syndrome. *Case Rep Dermatol.* 2025;17(1):464–70.