



MAXILLARY HARD TISSUE AUGMENTATION-AN OVERVIEW

Oral & Maxillofacial Surgery

Dr. Akshar

Tareshkumar

Patel*

Consultant Oral And Maxillofacial Surgeon*Corresponding Author

ABSTRACT

Bone augmentation procedures in maxillary edentulous jaws are often necessary for placement of endosseous dental implants as, at times, available bone height is limited due to ridge resorption. Hence, different surgical techniques are currently being used to augment the maxilla such as Ridge split osteotomy, Interpositional grafts, Sinus lift and inlay bone grafts, vertical ridge augmentation, horizontal ridge augmentation, distraction osteogenesis, onlay bone grafting, and guided bone regeneration(GBR), etc. In this article we will discuss about maxillary hard tissue augmentation using these surgical techniques.

KEYWORDS

INTRODUCTION

The treatment of the severely resorbed maxilla with bone grafting is a very demanding and expensive procedure for the patient and is also demanding for the clinician. There many procedures done for maxillary augmentation such as

- 1) Ridge split osteoplasty,
- 2) Onlay grafts,
- 3) Interpositional grafts,
- 4) Sinus lifts and inlay bone grafts
- 5) Guided bone regeneration and
- 6) Distraction osteogenesis.

DETAILED EXPLANATION IS AS BELOW:

1) Ridge Split Osteoplasty

Ridge-splitting procedures geared toward expanding the knife-edged alveolus in a buccolingual direction help to restore the crucial endosteal component of the alveolus that is associated with preservation and response to trans-ligamentary loading and maintains the alveolus during the dentate state. Replacement of this tissue allows for dental implant stimulation of the surrounding bone that can best mimic this situation and preserve the existing alveolus and possibly stimulate future bone growth. Adequate dimensions, however, should exist that allow for a midcrestal osteotomy to separate the buccal and lingual cortices (Figures 1 and 2). A labial incision originates just lateral to the vestibule and continues suprapariosteally to a few millimeters below the crest of the alveolus. A subperiosteal flap then originates exposing the underlying crest. Copious irrigation accompanies an osteotomy circumferentially anterior to the maxillary sinus from one side to the other. Mobilization of the labial segment can be achieved with careful manipulation with an osteotome, taking care to maintain the labial periosteal attachment. An interpositional cancellous graft can then be placed in the resulting defect, replacing the lost bony mass. Closure of the incision is away from the graft site and usually requires suturing of the flap edge to the periosteum with subsequent granulation of the remainder of the exposed tissue bed. Endosteal implants can be placed approximately 3 to 4 months later; waiting this length of time has been shown to increase overall long-term implant success. (1)

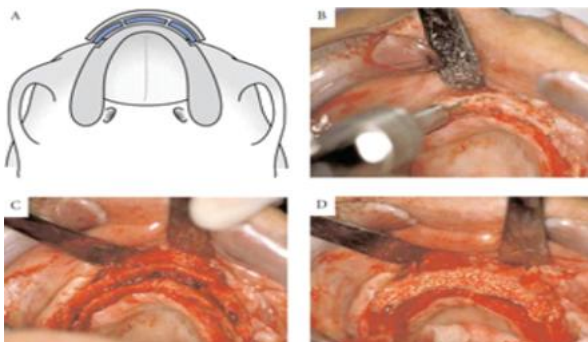


Figure 1: A TO D:

A, Diagram shows bone cuts and the position of the buccal fragment after the osteotomy. The bone grafts are already in position.

B, Handpiece in position with small crosscut fissure bur performing osteotomy along the crest of the alveolar ridge.

C, Osteotomy completed and buccal plate outfractured to complete ridge split. The defect is now ready for interpositional graft to maintain the increased buccolingual width.

D, Completed ridge split with interpositional corticocancellous and allogeneic bone used to fill the defect and maintain the increased buccolingual dimension. (10)

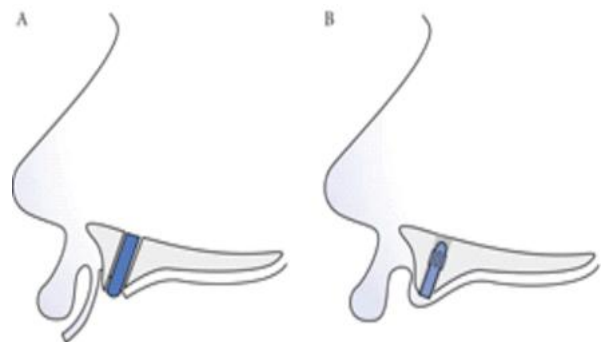


Figure 2 : A, Schematic drawing of the bone graft position in relation to the nasal floor. Note the reflected buccal periosteum after palatal incisions.

B, Position of endosteal implants after the bone graft has healed.

2) Onlay Grafts

When clinical loss of the alveolar ridge and palatal vault occur (Cawood and Howell Class V), vertical onlay augmentation of the maxilla is indicated. Initial attempts at alveolar restoration involved the use of autogenous rib grafts; however, currently corticocancellous blocks of iliac crest are the source of choice. (3)

In a similar approach to that described above, the crest of the alveolus is exposed and grafts are secured with 1.5 to 2.0 mm screws. (6)

Studies show increased success with implant placement in a second stage procedure rather than using them as sources of retention and stabilization of the graft and alveolus at the time of augmentation. (5)

Implant success ranges from > 90% initially (11) and falls to 75% at 3 years post operatively (7)

Implant success is almost 50% at 5 years postoperatively. Implant

success may be directly proportional to the degree of graft maturation and incorporation at the time of implant placement.(4)

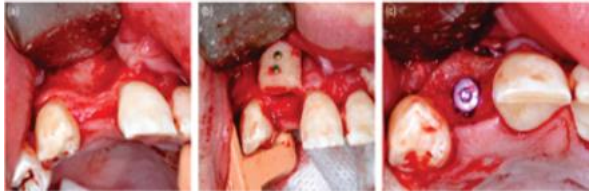

Figure 3: Anterior maxillary ramus graft: (a) missing congenital lateral incisor, (b) placement of ramus veneer graft, (c) placement of titanium implant several months later.(12)

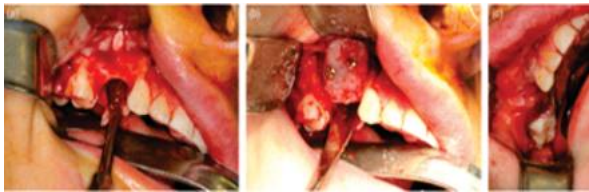


Figure 4: Anterior maxillary localized block graft: (a) maxillary defect, (b) placement of block graft, (c) tension-free closure (12)

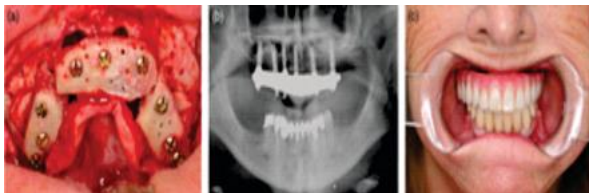

Figure 5: Anterior and posterior distant (extraoral) maxillary block grafts: (a) iliac crest block grafts, (b) radiograph of dental implants, (c) dental prosthesis 5 years after grafting. (12)

3) Interpositional Grafts

Interpositional grafts are indicated when adequate palatal vault height exists in the face of severe alveolar atrophy (Cawood and Howell Class VI) posteriorly, resulting in an increased interarch space.(10)

Because this method involves a Le Fort I osteotomy, true skeletal discrepancies between the maxilla and mandible can be corrected at the time of surgery. The improvement of maxillary dimensions as a result of interpositional grafts may obviate the need for future soft tissue recontouring to provide adequate relief for prosthetic rehabilitation.(9)

Although early studies entertained the simultaneous placement of dental implants at the time of augmentation, recently several authors have demonstrated better success rates for implants placed in a second-stage procedure; this alleviates the need for excessive tissue reflection for implant placement and allows for a more accurate placement at a later date.(3)

A relapse of 1 to 2 mm has been demonstrated in interpositional grafts using the Le Fort I technique with rigid fixation. (8)

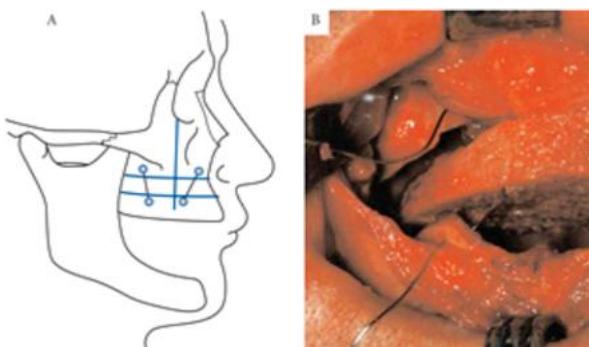


Figure 6: Graphic (A) and clinical presentation (B) of interpositional iliac crest grafts to the maxilla (2)

4) Sinus Lifts and Inlay Bone Grafts

Sinus lift procedures and inlay bone grafting play a valuable role in the subsequent implant restoration of a maxilla that has atrophied

posteriorly and is unable to accommodate implant placement owing to the proximity of the maxillary sinus to the alveolar crest. Incisions just palatal to the alveolar crest are created, followed by subperiosteal exposure of the anterior maxilla. A cortical window 2 to 3 mm above the sinus floor is created with the use of a round diamond bur down to the membrane of the sinus. Careful infracture of the window with dissection of the sinus membrane off the sinus floor creates the space necessary for graft placement; the lateral maxillary wall is the ceiling for the subsequent graft (Figure 7). Corticocancellous blocks or particulate bone may be placed in the resulting defect. Tears in the membrane may necessitate coverage with collagen tape to prevent extrusion and migration of particulate grafts through the perforations. Although implant placement can proceed simultaneously when 4 to 5 mm of native alveolus exists, we have found few cases where the alveolus meets these requirements and therefore elect to place implants approximately 6 months later. Block and Kent have reported an 87% success rate with sinus-grafting procedures. (1)

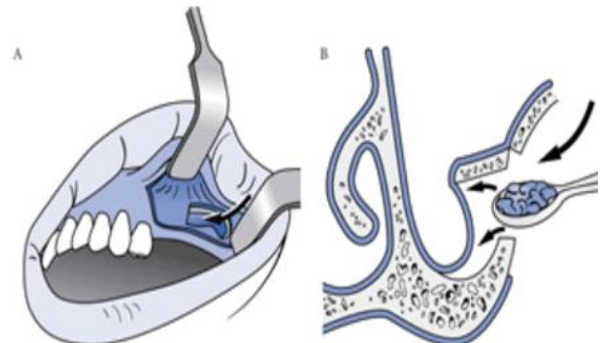


Figure 7: A, Sinus lift procedure with an inward trapdoor fracture of lateral sinus wall. B, Graft material is placed on the floor of the sinus. The sinus lining should not be perforated during the elevation of the bone. (2)

5) Guided bone regeneration (GBR)

The science of bone regeneration has evolved into a highly complex and specialized area of study. The understanding of the molecular and cellular cascade of events involved in bone repair and regeneration continues to evolve at a rapid pace. Promising technologies, such as tissue engineering, recombinant growth factors, and gene therapy, offer tremendous hope for the future. Notwithstanding these recent advances, the principle of guided bone regeneration continues to play a major role in contemporary clinical practice and is particularly important in the management of localized bone defects associated with dental implants. The development of guided bone regeneration has a long and interesting history. As early as 1944, the principle of compartmentalization to achieve regeneration of specific tissues was under investigation. Researchers in the field of neural regeneration, using allogeneic aorta as a protective conduit over the cut ends of a peripheral nerve, reported regeneration of nerve fibres, even in the absence of a distal segment. It had previously been observed that nerve regeneration was prevented by fibrous tissue ingrowth and scarring.(13)

In 1957, Murray found that if a section of cortical bone was removed from the dog ilium and subsequently protected with a plastic cage, the interior of the cage would fill with new bone. Murray also found that if the three-dimensional design of the cage permitted, new bone would form on the cortical surface surrounding the defect and also proliferate vertically within the cage.(14)

Hurley et al., seeking to improve bone regeneration in spinal fusion, found that insertion of a cellulose acetate filter over the grafted site effectively excluded the overlying, fully differentiated tissues from the bony defects.(15)

Subsequently, Linghorne reported on tube-guided osteogenesis in fracture repair. In this study, discontinuity defects 15 mm in length were produced in the fibulae of dogs by removal of a section of bone and periosteum. A hollow polyethylene tube was then placed across the gap, connecting the cut ends of the bone. It was demonstrated that in the presence of the tube, osseous healing occurred instead of a fibrous union.(16)

The use of guided bone regeneration in the realm of oral surgery was

first reported by Boyne, who used a cellulose acetate filter to regenerate bone in surgically created mandibular defects.(17)

Using a slightly different material, Kahnberg later described the successful use of perforated Teflon mantle leaf on regeneration of mandibular bone defects in rabbits(18)

The potential for the regeneration of specific, differentiated periodontal structures was described by Linghorne and O'Connell in 1950.(31,32)

The use of GTR membranes in implantology, more specifically the concept of guided bone regeneration (GBR) or osteopromotion, was recognized as a method of alveolar ridge augmentation and for managing localized defects associated with the placement of dental implants.(21)

These concepts would fundamentally change the practice of implantology, increasing the ability of clinicians to provide more predictable restoration of form, function, and aesthetics through more ideal implant placement.(34-36)

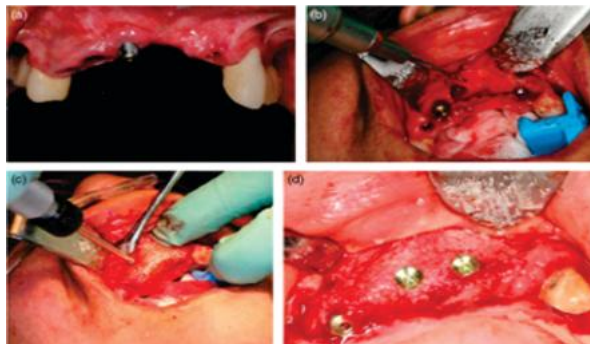


Figure 8: Anterior maxilla: GBR: (a) anterior maxillary defect with failing implant, (b) maxillary defect, (c) placement of titanium mesh and particulate graft, (d) placement of titanium implants in reconstructed bone

Horizontal bone augmentation using GBR

Guided bone augmentation is often used to repair dehiscent defects around dental implants. In the anterior maxilla, resorption of the facial plate following extraction often results in a ridge width deficiency. The greatest area of bone volume loss is at the facial ridge crest. Therefore it is not uncommon to need bone augmentation around the neck of the implant. Guided bone regeneration has proven to be a very reliable method to repair localized bone defects with simultaneous implant placement.(25)

In most cases a bone substitute and a resorbable collagen membrane will suffice. If local bone can be harvested, this may be used to cover exposed threads. When facial ridge contour is also deficient, it can be restored with a slower resorbing graft material under the membrane, such as bovine hydroxylapatite.(26)

The grafted implant can be covered by the flap and submerged for protected healing. In the case of more extensive bony width defects, precluding implant placement, a delayed implant protocol following lateral ridge augmentation is indicated. The amount of horizontal bone augmentation with using GBR has been reported to range from 2.0 to 4.5 mm.(27)

The osseous bed may be prepared by perforation of the cortex with a small burr. The intramarrow penetration can facilitate angiogenesis and allow osteogenic cells to migrate into the grafted area.(28)

Modest gains in ridge width may be obtained using bone substitutes, such as mineralized bone allograft, and a resorbable collagen membrane. Slightly greater horizontal gains have been found using a mixture of particulate autograft and bovine hydroxylapatite with a collagen membrane.(29)

Vertical Bone Augmentation Using GBR

Although simultaneous vertical bone augmentation and implant placement has been reported, a two-stage procedure is usually indicated.(30,31)

As vertical bone augmentation is more biologically challenging, the GBR technique may require modification. The majority of studies evaluating GBR for vertical bone augmentation used particulate autograft with a titanium-reinforced PTFE membrane(32,33).

Often a secondary donor site is needed for harvesting larger amounts of particulate bone. The use of a bone scraping device within the mandibular ramus and body has been shown to be a useful technique with low morbidity.(37)

The titanium-reinforced PTFE membrane should be stabilized with tacks or screws. It is helpful to fixate the membrane on the palatal or lingual bone before adding the bone graft and then rotating it over the augmented site. Flap advancement procedures are then performed to obtain tension-free primary closure. The most frequent postoperative complication of GBR is membrane exposure.(31)

Surgical methods to passively advance the flaps during closure over the membrane must be employed. Exposure of expanded PTFE membranes has been shown to significantly reduce bone regeneration.(30)

Exposure rates as high as 35% resulting in infection and GBR failure have been reported.(33)

A membrane made of high-density polytetrafluoroethylene (d-PTFE) was developed for use in socket grafting.(34)

Dense PTFE membranes have also been found to be as effective as the expanded version when used for ridge augmentation.(35)

However, primary closure and avoidance of membrane exposure are advised with this application. Exposure of collagen membranes to the oral cavity increases the rate of degradation and loss of barrier function.(36)

Onlay block bone grafts, Interpositional bone grafts, Distraction osteogenesis are described in Maxillary and Mandibular hard tissue augmentation.

6) Distraction osteogenesis

Distraction osteogenesis (DO) can be used to regenerate missing hard and soft tissue (Figures 9). Distraction osteogenesis relies on the body's ability to generate bone as two segments of bone are "distracted" apart. The osteotomies are created and the distraction device is placed. Typically, there is a latency phase of one week where a fibrovascular bridge is formed in the osteotomy site. This provides a template to generate new bone as the segments are distracted apart during the activation phase. Once the desired distraction has occurred, the device is left in place for a period of time. Once consolidation (typically 2 to 6 months) has occurred, the distraction device can be removed and implants can be placed. Chiapasco compared GBR to DO and found that both are equally effective in alveolar bone augmentation for implant placement and further stated that the long-term prognosis of vertical bone gain in DO is more predictable. (12)

Advantages

The major advantage of DO is that the gradual traction of the bone transport segment is followed by simultaneous bone osteogenesis and soft tissue regeneration. Distraction osteogenesis is comparable to other techniques for vertical augmentation of bone. There may be less morbidity with this technique and it does not require a donor site. (12)

Disadvantages

A second surgery to remove the distractor is required. In a study by Swennen et al. complications occurred in 22% of patients, mostly due to mechanical distractor-related problems and local infections. Infection was seen in 5.8% and device-related problems were present in 7.3% of all patients. Complications that may resolve spontaneously within six months of the procedure are: temporary inferior alveolar nerve disturbances, pain, trismus, temporary facial nerve palsy, and minor occlusal disturbances. There is also the possibility of localized infection, incorrect vector of distraction, device-related problems, and dehiscence. At times, there may be some technical complications with the device, which may cause device failure that will necessitate another surgery to either remove or replace the device. In cases of device failure, it may cause premature or deficient ossification and/or fracture of the supporting bone. (12)

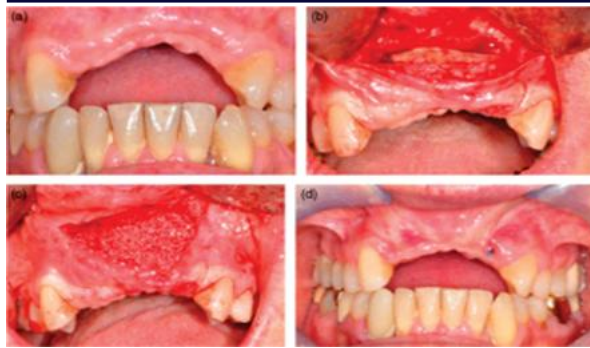

Figure 9: Anterior maxilla: immediate (static) distraction or "sandwich technique": (a) maxillary anterior defect, (b) Ramus interpositional graft, (c) Bovine bone graft over osteotomy, (d) post-operative healing. (12)

REFERENCES

- Peterson's principles of oral and maxillofacial surgery 2nd edition, Chapter 9, page number 175-177.
- Daniel B. Spagnoli et al. Preprosthetic and Reconstructive Surgery, page number 176-180.
- Nystrom E, Ahlqvist J, Kahnberg KE, Ronsenquist JB. Autogenous onlay bone grafts fixed with screw implants for the treatment of severely resorbed maxillae. Radiographic evaluation of preoperative bone dimensions, postoperative bone loss, and changes in soft tissue profile. *Int J Oral Maxillofac Surg* 1996;25:351-9.
- Vermeeren JJ, Wismeijer D, van Wassen MA. One-step reconstruction of the severely resorbed mandible with onlay bone grafts and endosteal implants. A 5-year follow-up. *Int J Oral Maxillofac Surg* 1996;25:112-5.
- Nystrom E, Lundgren S, Gonne J, Nilson H. Interpositional bone grafting in LeFort I osteotomy for reconstruction of the atrophic edentulous maxilla. A two stage technique. *Int J Oral Maxillofac Surg* 1997;26:423-7.
- Keller EE, Eckerd SE, Tolman DE. Maxillary antral and nasal one stage inlay composite bone graft. A preliminary report on 30 recipient sites. *J Oral Maxillofac Surg* 1994;52:438-48.
- Astrand P, Nord PG, Brånemark PI. Titanium implants and onlay bone grafts to the atrophic edentulous maxilla. A three year longitudinal study. *Int J Oral Maxillofac Surg* 1996;25:25-9.
- Bell WH, Profit WR, White RP Jr. Surgical correction of dentofacial deformities. Philadelphia: W.B. Saunders; 1980.
- Piecuch J, Segal D, Grasso J. Augmentation of the atrophic maxilla with Interpositional autogenous bone grafts. *J Maxillofac Surg* 1984;12:133-6.
- Cawood JJ, Stoelting PJW, Brouns, JJ. A reconstruction of the severely resorbed, Class VI in maxilla. A two step procedure. *Int J Oral Maxillofac Surg* 1994;23:219-25.
- Block MS, Kent JN. Sinus augmentation for dental implants: the use of autogenous bone. *J Oral Maxillofac Surg* 1997;55:1281-6.
- Alan S. Herford, Katina Nguyen, Chapter 8, Alveolar ridge augmentation: An algorithmic approach, Horizontal Alveolar ridge augmentation in implant dentistry, A surgical manual, 1st edition, 2016
- Weiss PA, Taylor AC: The technology of nerve regeneration. A review. Sutureless tubulation and related methods of nerve repair, *J Neurosurg* 1:400-450, 1944
- Murray G, Holden R, Roachlaw W: Experimental and clinical study of new growth of bone in a cavity, *Am J Surg* 93:385-387, 1957.
- Hurley L et al: The role of soft tissues in osteogenesis. An experimental study of canine spinal fusions, *J Bone Joint Surg* 41A:12431254, 1959.
- Linghorne WJ: The sequence of events in osteogenesis as studied in polyethylene tubes, *Ann NY Acad of Sci* 85:445-455, 1960.
- Boyne PJ: Regeneration of alveolar bone beneath cellulose acetate filter implants, *J Dent Res* 43:827, 1964.
- Kahnberg KE: Restoration of mandibular jaw defects in the rabbit by subperiosteally implanted Teflon mantle leaf. *Int J Oral Surg* 8:449-456.
- Linghorne WJ, O'Connell DC: Studies in the regeneration and reattachment of supporting structures of the teeth. I. Soft tissue attachment, *J Dent Res* 29(16):419-428, 1950.
- Linghorne WJ, O'Connell DC: Studies in the regeneration and reattachment of supporting structures of the teeth. II. Regeneration of alveolar process, *J Dent Res* 30(5):604-614, 1951.
- Melcher AH: On the repair potential of periodontal tissues, *J Periodontol* 47:256-260, 1976.
- Seibert J, Nyman S: Localized ridge augmentation in dogs: a pilot study using membranes and hydroxyapatite, *J Periodontol* 61:157165, 1990.
- Rominger JW, Triplett RG: The use of guided tissue regeneration to improve implant osseointegration, *J Oral Maxillofac Surg* 52(2):106-112, 1994.
- Hammerle CH, Jung RE, Feloutzis A: A systematic review of the survival of implants in bone sites augmented with barrier membranes (guided bone regeneration) in partially edentulous patients, *J Clin Periodontol* 29 (suppl 3):226-231, 2002.
- Aghaloo TL, Moy PK: Which hard tissue augmentation techniques are the most successful in furnishing bony support for implant placement? *Int J Oral Maxillofac Implants* 22(suppl): 49-70, 2007.
- Buser D, Chappuis V, Kuchler U, et al.: Long-term stability of early implant placement with contour augmentation, *J Dent Res* 92(12 Suppl): 176S-182S, 2013.
- Chiapasco M, Zaniboni M, Boisco M: Augmentation procedures for the rehabilitation of deficient edentulous ridges with oral implants, *Clin Oral Implants Res* 17:136-159, 2006.
- Gordh M, Alberius P, Lindberg L, Johnell O: Bone graft incorporation after cortical perforations of the host bed, *Otolaryngol Head Neck Surg* 7:664-670, 1997.
- Urban IA, Nagursky H, Lozada JL, Nagy K: Horizontal ridge augmentation with a collagen membrane and a combination of particulated autogenous bone and anorganic bovine bonederived mineral: a prospective case series in 25 patients, *Int J Periodontics Restorative Dent* 33:299-307, 2013.
- Simion M, Trisi P, Piattelli A: Vertical ridge augmentation using a membrane technique associated with osseointegrated implants, *Int J Periodontics Restorative Dent* 14:496-511, 1994.

- Rocchietta I, Fontana F, Simion M: Clinical outcomes of vertical bone augmentation to enable dental implant placement: a systematic review, *J Clin Periodontol* 35(Suppl. 8):203-215, 2008.
- Urban IA, Lozada JL, Jovanovic SA, et al.: Vertical ridge augmentation with titanium-reinforced, dense-PTFE membranes and a combination of particulated autogenous bone and anorganic bovine bone-derived mineral: a prospective case series in 19 patients, *Int J Oral Maxillofac Implants* 29:185-193, 2014.
- Lang NP, Hammerle CH, Bragger U, et al.: Guided tissue regeneration in jawbone defects prior to implant placement, *Clin Oral Implants Res* 5:92-97, 1994.
- Hoffmann O, Bartee BK, Beaumont C, et al.: Alveolar bone preservation in extraction sockets using non-resorbable dPTFE membranes: a retrospective non-randomized study, *J Periodontol* 79(11):1355-1369, 2008.
- Carbonell JM, Martin IS, Santos A, et al.: High-density polytetrafluoroethylene membranes in guided bone and tissue regeneration procedures: a literature review, *Int J Oral Maxillofac Surg* 43:75-84, 2014.
- Tal H, Kozlovsky A, Artzi Z, et al.: Cross-linked and non-crosslinked collagen barrier membranes disintegrate following surgical exposure to the oral environment: a histological study in the cat, *Clin Oral Implants Res* 19:760-766, 2008.