Research Paper Medical Science

Amelogenesis Imperfecta with Class III Malocclusion: an Overview Of Interdisciplinary Approach to Esthetic Management – A Rare Case Report

* Dr.Bhavna Singh ** Singh Vijav B.

* Lecturer, Department of Dental Surgery, Moti Lal Nehru Medical College, Allahabad

** Professor and Head of Department, Department of Dental Surgery, Moti Lal Nehru Medical College, Allahabad

ABSTRACT

The article reports and describes a comprehensive interdisciplinary approach to aesthetic management of a rare case of amelogenesis imperfecta with Class III malocclusion.

Keywords : Amelogenesis Imperfecta; Class III malocclusion; Interdisciplinary management.s.

INTRODUCTION

The term Amelogenesis Imperfecta (AI) has been defined to include a variety of genetically determined disorders that primarily affect the enamel of all or nearly all teeth, without causing detectable alteration elsewhere in the body. (1) It represents an inherited group of anomalies of enamel formation with an incidence ranging from 1:718 to 1:14,000. (2) It is passed down through families as a dominant trait. That means the affected individual only needs to get the abnormal from one parent in order to get the disease.

It is a developmental disorder of tooth structure in which the teeth are covered with thin, soft and abnormally formed enamel. The teeth appear yellow and are easily damaged. The enamel is easily fractured and worn away, which affects the appearance of the teeth, especially if left untreated. Both deciduous and permanent dentition is affected. (3)

At least 14 different subtypes of AI exist, with numerous patterns of inheritance and a variety of clinical manifestations. (1-4) On the basis of phenotype (clinical appearance), three broad types can be identified by Witkop as: hypoplastic, hypocalcified and hypomaturation. (5)

- **Hypoplastic**: enamel formed, is reduced in quantity but is relatively well mineralized.
  - Clinically it presents as reduced thickness of enamel.
- **Hypocalcified**: enamel is formed in normal amount, but is poorly mineralized.
  - Enamel thickness on newly erupted teeth closely approaches that of normal, but it is very soft, fria ble and can be easily removed from the underly ing dentin.
- **Hypomaturation**: final stage of mineralization is abnormal.
  - Enamel thickness is normal. Enamel is harder than the hypocalcified type, with a mottled opaque white to yellow brown to a red brown color and a tendency to chip off from the underlying dentin rather than wear away.

Restoration of these defects is important for aesthetic and functional concerns as well as for a positive psychological impact on the patient. (6) Treatment planning for such patients is related to factors like: other co-existing dental problems, age, socioeconomic status, type and severity of the disorder, extent of damage and intraoral situation at the time of treatment planning. (7)

CASE DESCRIPTION

A 22 year male presented with the complaint of severe, generalized loss of tooth structure and extreme concern regarding the unaesthetic appearance of his teeth. On extraoral examination a Class III tendency with mild maxillary deficiency was detected (Figure 1a, 1b). The patient presented with a low self esteem and was extremely conscious while smiling consequently resulting in lack of teeth visibility on smiling (Figure 1c).



Figure 1a Figure 1b Figure 1c

Figure 1a, 1b, 1c: Extraoral photographs (Frontal, Profile and Smiling)

Clinical examination revealed a narrow maxillary arch, complete bilateral buccal cross-bite and edge to edge anterior occlusion (Figure 2a, 2b, 2c). Almost all teeth showed significant amount of occlusal wear (Figure 3a, 3b). The pattern of wear was strongly affected and worsened by the co-existing Class III malocclusion and edge to edge occlusion. Remaining teeth had a brownish yellow color. The generalized pattern of enamel affected and positive family history led to the diagnosis of AI. Orthopentomogram showed normal development of roots with no existing pathology (Figure 4).





Figure 2a Figure 2b Figure 2c

Figure 2a, 2b, 2c: Intraoral photographs (Right buccal, frontal, Left buccal)




Figure 3a Figure 3b

Figure 3a, 3b: Maxillary and Mandibular Occlusal photographs

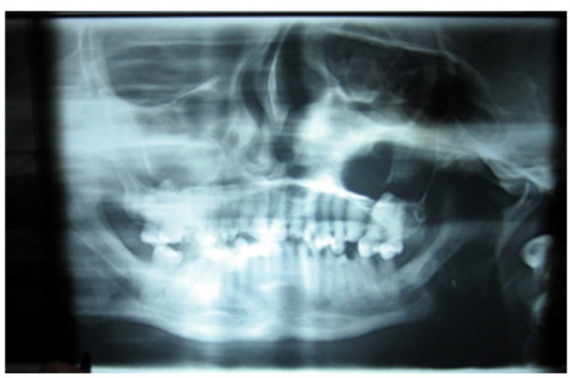

Figure 4

Figure 4: OPG x-ray

DISCUSSION

Amelogenesis imperfecta is a developmental disorder than can be readily recognized by the dentist, on careful clinical examination. Its timely diagnosis and careful treatment planning are essential for best and most conservative management. Class III malocclusion is another challenging clinical condition to treat, especially in an adult patient. Co-existence of both these conditions in the case under discussion presents a highly challenging clinical situation, wherein careful sequencing of comprehensive treatment would ensure a stable, functional and aesthetically pleasing result for the patient.

Diagnosis

Diagnosis of AI is largely clinical as genetic diagnosis is presently only a research tool. (3) *Clinical diagnosis* is based on:

- Positive family history
- Clinical observation: whether all teeth are affected, is there a chronological distribution and meticulous recording of the findings
- Absence of any past medical history that could have caused sufficient metabolic disturbance.
- Radiographs: showing contrast between enamel and dentin.

Differential diagnosis must consider and rule out possibilities like: (3)

- Dental fluorosis: usually premolars and 2nd molars may be unaffected.
- Chronological enamel hypoplasia: a positive history of disease and corresponding chronological distribution of markings will be seen.
- Molar-Incisor hypo-mineralization.

Problem list

The multiple problems associated with the presenting clinical situation are governed both by AI as well as the co-existing Class III malocclusion and can be listed as follows:

- Low self esteem of the patient due to long-standing, progressively deteriorating aesthetic appearance of his teeth.
- Class III malocclusion with bilateral buccal cross-bite and edge to edge anterior occlusion.
- Poorly calcified enamel structure, easily prone to wear and damage.
- Difficulty in undertaking routine orthodontic treatment due to poor enamel strength and significant wear.
- Severe generalized occlusal wear (necessitating a more comprehensive endodontic and prosthetic management approach, than would be needed if the patient presented at an earlier age).
- Multiple exposed teeth due to severe loss of tooth structure.
- Reduced vertical dimension due to severe occlusal wear resulting in over closure.

Interdisciplinary Approach to Comprehensive Management

The successful management of the presenting clinical situation requires a comprehensive interdisciplinary approach for best psychological, aesthetic and functional outcome.

***Psychological management* includes**

Thorough counseling of patient regarding the nature of his problem, with the aim to reinforce a realistic and positive attitude towards the expected outcome.

Before and throughout treatment a compassionate attitude of the interdisciplinary team towards the patient and his dental situation must be maintained to enforce and improve his self esteem and confidence.

Orthodontic management includes

- Three way expansion of maxillary arch: age of patient, limited availability of remaining tooth structure and proneness of enamel to damage indicates the need for bone supported expansion appliance. Palatal implants can be used for the same.
- Removable mandibular appliance (posterior bite plane) can be used for transient bite opening to facilitate unhindered expansion.
- If the patient presented at an earlier age, face mask could be used to facilitate maxillary protraction.

Surgical alternatives include

- Extraction of teeth that are severely damaged and are not expected to have a good prognosis.
- Surgically assisted rapid palatal expansion (SARPE) in combination with face mask therapy for maxillary advancement.
- Le-forte I osteotomy for maxillary advancement with SARPE for faster correction of malocclusion.

Endodontic management includes

- Root canal treatment of exposed teeth.
- Endodontic Post and core build-up on teeth that lack sufficient clinical crown height to support artificial crown.

Prosthetic management includes

- Restoration of vertical dimension lost due to extreme occlusal tooth wear.
- Full mouth rehabilitation with fixed prosthesis to restore lost tooth structure.
- Full coverage crowns to protect the teeth from further

damage, improve their appearance, and optimize function and esthetics.

The objective of treatment of adult patients presenting with this unique clinical condition (amelogenesis imperfecta with Class III malocclusion) is to reinforce a better self-esteem and confidence concomitant with restoration of optimal function and aesthetics. On initial examination, such conditions may appear challenging and difficult to treat. However, careful and well planned treatment sequencing enables successful and satisfactory outcome for both the patient as well as the clinician.

REFERENCES

1. Sengun A, Ozer F. Restoring function and aesthetics in a patient with amelogenesis imperfecta – A case report. Quintessence Int 2002;33:199-204. | 2. Neville BW, Damm DG, Buoquot JE. Oral and maxillofacial pathology (2nd edn). Saunders, Philadelphia 2007:89-106. | 3. Crawford PJM, Aldred M, Zupan AB. Amelogenesis Imperfecta – Review. Orphanet J of Rare Diseases 2007;2:17. | 4. Witkop CS, Kuhlmann W, Sauk J. Autosomal recessive pigmented hypomaturation amelogenesis imperfecta. Oral Surg Oral Med Oral Pathol 1973;36:367-82. | 5. Witkop CJ Jr. Hereditary defects in enamel and dentin. Prosc First Cong Human Genetica Statist Med 1957;7:236-39. | 6. Ozturk N, Zari Z, Ozturk B. An interdisciplinary approach for restoring function and esthetics in a patient with amelogenesis imperfecta and malocclusion: A clinical report. J of Prosthet Dent 2004;92:112-15. | 7. Rosenblum SH. Restorative and orthodontic treatment of an adolescent with amelogenesis imperfecta. Pediatr Dent 1999;21(4):289-92.