Research Paper Medical Science

Aplasia of Left Submandibular Gland- A Case Report

Dr. V.R. Nikam Professor and Head, Department of Anatomy, D.Y.Patil Medical College Kasaba Bawada, Kolhapur.

Dr. B. S. Kitture Consulting Radiologist, Director I lab diagnostic Ichalkaranji and Eureka diagnostics and research centre, Kolhapur.

ABSTRACT

The congenital absence of major salivary glands is a very rare disorder. The cause of the absence has not been determined. Isolated absence of unilateral submandibular gland is an unusual entity with less than 14 cases reported in the literature. The etiopathogenesis of isolated absence of major salivary gland without other developmental anomalies is still unclear. In this case we report a 42 year old male who came with a complaint of suprasternal neck swelling and on ultrasonography and magnetic resonance imaging incidentally left submandibular aplasia was detected. The literature on this rare occurrence is reviewed and signifance of the patient is discussed.

KEYWORDS Submandibular gland, Aplasia, Agenesis, Congenital, Salivary gland.

INTRODUCTION-

Congenital major salivary gland is a very uncommon disorder [1, 2, 3, 4]. The precise incidence of major salivary gland agenesis is difficult to establish due to asymptomatic nature of many cases [3].

The first case of salivary gland agenesis was described in 1885; and about 30-40 cases have been reported in the literature [1, 5, 6].

Most of the cases of congenital absence of major salivary glands; may be associated with multiple other developmental anomalies of the face [1, 4]. These anomalies may be like atresia of lacrimal puncta, mandibulo-facial dysostosis or congenital malformations of the temporo-mandibular component [1, 2, 4, 7, 8, 9].

Developmental anomalies of major salivary gland include total absence of major salivary gland (aplasia) or reduced glandular tissue associated with salivary hypofunction (hypoplasia). Any of the major glands may be absent unilaterally or bilaterally [9].

Analysis of these abnormalities suggest that the aplasia of salivary glands likely results from the disturbance during fetal development of first and second branchial arches but the exact etiology is not known [10].

Unilateral submandibular gland aplasia is even rarer with less than 10-14 cases have been described [1, 10, 11-20]. Most of them were incidental findings because of lack of symptoms.

In this study we report a case of an incidentally detected unilateral aplasia of left submandibular salivary gland demonstrated by ultrasonography and magnetic resonance imaging.

CASE REPORT-

A 42 year male patient was referred for ultrasonography for the complaint of suprasternal swelling in the neck. On examination no such swelling was palpated and the patient didn't complain about any symptoms apart from anxiety. The patient was otherwise healthy.

Inspection showed an asymmetry in the submandibular region. Extra oral palpation was unremarkable. Oral mucosa had no alterations. The rest of oropharyngeal and cervical examination was normal. There was no enlargement of submandibular gland region.

Neck ultrasonography was performed for initial radiological evaluation

Fig no-1: Ultrasonography of right and left submandibular region showing the absence of left submandibular gland.



Left sublingual gland was normal; no areas of necrosis and calcification were noted. But left submandibular gland could not be identified. No anomalies were observed in remaining major salivary glands. Cervical adenopathy was absent. These findings were suggestive of absence of unilateral i.e. left submandibular gland with normal left sublingual gland.

Our study was completed with magnetic resonance imaging which revealed the absence of left submandibular gland and normal left sublingual gland. Right sublingual, right submandibular and both parotids were normal. Patient was asymptomatic hence required no treatment.

Fig no-2: Magnetic resonance image showing the empty submandibular region.

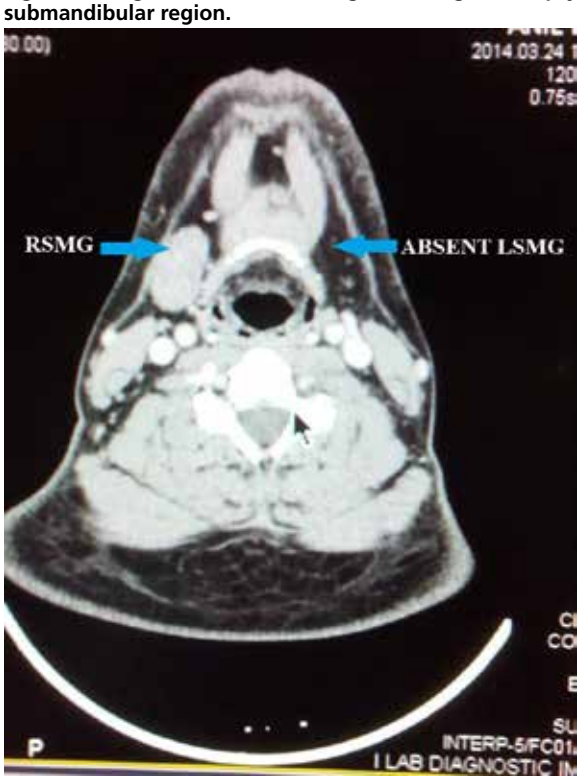

DISCUSSSION-

Salivary glands arise sequentially between 4th and 8th week of fetal development as solid epithelial buds from primary oral cavity [2, 4]. These primordial buds grow and extend into underlying mesenchymal tissue as a solid core of cells; which undergoes extensive branching and eventually develops into lumina. Parotid gland appears during 4th week of gestation, submandibular glands during 6th and sublingual glands during 9th week of gestation [1, 4, 21, 22].

The cause of aplasia of the salivary glands is still unknown [1, 2] and involves multiple major salivary glands [4]. The parotid gland is most commonly affected than the submandibular glands [21]. A review of any familial disease in these patients may reveal an underlying genetic cause of the absent major salivary glands [3, 22, 23].

Isolated unilateral major salivary gland aplasia is a rare entity with only few cases reported in the literature to date [4]. The aplasia is likely due to arrest in organogenesis but the exact etiology is unknown [4, 22]. Agenesis of major salivary glands may be associated with ectodermal defects of first and second branchial arches, lacrimal punctum aplasia or hypoplasia and agenesis of lacrimal glands [1, 2, 4] and may be the result of some disturbing influence in early fetal development [22].

Submandibular gland aplasia may be associated with severe caries in mandibular permanent incisor teeth as well as other signs of salivary hypofunction, such as dry mouth, disturbed oral sensation and oral infections. In our case the patient did not suffer from any problems related to salivary hypofunction and was asymptomatic as the aplasia was confined to one gland only and the secretions of other glands compensated for it. Additionally all other cases of unilateral submandibular salivary gland aplasia reported in the literature had no accompanying developmental disorders. Also in our case we did not encounter any associated anomaly.

In previous case reports hypertrophy of sublingual salivary gland in association with absence of ipsilateral submandibular salivary gland was observed. However in our case no significant hypertrophy of left sublingual gland was seen.

Salivary gland aplasia can be diagnosed with variety of imaging techniques which include computed tomography, magnetic resonance imaging, ultrasonography, sialography or nuclear medicine [1, 4, 24]. Among these methods ultrasonography is cheap, non-invasive and widely available; and thus very important [3, 24].

In our patient we were able to confirm the diagnosis of left submandibular gland aplasia by using ultrasonography and magnetic resonance imaging.

CONCLUSION-

In conclusion unilateral submandibular gland aplasia is an extremely rare disorder and its incidence is unknown. Careful evaluation of patients who complain of neck mass may lead to detection of new cases of this entity. Ultrasonography and magnetic resonance imaging techniques should be performed before any intervention.

In our opinion unilateral agenesis of submandibular gland always will not be associated with hypertrophy of ipsilateral sublingual gland as well as any facial anomaly which was revealed in our case.

REFERENCES

1] Gonzalo Herrera-Calvo, Belen Garcia-Montesinos-Perea, Ramon Saiz-Bustillo, Jaime Gallo-Teran, Pedro Lastra-Garcia-Baron: Unilateral submandibular gland aplasia with ipsilateral sublingual gland hypertrophy presenting as a neck mass. Med Oral Patol Oral Cir Buccal 2011,Jul 1;16 (4):e537-40. | | 2] Mustafa Deniz Yilmaz, Aylin Yucel, Sefa Derekoy: Unilateral aplasia of the submandibular gland. Eur Arch Otorhinolaryngol (2002) 259: 554-556. | 3] T. A. Hodgson FDS, RCS, MRCP (UK), R. Shah FDS, RCS, S. R. Porter MD,Phd,FDS,RCS,RCSE: The investigation of major salivary gland agenesis: A case report. J Oral pathology; Pedeatric Dentistry 23:131-134, 2001. | | 4] A. Srinivasan, J. S. Moyer, S. K. Mukherji: Unilateral Submandibular Gland Aplasia Associated with Ipsilateral Sublingual Gland Hypertrophy; AJNR; Nov-Dec 2006;www.anjr.org. | | 5] McDonald FG, Mantas J, McEwen CG, et al. Salivary gland aplasia: an ectodermal | disorder? J Oral Pathol 1986;15:115–17. | | 6] Higashino H, Horii T, Ohkusa Y, et al. Congenital absence of lacrimal puncta | and of all major salivary glands: case report and literature review. Clin Pediatr | (Phila) 1987;26:366–68. | | 7] Yilmaz MD, Yucel A, Derekoy S, et al. Unilateral aplasia of the submandibular | gland. Eur Arch Otorhinolaryngol 2002;259:554–56. | | 8] Collins P. Embryology and development. In: Williams PL, ed. Gray's Anatomy: | The Anatomical Basis of Medicine and Surgery. 38th ed. New York: Churchill | Livingstone; 1995:175. | | 9] MS Fracaro, VM Linnett, KB Hallett, NW Savage: Submandibular gland aplasia and progressive dental caries: A case report; Australian Dental Journal 2002;47:4;347-350. | 10] Luis Garcia-Consuegra, Pablo Rosado, Lorena Gallego, Luis Junquera: Unilateral absence of submandibular secondary to stones. Aplasia versus early atrophy. Med Oral Patol Oral Cir Buccal 2010; Sep1; 15(5);e752-4. | | 11] Kubo S, Abe K, Ureshino T, Oka M. Aplasia of the submandibular gland. A case report. J Craniomaxillofac Surg. 1990;18:119-21. | | 12] García-Consuegra L, Gutiérrez L J, Castro J M, Granado J F. Congenital unilateral absence of the submandibular gland. J Oral Maxillofac Surg. 1999;57:344-6. | | 13] Yilmaz MD, Yücel A, Dereköy S, Altuntaş A. Unilateral aplasia of the submandibular gland. Eur Arch Otorhinolaryngol. 2002;259:554-6. | | 14] Roh JL. Unilateral submandibular gland aplasia: an isolated phenomenon of early fetal development. Otolaryngol Head Neck Surg. 2006;135:332-4. | | 15] Mathison CC, Hudgins PA. Bilateral submandibular gland aplasia with hypertrophy of sublingual glands. Otolaryngol Head Neck Surg. 2008;138:119-20. | | 16]Shipchandler TZ, Lorenz RR. Unilateral submandibular gland aplasia masquerading as cancer nodal metastasis. Am J Otolaryngol. 2008;29:432-4. | | 17] Koo BS, Lee SW, Lee YM, Lee JD, Koh YW. Sialolithiasis in a stump of Wharton's duct of an aplastic unilateral submandibular gland. Int J Oral Maxillofac Surg. 2009;38:93-5. | 18] Gallego L, Junquera L, Cuesta P, Rosado P. Symptomatic unilateral submandibular gland aplasia. Br J Oral Maxillofac Surg. 2009;47:243. | | 19] Gupta N, Palacios E, Barry S. Unilateral submandibular gland aplasia: a rare phenomenon. Ear Nose Throat J. 2009;88:818-20. | | 20] M Ahmed, M Strauss, A Kassai, V Shotelersuk, R DeGuzman: Bilateral submandibular gland aplasia with clinic-radiological mass due to prolapsing sublingual salivary tissue through mylohyoid boutonniere: a case report and review. | | 21] SR Gangidi, D Cunliffe: Hyperpalstic sublingual gland in association with a congenitally missing ipsilateral submandibiular gland; Journal of Surgical Case Reports; 2011;9:5;1-3. | | 22] Wiedemann HR. Salivary gland disorders and heredity. Am J Med Genet 60:222-224, 1997. | | 23] Smith NJD, Smith PB. Congenital absence of major salivary glands. Br Dent J 142:259-260, 1977. | | 24] A Haktanur: CT and MRI findings of bilateral submandibular gland aplasia associated with hypertrophied symmetrical sublingual glands herniated through mylohyoid defects; Dentomaxillofacial Radiology (2012) 41,79-83. |