Research Paper Medical Science

Case Report of a Solitary Osteochondroma of Right Scapula

AYUSH.K.SINGH	Chief Resident, Department of Orthopaedics, Grant Government Medical College,Mumbai, India
NEETIN. P. MAHAJAN	Associate Professor& Head,Department ofOrthopaedics, Grant Government Medical College, Mumbai, India
NADIR.Z.SHAH	Assistant Professor, Department of Orthopaedics, Grant Government Medical College,Mumbai, India
SUNIRMAL.K. MUKHERJEE	Senior Registrar, Department of Orthopaedics, Grant Government Medical College,Mumbai, India
MANISH .D.CHATTE	Chief Resident, Department of Orthopaedics, Grant Government Medical College,Mumbai, India
CHIRAG BORANA5	Senior Registrar, Department of Orthopaedics, Grant Government Medical College,Mumbai, India

KEYWORDS

INTRODUCTION

Osteochondroma is the most common benign bone tumor and is often diagnosed as an incidental finding. Osteochondromas account for approximately 35% of benign bone tumors and 9% of all bone tumors. Most are asymptomatic, but they can cause mechanical symptoms depending on their location and size.

The osteochondroma may have a stalk and be defined as pedunculated, or it may have a broad base of attachment and be considered sessile . Whether the neoplasm is sessile or pedunculated, the medullary canal of the stalk and the bone are in continuity by definition.

There is a higher incidence in male patient (3:1) and generally affects patient younger than 20 years old. The most common locations for solitary osteochondromas are distal femur, proximal tibia, proximal humerus and pelvis.

These are mostly found in the metaphyseal region of long bones and scapula is involved rarely in 3-4.6%of cases.

Solitary osteochondroma of the scapula is a rare entity, whose prevalence has been estimated in <5% of all osteochondromas, on the basis of the largest reported case series . The tumour can settle on the dorsal or the ventral surface of the scapula, which will determine its clinical manifestations together with the tumour size. When settled on the dorsal surface, it may lead to palpable exostosis and thorax asymmetry; when settled on the ventral surface, it may result in limited motion range, winging of the scapula or snapping noise.

Plain radiography is the modality of choice for identifying osteochondromas . They have the appearance of a pedunculated or sessile lesion with well defined margins that blends imperceptibly with host bone.



Treatment of an asymptomatic lesion is non-operative Resection of osteochondromas should be performed if painful,displays suspicious features of malignant transformation, causes functional impairment, cosmetic deformity,or damage surrounding structures.

CASE REPORT

We present a case of 15 year old girl with large osteochondroma on the dorsal surface of right scapula(Fig 1).She presented with deformity of right scapula for 2 years which was painful and the swelling was not cosmetically appealing to the patient.Local examination revealed prominence at the junction of medial border and spine of scapula.There was no distal neurodeficit. Patient was counselled about the treatment modality.



An Xray of the AP and dorsal surface of scapula was done which showed a bony outgrowth from medial margin(Fig 2)



A bony hard tumour 2.5 x 2 cm was excised along with cartilage cap (Fig 3)under general anaesthesia in prone position by a longitudinal incision 5 cm long at the junction of medial border and spine of right scapula.



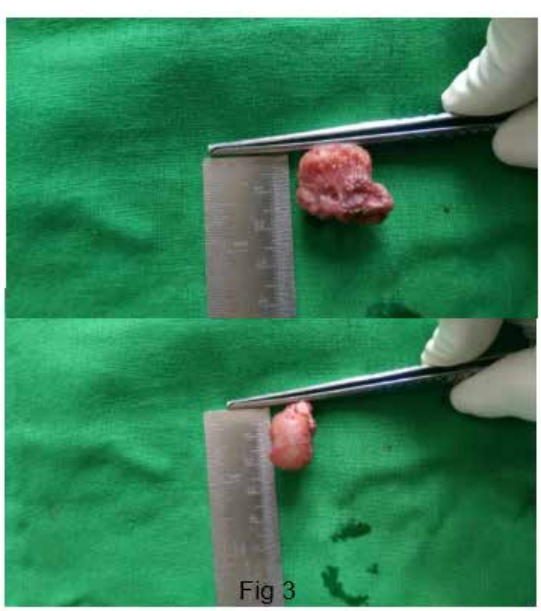

Fig 3

Haemostasis was achieved.Closure was done using subcuticular stitches. Postoperatively patient was given 3 doses intravenous broad spectrum antibiotics(cephalosporin). Suture removal was done on 10th postoperative day.The sample was sent for histopathological examination which confirmed the diagnosis of osteochondroma with no evidence of malignancy.The patient had pain free shoulder movements post operatively

Post op Y view X-ray of scapula along with X-ray of dorsal surface of scapula was done which shows complete removal of osteochondroma(Fig 4)



DISCUSSION

Pedunculated osteochondroma is treated by complete excision of the tumour.In our case patient had no neurodeficit in the form of suprascapular nerve palsy which is commonly seen in scapular osteochondroma.The only concern in our subject was dull aching pain and cosmetic deformity.After excision of the tumour the patient was relieved of pain and had free shoulder movements.Follow up X rays were taken at six months which showed no recurrence.

conclusion

Solitary osteochondroma on dorsal aspect of scapula clinically presents with palpable exostosis which can be diagnosed with ease on an X-ray .Additional diagnostic modalities like CT scan and MRI may not be required in an evident case of dorsal pedunculated osteochondroma with no neurodeficit. There was no recurrence of osteochondroma in our case.We recommend complete excision of the osteochondroma along with cartilage cap to ensure less chances of recurrence.

REFERENCES

1 Tomo H, Ito Y, Aono M, et al. Chest wall deformity associated with osteochondroma | of the scapula: a case report and review of the literature. J Shoulder Elbow Surg | 2005;14:103–6. | 2 Mohsen MS, Moosa NK, Kumar P. Osteochondroma of the scapula associated with | winging and large bursa formation. Med Princ Pract 2006;15:387–90. | 3 Danielsson LG, el-Haddad I. Winged scapula due to osteochondroma. Report of 3 | children. Acta Orthop Scand 1989;60:728–9. | 4 Chillemi C, Franceschini V, Ippolito G, et al. Osteochondroma as a cause of scapular | winging in an adolescent: a case report and review of the literature. J Med Case Rep | 2013;7:220. | 5.O. S. Kwon and J. I. V. Kelly1 .Delayed presentation of osteochondroma on the ventral surface of the scapula.Int J Shoulder Surg. 2012 Apr-Jun; 6(2): 61–63 | 6. Nercessian O, Denton JR. Cartilaginous exostosis arising from the ventral surface of the scapula. A case report. Clin Orthop Relat Res. 1988;236:145–7. [PubMed] | 7. Schmale GA, Conrad EU, III, Raskind WH. The natural history of hereditary multiple exostoses. J Bone Joint Surg Am. 1994;76:986–92. [PubMed] | 8. Shackcloth MJ, Page RD. Scapular osteochondroma with reactive bursitis presenting as a chest wall tumour. Eur J Cardiothorac Surg. 2000;18:495–6. [PubMed] | 9. Tomo H, Ito Y, Aono M, Takaoka K. Chest wall deformity associated with osteochondroma of the scapula: A case report and review of the literature. J Shoulder Elbow Surg. 2005;14:103–6. [PubMed] | 10. Yoo WH, Kim JR, Jang KY, Lee SY, Park JH. Rapidly developed huge bursitis associated with scapular osteochondroma of the multiple exostosis: A case report. Rheumatol Int. 2009;29:317–9. [PubMed] | 11. Cuomo F, Blank K, Zuckerman JD, Present DA. Scapular osteochondroma presenting with exostosis bursata. Bull Hosp Jt Dis. 1993;52:55–8. [PubMed] | 12. D'Ambrosia R, Ferguson AB., Jr The formation of osteochondroma by epiphyseal cartilage transplantation. Clin Orthop Relat Res. 1968;61:103–15. [PubMed] | 13. Esenkaya I. Pseudowinging of the scapula due to subscapular osteochondroma. Orthopedics. 2005;28:171–2. [PubMed] | 14. Anthony McGrath,Kesavan Sri-Ram,Eric Yeung, Ben Spielberg, Nick Kalson,Barry Rose,Rob Pollock,John Skinner. Section 2.5 Benign Bone Tumours. Oxford Textbook of Trauma and Orthopaedics 2nd ed.