Research Paper Medical Science

Diagnostic Challenges of Fine Needle Aspiration Cytology of Focal Hepatic Lesions

DR YOGENDRA MADAN TUTOR, DEPARTMENT OF PATHOLOGY, M.P. SHAH MEDICAL COLLEGE, JAMNAGAR, GUJARAT, INDIA.

DR SHAMIM S. SHEIKH ASSOCIATE PROFESSOR, DEPARTMENT OF PATHOLOGY, M.P. SHAH MEDICAL COLLEGE, JAMNAGAR GUJARAT, INDIA.

ABSTRACT

Background: Space-occupying lesions (SOL), such as metastatic tumors and other focal lesions, produce changes in the liver parenchyma adjacent to lesion. Single or multiple hepatic SOL is a major indication for fine needle aspiration cytology (FNAC) to evaluate possible tumor. Method: Ultrasonographic (USG) guided FNAC was performed in 44 cases who present as hepatic SOL on USG. Cytomorphological features of hepatic SOL are discussed and diagnostic accuracy and limitations of ultrasonography guided FNAC was evaluated. Result: The diagnostic yield was 90.90%. Benign lesions were 31.81% whereas malignant lesions were 54.54%. Most common benign lesion encountered was abscess. The ratio of metastatic carcinoma to primary Hepatocelluler carcinoma in present study was 3.6: 1. Most common metastasis was of adenocarcinoma type (44.44%). Conclusion: FNAC is a safe, useful and economic procedure with minimum complication and can be routinely done for diagnosis of liver diseases.

KEYWORDS fine needle aspiration cytology, space occupying lesion, ultrasonography.

Introduction

The liver is involved in many nonneoplastic and neoplastic diseases. Final definitive diagnosis in a SOL of liver can not be made only by radiological imaging modality. Ultrasound is being used in combination with fine needle aspiration in diagnosis of liver disease since 1970[1]. Although ultrasound guided FNAC is a safe procedure it should only be performed if thorough non invasive clinical, biological and radiological findings are inconclusive. Indication of hepatic FNAC are possible tumor, hepatocellular disease of unknown cause, PUO and long standing cases of hepatitis.

Most of the time FNAC provides sufficient cellularity and at the same time greatest challenge to cytopathologist. The aim of present study is to find out frequency of different benign and malignant lesions. Various cytomorphological features of hepatic SOL are discussed and diagnostic accuracy and limitations of ultrasonography guided FNAC was evaluated. Major diagnostic issues include: 1) Distinction of benign/ reactive hepatocyte from well differentiated hepatocellular carcinoma. 2) Distinction of poorly differentiated HCC from cholangiocarcinoma and metastatic carcinoma. 3) Determination of primary site of malignant tumor.

Occasionally inflammatory lesion or diffuse liver disease mimic mass like lesion on radiograph and FNAC is performed to rule out possibility of malignancy.

Material and method

Forty four patients with hepatic mass lesion with normal prothrombin time were subjected to USG-guided FNAC over a three-year period from Jan. 2011 to Dec.2013. The patients with hemangioma and hydatid cyst of liver diagnosed by USG were excluded to prevent undue complications. The cytological material was obtained using 22-gauge, 90-mm spinal needle introduced into various nodular or cystic lesions. The smears were stained by may-grónwald-giemsa, papanicolaou, hematoxylin and eosin stains. Gram's and Ziehl-neelson (ZN) stains were done whenever needed. The diagnoses were correlated with clinical and radiological findings, histopathological diagnoses where available, and/or follow-up information.

Results

FNAC of liver was performed on 44 cases and studied. It was conclusive in 40 cases. The diagnostic yield was 90.90%.

Table: 1 distribution of liver aspirate in present study and its comparison with different studies (percentage)

LIVER ASPIRATE	Mallikarjuna et al[11]	Rasania et al[12]	Talukder et al[3]	Present study
Benign	30.56	23.33	0.9	32.56
Malignant	68.06	67.77	93.5	53.50
Suspicious	0	2.23	0	4.60
Non representative	1.38	6.67	6.5	9.30

Table 2: Incidence of various types of benign tumor

S. No.	Lesion	No. Of Cases
1	Bile duct hyperplasia/adenoma	1
2	Amoebic abscess	9
3	Pyogenic abscess	2
4	Granuloma	1
5	Benign cystic lesion	1

Table3: Incidence of various types of malignant tumor

S. No.	Type of malignancy	No. of cases
1	Metastatic carcinoma	18
2	Hepatocellular carcinoma	5
3	Cholangiocarcinoma	3

Hepatocellular carcinoma is more common in male with male female ratio 4.4:1 in India[2]. In present study out of 26 malignant cases 18 (69.23%) were due to secondary metastasis to liver (table 3) and all five patients were male. Talukder et al[3] found seven out of eight patients male. Two female patients showed cholangiocarcinoma against one male.

Table 4: incidences of different type of metastatic tumor

S. No.	Metastatic tumor	No.of cases	Percentage
1	Adenocarcinoma	8	44.44
2	Small cell tumor lung	3	16.16
3	Squamous cell carcinoma	1	5.55
4	Round cell neoplasm	1	5.55
5	Secondary from epithelial malignancy: loss of differentiation	5	27.77
	Total	18	100

Most common metastasis (table 4) was of adenocarcinoma type (44.44%). In four cases of adenocarcinoma primary tumor was found in gastrointestinal tract. Lung and breast were other primary tumor found (two cases each) on follow up examination. Three cases (16.16%) of small cell carcinoma and one case of Squamous cell carcinoma were from lung. One round cell tumor from unknown primary was other metastatic tumor. In 5 cases (28%) metastatic cells were of high grade and loss of differentiation was reported.

Discussion

Space occupying lesion of liver are not very common in our environment but it affects relatively all age groups with peak age in 6th to 7th decade and male female ratio is 3:1. The malignant lesions were common between 45-70 years while the benign were in age group of 16 to 70 years. Ultrasound guided liver aspiration is a routine practice in our hospital for any patient suspected with focal hepatic lesion rather than conventional Vim Silvermen needle biopsy.

Normal hepatocytes are polygonal cells with abundant cytoplasm that often contains golden brown bile pigment. Nucleus is round monomorphic with fine granular chromatin, prominent nucleoli and pseudoinclusions. Mild degree of nuclear pleomorphism can be seen in benign hepatocyte. Spindle shaped endothelial cells surround the cluster of hepatocytes.

Bile ductule cells are small round monomorphic cells with scanty cytoplasm. These are usually present as smaller clusters. Kupffer cells have scanty cytoplasm, bean shaped nuclei with inconspicuous nucleoli. Phagocytic material are often noted within the cytoplasm.

Although imaging techniques have helped greatly with the early and accurate diagnosis of liver abscess, the appearances are often non-specific. There is some overlap between the radiologic features of liver abscesses, Hepatocelluler carcinoma (HCC) and metastasis. Tumors, primary or secondary, may undergo extensive necrosis, with the resultant radiologic image of the cavitary neoplasms mimicking abscesses; abscesses are accompanied by proliferative reactive changes, making radiologic differentiation from a neoplastic process almost impossible. In these situations FNAC plays an essential complementary role[4].

In cases of amoebic abscess there was spares inflammatory cells. Monocytes and lymphocytes were observed more commonly than polymorphs. Microscopic examination of the pus showed deformed hepatocytes, debris, RBCs and a few polymorphs. In cases of pyogenic abscess cytologic smear showed numerous polymorphs, necrotic debris and degenerated hepatocytes.

Amoebae are unlikely to be detected in the smears unless tissue from the walls of the abscess cavity is examined. Amoebic liver abscess can also be diagnosed by the presence of serum anti-amoebic antibodies[5].

The smears from granulomatous hepatitis showed epithelioid histiocytes in single and small clusters along with foreign body, Langhan's type of multinucleated giant cells and lymphocytes. Indian studies have shown that 68% of granulomas in liver biopsies are of tuberculous etiology[6].

One patient diagnosed as solitary cyst in liver on USG. Liver function test was within normal limit. Aspiration shows cystic macrophages with no evidence of malignancy.

All the five cases diagnosed as hepatocellular carcinoma were male in this study. Three patients had history of chronic alcohol abuse and one was positive for hepatitis B where as in one patient no etiological agent could be recognized. In all the cases level of alpha feto protein was high.

In hepatocellular carcinoma cytology smear showed oval to polygonal pleomorhic hepatocytes arranged in trabecullar, acinar or thin cord like structure. Cytoplasm was dense with well defined border. At many places cytoplasm showed bile pigment and eosinophilic globule.

Numerous naked nuclei with conspicuously large nucleoli of irregular shapes were present. This feature was first describes by Pedio et al[7] (1988), reflects the fragility of cytoplasm of tumor cells. This feature is common to all hepatomas.

Well differentiated tumor cells were polygonal, have central round vesicular nuclei, a central nucleolus and granular cytoplasm. Cells of poorly differentiated liver cell carcinoma were round and smaller; nuclei were large, irregular; central or eccentric; nucleoli were prominent and cytoplasm was relatively scanty and pale staining (figure 1).

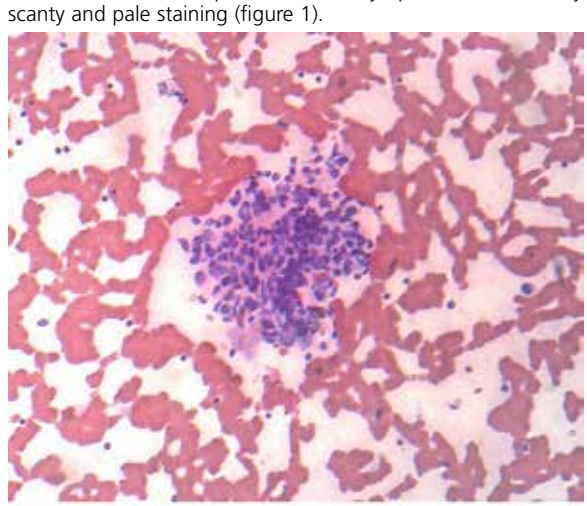

Figure 1 Hepatocellular carcinoma (luster of dissociated malignant cells. Individual cells are oval to polygonal. Nuclei are enlarged and moderately pleomorphic (H and E stain, 200X)

Many times reactive hepatocytes are difficult to differentiate from well differentiated HCC. Reactive or regenerated hepatocytes often show nuclear enlargement and pleomorphism. Bi and multinucleated hepatocytes are also seen. The differentiating cytological feature from HCC are abundant cellularity, trabecular pattern of cells, moderate to mark nuclear atypia, stripped atypical nuclei and macronuleoli.[8]

Three criteria differentiate HCC from metastatic tumor: Polygonal cells with centrally placed nuclei, malignant cells separated by sinusoidal capillaries and bile. Two additional criteria are: endothelial cells surrounding tumor cell clusters and intranuclear inclusions were identified as being important.[9]

Cholangiocarcinoma cases cytology smear showed small cuboidal to columnar cells arranged in glandular pattern with round hyperchromatic nuclei and scanty cytoplasm.

Metastatic nodule is more common than primary hepatic malignancy. The ratio of metastatic carcinoma to primary HCC in present study was 3.6 : 1 which is almost similar to Hertz et

al, 2000 (3:1).[10] Malignant tumor observed in an otherwise normal liver is metastatic until proved otherwise. The common sources of metastasis to liver are gastrointestinal tract, lung, breast and kidney.[8] Cytologically metastatic cells look foreign to liver. Benign hepatocytes are present in the background.

Among the metastatic lesions, adenocarcinoma showed glandular (figure 2) or acinar pattern, intra and extracytoplasmic mucin. These tumours mainly came from the GIT, breast, ovary and prostate. The special stain PAS and mucicarmine were done for glycogen and mucin. Adenocarcinoma was most common metastatic malignancy and colonic adenocarcinoma was commonest primary source for liver metastasis. However, in present study the frequency of metastatic adenocarcinoma (42%) was somewhat lower than the frequencies reported by Rasania et al[12] (86%), Talukder et al[3] (80%) and Mallikarjuna et al[11] (63%).

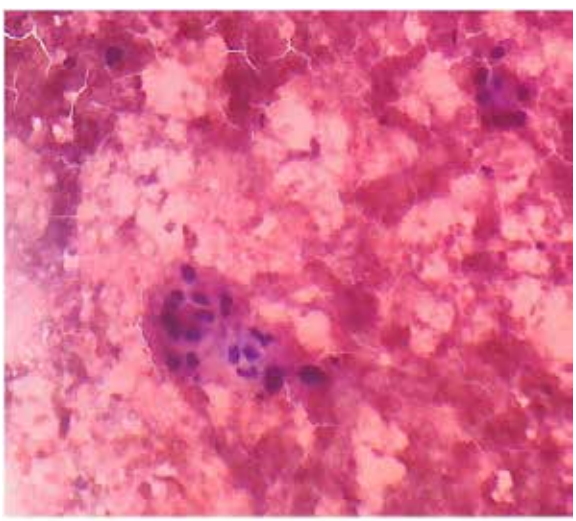

Figure 2: Metastatic adenocarcinoma to liver: columnar cells showing glandular arrangement (H and E stain, 200X).

The squamous cell carcinoma showed large squa mous cells arranged in syncytial pattern with baso philic cytoplasm and intracellular keratin. The cells were present in necro-inflammatory background. The small cell carcinoma showed small monomorphic cells with scanty cytoplasm and finely granular chromatin. Nuclear molding was consistent feature (figure 3).

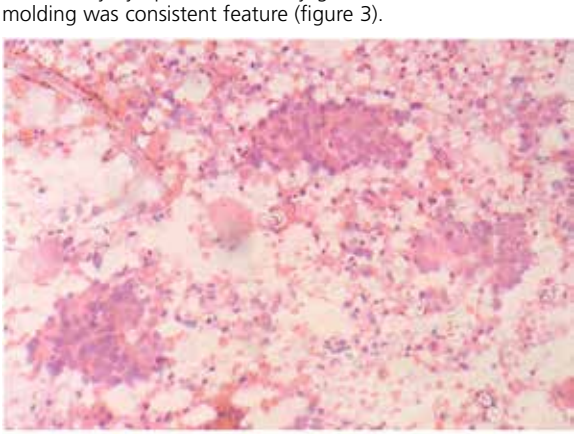

Figure 3: Small cells having scanty cytoplasm. Nucleus is hyperchromatic with inconspicuous nucle. Characteristic nuclear molding can be appreciated (H and E stain, 200X).

Cytological features which favored metastatic poorly differentiated carcinoma were the presence of benign hepatocytes, necrosis along with irregular clusters and dissociated anaplastic malignant cells.

Among primary malignant cases our study is similar to Rasania et al[12] and E D Gatphoh et al[13]. Most of the studies show metastatic tumor is outnumber than primary tumor in liver. Talukder et al[3] found highest number (91%) of metastatic carcinoma cases whereas Mallikarjuna et al[11] found higher number of primary malignant tumor(55.10%) as compare to metastatic tumor (44.89%).

Table: 5 comparisons of type of metastatic tumor in different studies (percentage)

Type of metastatic tumor	Mallikarjuna et al[11]	Rasania et al[12]	Talukder et al[3]	Present study
Adenocarcinoma	63.63	86.04	80.2	42
Squamous cell carcinoma	4.54	4.68	-	5.9
Round cell neoplasm	-	2.32	-	5.9
Small cell carcinoma of lung	-	2.32	-	17.6
Secondary from undefferentiated carcinoma	18.18	-	19.8	29.4

Mallikarjuna et al[11], Rasania et al[12] and talukder et al[3] all three found maximum number of metastasis is of adenocarcinoma type(table 5) but there percentage of cases were still higher (63.63%, 86.04%and 80.2% respectively) as compare to present study (42%). We found that a significant number of metastatic tumor were of undifferentiated type (29.40%), that could be due to more chances of distant metastasis in advance grade malignancy.

Distribution of benign lesion is different in Mallikarjuna et al[11], Rasania et al[12] and present study due to cases selection criteria and geographical differences. Both these investigator include focal as well as diffuse hepatic lesion in the study whereas we include only focal hepatic lesion. Mallikarjuna et al[11] found cirrhosis most common benign lesion and Rasania et al[12] normal liver. Talukder et al[3] found only one benign lesion out of 108 cases which was of amoebic liver abscess. Our study shows amoebic liver abscess is most common focal benign lesion in Saurashtra region.

Fine needle aspiration cytology has some inherent limitations. To diagnose properly sample must be representative of the lesion investigated and it should be adequate in term of cells and other tissue component. Lesion smaller than1 cm frequently difficult to definitively characterize by imaging methods, due to their small size, and difficult to biopsy percutaneously[14]. Often clinical follow-up is the only recourse for these lesions. FNAC has low sensitivity in diffuse liver diseases which require the use of tissue biopsies preferably representing six to twelve portal tract.[8]

In our study there was no complication of procedure recorded.

Conclusion

USG guided FNAC of liver is a rapid, reliable and cost-effective method for cytological diagnosis of focal hepatic lesions, however in a small number of cases satisfactory cellularity representative of lesion, is a concern. The recognition of the distinct cytomorphological features, in conjunction with the clinical data and radiological findings, make ultrasound guided FNAC useful primary diagnostic modality. Furthermore, by USG guided FNAC reliable results are obtained in most cases without serious complications related to the procedure.

ACKNOWLEDGMENT

WE ARE THANKFUL TO ALL THE PATIENTS USED IN THIS STUDY. WE ARE HIGHLY THANKFUL TO DR (MADAM) P.M. SANTWANI, HEAD OF DEPARTMENT PATHOLOGY. DUE TO PERMISSION, CONSTANT MOTIVATION AND GUIDELINE WE CAN COMPLETE THIS STUDY.

REFERENCES

1. Ji Xiao-Long. Fine-needle aspiration cytology of liver diseases. World J. of Gastroenterology, 1999 April; 5(2):95-97. | 2. ICMR (2004): assessment of burden of Non-Communicable diseases. | 3. Talukder SI, Huq MH, Haque MA, Rahman S, Islam SM, Hossain GA, Sarker CB, Saleh AF, Rahman MM, Ali MS. Ultrasound guided fine needle aspiration cytology for diagnosis of mass lesions of liver. Mymensingh Med J. 2004 Jan;13(1):25-9. | 4. Wee A, Nilsson B, Yap I, Chong SM. Aspiration cytology of liver abscess.With an emphasis on diagnostic pitfalls. Acta Cytol. 1995;39:453–62. [PubMed] | 5. Roy M, Bhattacharyya A, Dasgupta S, Sanyal S. Fallacies of fine needle aspiration cytology surgical lesion of the liver. J Indian Med Assoc. 1994;92:285–7. [PubMed] | 6. Radhika S, Rajawanshi A, Kochhar R, Kochhar S, Dey P, Roy P. Abdominal tuberculosis. Diagnosis by fine needle aspiration cytology. Acta Cytol. 1993;37:673–8. [PubMed] | 7. Pedio G, Landolt U, zobeli L, Gut D. Fine needle aspiration of liver: significance of hepatocyte naked nuclei in the diagnosis of hepatocellular carcinoma. Acta Cytol 32:437-442, 1988. | 8. Muhammad B. Zaman. Liver and Spleen.In: Leopold G. Koss, Myron R. Melamed, editors. Koss' Diagnostic cytology, 5th ed. New York: Lippincott Williams and Wilkins; 2006. pp.1389-1427. | 9. Bottles K, Cohen MB, Holly EA, Chiu SH, Abele JS, Cello JP, et al. A step-wise logistic regression analysis of hepatocellular carcinoma-An aspiration biopsy study. Cancer. 1988;62:558–63. [PubMed] | 10. Hertz G,Reddy VB, Green L, et al. Fine needle aspiration biopsy of the liver: a multicentre study of 602 radiologically guided FNA. Diagn cytopathol 23: 326-328, 2000. | 11. Mallikarjuna CM Swamy, CA Arathi, and CR Kodandaswamy Value of ultrasonography-guided fine needle aspiration cytology in the investigative sequence of hepatic lesions with an emphasis on hepatocellular carcinoma. J Cytol. 2011 Oct-Dec; 28(4): 178–184. | 12. Rasania A, Pandey CL, Joshi. Evaluation of FNAC in diagnosis of hepatic lesion. J Cytol 2007;24:51-4. | 13. Gatphoh ED, Gaytri S, Babina S, Singh AM. Fine needle aspiration cytology of liver: a study of 202 cases. Indian J Med Sci. 2003;57:22–5. [PubMed] | 14. Nasser Ebrahimi Daryani. TUMS e journal, Iranian journal of radiology 2009;6(S1) : 120 |