ORIGINAL RESEARCH PAPER

General Medicine

# EALES DISEASE- A RARE ENTITY FOR SUDDEN LOSS OF VISION

KEY WORDS:

| | |
|---|---|
| **Dr Polam Harshitha Reddy** | Professor Of General Medicine In Pesimsr, Kuppam. Ap India |
| **Dr Niharika Puligundla*** | Professor Of General Medicine In Pesimsr, Kuppam. Ap India *Corresponding Author |
| **Dr Reddy Bhargav** | Professor Of General Medicine In Pesimsr, Kuppam. Ap India |
| **Dr Suganeswari** | Professor Of General Medicine In Pesimsr, Kuppam. Ap India |
| **Dr N Nagarajan** | Professor Of General Medicine In Pesimsr, Kuppam. Ap India |

**ABSTRACT**

**INTRODUCTION :** eales disease ia an idiopathic obliterative vasculopathy that usually involves the peripheral retina of young adults. The frequency with which it is encountered makes eales disease a formidable diagnostic challenge.
**CASE HISTORY :** a 34 year old male consulted his primary physician at pes for sudden onset of blurring of vision in his left eye while working on his computer. Vision loss was complete with sensation of floaters,specks,zig zac lines. It was not associated with headache, limb weakness, loss of consciousness. His vitals were stable. Carotid pulsations were normal.no other neurocutaneous lesion of neurofibroma, arterial sclerosis, angioid streaks in pseudoxanthoma elasticum.no features suggestive of retinitis pigmentosa as in ataxic telanectasia.no historyof diabetes or hypertension.family history not significant. He was referred to shankara nethralaya (chennai). He underwent vision testing with fundus fluorescent angiography, which revealed peripheral retinal vessel sclerosis with constriction and vitreous haemorrhage.

**INVESTIGATIONS:** flouroscopy fundus, visual acuity testing, tunerculin skin test, chest x ray, and ct chest, ana profile.
Tset results: chest x ray appears normal . Ct chest normal study, tuberculin skin test 10mm induration with mild erythema , hiv status negative.ana profile negative.

**DIAGNOSIS:** after above investigations and proper history and physical examination, diagnosis of eales disease is made.

**COURSE AND TREATMENT :** he underwent laser photocoagulation , kept on prednisolone 80mg daily od dose. Patient was observed in hospital for 4 days.there was some improvemnt in vision with improvement in visual acuity and field of vision. Discharged on day 5 and advised to review once in 2 weeks for visual field testing and to taper immunomodulators. Due care is taken in administration of laser photocoagulation. After 2 weeks, during next visit patient vision further improved and prednisolone dose tapered.

**DISCUSSION:** eales disease is more common in india witha a prevalence of 1/200 in one million population.disease has association with tuberculosis,cns pathology (stroke,demyelinating disease)and more common in male gendre. It is one of the causes of acute loss of vision.other causes include sub acute myelo optic neuropathy,giant cell arteritis,vitreous hemmorrage,neuromyelitis optica(devic's disease) ,acute glaucoma.this case illustrates the potential for complete and irreversible loss of vision, if not diagnosed and treated with photocoagulation and steroids early. Although this condition is rare, it was a predictable diagnosis of exclusion. Early recognition of this disease is critical to institute appropriate therapy and prevention of permanant vision loss.

**CONCLUSION:** because of timely diagnosis of this disease ,timely intervention and treatment ,patient is able to recover completely and is performing his daily activities.

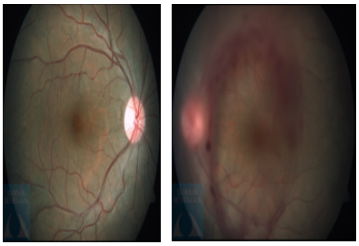

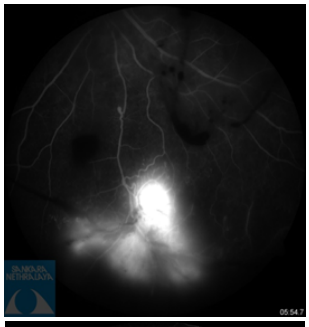





## REFERENCES

1) Saxena s,kumar d:a new staging system for idiopathic retinal periphlebitis eur j of opthalology 2004,14(3):236-239.
2) Madhavan hn ,therese kl,kavitha d:further investigations on the association of

mycobacterium tuberculosis with eales disease.indian journal of opthalmol 2002,50:35-39
3) Elliott aj:recurrent intra ocular hemorrhages in young adults ,eales disease :a preliminary report.treats serv bull 1949,4(7):35-42
4) Gupta a,gupta v,arora s,dogra mr,bambery p:pcr positive tubercular retinal vasculitis:clinical charactersitics and management.retina 2001,21(5):435-444.
5) Ishaq m,karamat s,niazi mk:hla typing in patients of eales disease.j coll physicians surg pak 2005,15(5)288-290.