Research Paper Medical science

Effect of Static Splinting in Patient With Claw Hand - A Case Study

Deepika Sharma	University College of Physiotherapy, Baba Farid University of Health Sciences, Faridkot, Punjab, India.
Smati Sambyal	University College of Physiotherapy, Baba Farid University of Health Sciences, Faridkot, Punjab, India.
Dheeraj KV	College of Physiotherapy, Christian Medical College, Ludhiana, Punjab, India.
Sandeep Kumar	University College of Physiotherapy, Baba Farid University of Health Sciences, Faridkot, Punjab, India.
Jaspreet Singh Vij	University College of Physiotherapy, Baba Farid University of Health Sciences, Faridkot, Punjab, India.

ABSTRACT

Hand injury is a critical condition, it not only creates enormous physical and emotional cost to the victim but also cause a financial burden to the society at large. The treatment of hand injury focuses on enabling people to return to an active and productive life within limits of their disability and preventing further injury. In recent times with advances in rehabilitation, functional activates like eating, writing, combing after hand injures are now made possible. Splinting is a well accepted modality in gaining joint motion in the injured hand there by maximizing functional use of hand. The purpose of the study was to evaluate the effect of static splinting on lumbrical muscle, in which, a 20 year old male patient, with flexor tendon injuries along with both ulnar and median nerve injury, has been taken. The patient was operated for repairing the tendon injuries and had been advised conventional physiotherapy along with static custom made splint for claw hand. Conclusions: The findings of the study indicate that the static splinting improves grip strength of hand as well as reducing the severity of claw hand.

KEYWORDS Finger splints; Hand injury; Claw hand; Lumbrical muscles

1. Introduction

The hand of the man is remarkable instrument capable of performing countless action, owing to its essential function. The prime function of hand is to grip, and movement in its numerous joints enables it to be moulded to the wide variety of shapes and sizes with which it comes in contact. Together with the brain, the hand is the most important organ for accomplishing tasks of adaptation, exploration, prehension, perception and manipulation unique to humans [(1)]. The complexity of the hand and the similarities in clinical presentation of different injuries make understanding of hand anatomy and function, good physical examination skills, and knowledge of indication for treatment indispensable for the emergency physician. A peripheral nerve lesion with significant sensory loss prevents functional use of the hand. The combination of sensory loss and motor imbalance in median and ulnar nerve lesions make it impossible to use hand normally [(2)]. Mixed nerve lesions provide the ultimate splinting challenge. Because multiple nerve involvement nearly always accompanies trauma to many other structures, a balance between increasing glide of soft tissues and constraint splinting for the denervated muscles is required. The most common mixed nerve lesion is concurrent injuries to median and ulnar nerve because they both lie on the palmer surface of the wrist. Divisions of these nerves rob the hand of all intrinsic muscles, and clawing of all four digits present. The human hand is designed for grasping, precise movement and for serving as a tactile organ. All of these characters increase the efficacy of the grip [(3)].

Splinting the hand with a peripheral nerve injury is both easy and difficult. Therefore, unlike many other hand injuries, the deformities resulting from isolated peripheral nerve paralysis are usually effectively splinted using standard splinting designs. The difficulty however, in splinting peripheral nerve paralysis arises from the impossibly of building a static external device that substitute for the intricately balanced muscles the splints attempt to replace [(4)].

The goal of the treatment is early rehabilitation, thus restoration and compensation of lost muscular function for physiotherapy.

2. Case Report

A 20 year old male patient, was referred to the Department of Physiotherapy, Christian Medical College and Hospital, Ludhiana, after surgical repair of an accidental injury of his right wrist (Verdans zone 5) with a sharp edge of drum at his work place resulting in a complete laceration of the radial artery, the ulnar and median nerve, and all flexor tendons. At 15 weeks post-surgery, the patient began to use the static splint in an attempt to correct the claw deformity. The patient was unable to grasp larger objects. There was no history of loss of consciousness or vomiting.

3. A Static Custom Splint

A Static custom made splint, made up of 5 ice-cream sticks, placed on the all four fingers of right hand and thumb, covered with a micro-pore tape on the ventral aspect of the hand. The splint was worn for short intermittent periods during the day while performing functional tasks as well as in the home exercise program. The treatment was given 6 days a week for 1 hour daily.

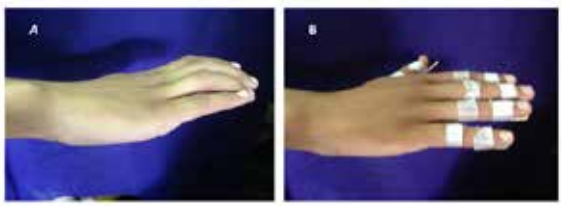

Fig1: (A) Lateral view of hand before splinting ; (B) Lateral view of hand after splinting.

4. Home Exercise Program
The Home Exercise Program was performed by moving the MCP and IP joints into extension from a flexed position for 10-15 slow, gentle repetitions, 5-8 times/day. Exercises progressively extending the MCP and PIP joints against a dynamic resistance, guided the patient to extend MCP and IP joints in a stable posture. This static splint allowed the optimal range of motion of all fingers and thumb.

5. Conventional Treatment
The patient underwent conventional treatment which includes infra-red radiation for 10 minutes, followed by passive joint mobilization of each joint with 10 repetitions. Electrical galvanic stimulation, with frequency less than 50 Hz, was given to lumbrical muscles, with 90 contraction. The treatment was given 6 days a week for 1 hour daily. The patient was assessed for book holding test and Functional Independence Scale (FIM) score.

6. Data analysis

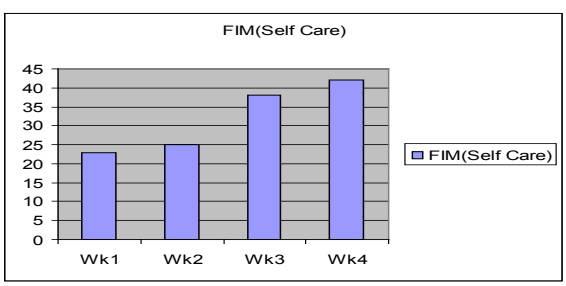

Fig 2: Graphical representation of improving in FIM score before and after intervention.

7. Results
The result of the study shows book hold test increased from mild to good and FIM Score improved from 25 initially to 42 by the end of the fourth week. It shows that the patient gradually improved on his precision work by the end of the 4th week due to increase in strength of his lumbrical muscles.

Table 1: Showing improvement in the scores of book test and FIM score.

Test	Week 0	Week 1	Week 2	Week 3	Week 4
Book Test	Not able to perform	Mild	Moderate	Moderate	Good
FIM Score	1	23	25	39	42

8. Discussion
Sterling bunnell considered the father of hand surgery wrote in the classic book about hand surgery, in a chapter which was dedicated to intrinsic muscles of the hand," the intrinsic muscles of the hand though tiny are important because with the long flexors long extensors, they complete the muscle balance in the hand[5]. In our study we also made a simple splint for patient which shows a great improvement and at the end of the 4th week lumbrical grip improves and activity of self care also able to perform. The peripheral-nerve splint will often restrict full tendon excursion. In longstanding denervation in which joint contractures have already developed one must first splint to regain joint motion before splinting the dynamic deformity. If we will see in Muscle reinnervation versus functional recovery Neurophysiologic testing, such as needle electromyography and nerve conduction studies, are capable to identify reinnervation potential after peripheral nerve injury.[7] Unfortunately, the authors did not have these methods available for use. Therefore, the authors cannot assert whether such muscles were fully reinnervated or not. The authors present two hypotheses to explain the outstanding outcome of this patient [6]. The "Torque Transfer Hypothesis" assuming that the intrinsic muscles were denervated, the patient would have developed a remarkable ability to transfer torque from the EDC to the IP joints, without MCP joint hyperextension. According to Strauch. When MCP joint hyperextension is prevented, EDC is capable of extending MCP, PIP, and DIP joints even in the absence of intrinsic muscle function. [7] It can be seen on Bouvier's test, where the MCP joints are taken out of hyperextension and the extrinsic extensors are then allowed to apply their force through the central slip in order to extend the IP joints.[8]

The "Neuromuscular Reeducation Hypothesis " given the post-surgery time and the expected axon growth rate, it seems feasible the intrinsic muscles were partially reinnervated at 16th week post-surgery. Even then, the patient was not able to extend both MCP and IP joints without production of claw posturing. Muscle reinnervation does not mean return of the muscle function. Recovery of synergistic function involves much more than just axonal regeneration and connectivity. Restoring appropriate biomechanical balance between intrinsic and extrinsic finger extensors may require specific muscle training.

9. Conclusion
It has been concluded that the individual static splint used for fingers helps the patient in increasing the strength of the lumbrical muscles and thereby reducing the clawing of fingers. Further it is recommended that a similar study may be performed to compare between to effectiveness of these individual splints over dynamic splints in the strengthening of interossei muscles.

REFERENCES

1. Contribution of the intrinsic muscles to grip and pinch strength,Scoot H.Kozin,Scoot Porter jan 1999 volume 24,pages 64-72 | 2. Hand therapy for Dysfunction of the intrinsic muscles,2012 Feb,page 87-100 | 3. Effect of dynamic orthotic in an individual with claw hand, Gudson G.Q Sousa PT2015(15-20) | 4. Essentionals of Orthopedices by Measahawari | 5.Bunnell S. Surgery of the Hand. JB Lippincott: Philadelphia, 1944; 315 | | 5. Hand Rehabilitation A practical guide edited by Gayiord L Clark | 6. Krarup C, Archibald SJ, Madison RD. Factors that influence peripheral nerve regeneration: an electrophysiological study of the monkey median nerve. Ann Neurol. Jan 2002;51(1):69e81. | 7. Strauch RJ. Extensor tendon injury. In: GreenDP, Kozin SH, eds. Green's Operative Hand Surgery. 6th ed. Philadelphia: Elsevier; 2011:161. | 8. Sapienza A, Green S. Correction of the claw hand. Hand Clin. Feb 2012;28(1): 53e66.