ORIGINAL RESEARCH PAPER

Otolaryngology

KEY WORDS: liposarcoma; thick septa; globular features

HINT FOR HEAD AND NECK MALIGNANT LIPOSARCOMA - 4 CASES SERIES REPORT

Tengchin Wang* MD, Department of Otolaryngology, Tainan Municipal Hospital (Managed By Show Chwan Medical Care Corporation), Tainan City, Taiwan *Corresponding Author

ABSTRACT

Background: Liposarcoma is a category of sarcoma generally originates from deep soft tissue in the extremities and retroperitoneal spaces and rarely occurs in the head and neck region. The challenges exists in diagnosing between lipoma and liposarcoma due to histological similarities. However, the specific radiolodical features can help to identify the malignant lipomatous lesions.

Method: We reviewed the images of the 4 patients who were diagnosed with liposarcoma between 1996 and 2013. We assessed the radiological features according to the literature reports.

Results: These cases showed the characteristic findings : (1) fat less than 75% of the tumor volume in all patients, (2) the presence of thick septa (Figure 1b, 2a, 4), and (3) nodular or globular features

Conclusion: These radiological features can indicate malignancy and are helpful in accurately diagnosing liposarcoma.

Background:

Liposarcoma is a category of sarcoma commonly found in adults that generally originates from deep soft tissue in the extremities and retroperitoneal spaces. However, liposarcoma rarely occurs in the head and neck region. It typically presents as a painless, slowly enlarging mass, only becoming symptomatic when infringing upon surrounding structures. Currently, the World Health Organization classifies 4 variants (WHO also recognizes a fifth variant, dedifferentiated type) based on Enzinger and Weiss.1 Histological similarities exist between lipoma and liposarcoma ; therefore, accurate diagnosis is quite challenging. However, numerous studies have proposed specific radiolodical features of liposarcoma that can help to distinguish it from benign lipoma.

Method:

We retrieved 4 patients between 1996 and 2013 who were diagnosed with liposarcoma. Table 1 lists the patient demographics, lesion site and histological findings. Image findings among these patients were reviewed retrospectively. A computed tomography scan (of 3 patients) and magnetic resonance imaging (of one patient) were conducted. We assessed the fat percentage according to the grading system presented in Einarsdottir et al[2]; the thickening septa (thicker than 2 mm or exhibiting focal thickness) and nodular feature of the nonadipose region were evaluated and defined according to Kransdorf et al report.[3]

Result:

Patient A exhibited a rapid growing facial mass without presentation of facial palsy (from 3x3x2 cm to 10x5x9 cm within 2 months). Computed tomography (CT) scan showed a huge mass with predominant fat attenuation. The central soft-tissue component and thick septations were visible (Figure 1). The result of initial biopsy had highly suspicious of sarcoma. Tumor wide excision was performed.

Patient B exhibited painless right submandibular mass for 2 years. CT scans revealed fat attenuation with streaky structures and septa with soft tissue density (Figure 2). Tumor wide excision was performed under the suspicious of liposarcoma according to CT findings.

Patient C received excision of hypopharyngeal fibrolipoma in 2002. He suffered from local recurrence and received local excision for organ preservation, and was diagnosed with well-differentiated liposarcoma. Pathologist reviewed previous specimens and identified some malignant cell incidentally. His CT findings revealed a hypopharyngeal mass that exhibited nodular pattern with densities between those of fat and muscle (Figure 3).

Patinet D received resection of right pyriform giant fibroepithelial polyp in 1996. She exhibited progressive dyspnea with dysphagia and local recurrence was suspected. Biopsy revealed liposarcoma. MRI exhibited high signal intensity mass. The streaky structures and nodular pattern were seen (Figure 4).

All of the patients were diagnosed with well-differentiated liposarcoma , with foci of dedifferentiation observed in one patient (Patient A).Their images revealed specific findings: (1) fat less than 75% of the tumor volume (Figure 1, 2, 3, 4), (2) the presence of thick septa (Figure 1b, 2a, 4), and (3) nodular or globular features (Fig 1a, 3b, 4). Those findings are similar to those of other studies.[2-4]

Conclusion:

Liposarcoma can be easily misdiagnosed clinically; its relatively indolent course often results in a misdiagnosis as benign lipoma. Numerous studies have identified the radiological features of malignant lipomatous lesions. These patients in our series also demonstrated the typical image findings: (1) fat content less than 75% of the tumor volume, (2) presence of thick septa, as well as, (3) nodular mass like area in the nonadipose region. These radiological features can indicate malignancy and are helpful in accurately diagnosing liposarcoma by evaluating the highly suspicious part. Therefore, patients would benefit from early diagnosis and must receive thorough treatment.

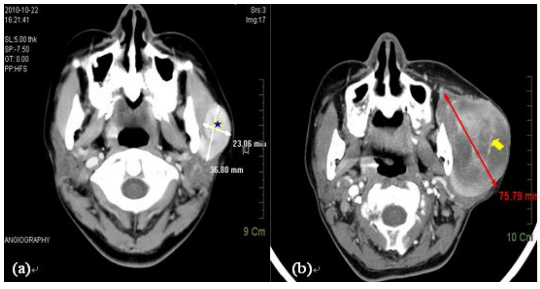

Figure 1. Left facial huge liposarcoma. (a) and (b). Axial CT image with contrast. The fat content is predominant attenuated. Non-fatty tumor component is composed of septa with various thickness (arrow in b), as well as confluent nodule (asterix in a).

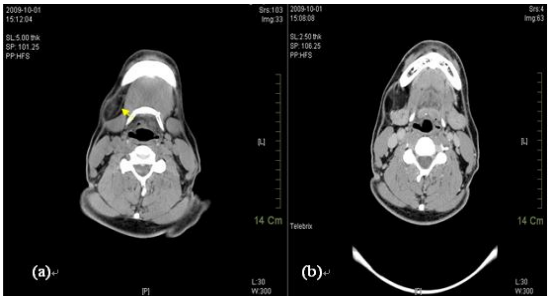

Figure 2. Right submandibular area liposarcoma. (a) and (b).Axial CT image. The fat content is assessed as 1-75% of the tumor volume. Non-fatty tumor component is composed of thick septa (arrow in a) and amorphous-hazy high density (both a and b).

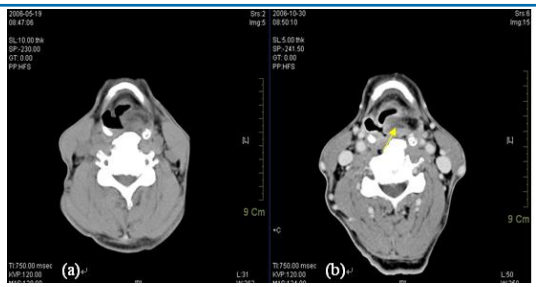

Figure 3. Hypopharyngeal liposarcoma. (a) and (b) Axial CT image. The fat content is assessed as 1-75% of the tumor volume. The nonadipose nodule is exhibited (arrow in b).

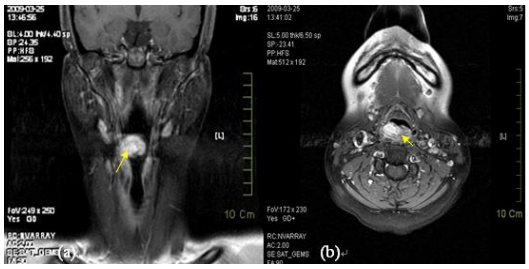

Figure 4. Hypopharyngeal liposarcoma. (a) Coronal T1 weighted MR with contrast and (b) Axial T1 weighted MR with contrast. MR image showed fat content is assessed as 1-75% of the tumor volume. The nonadipose globular region with focal thickening of septa are shown (arrow in a and b)

Table 1 Lesion location, histology and management

Patient no.	Age	Gender	Location	Histology	Management
A	21	F	Facial/Parotid area/Masticator space	WD[§] with foci of Dedifferentiation	Wide Excision + post-op R/T[α]
B	49	M	Submandibular area	Atypical lipomatous mass/ WD[§]	Wide Excision
C	72	M	Hypopharynx	WD[§]	1.Local excision+ post-op R/T 2.Local excision[β]
D	46	F	Hypopharynx	WD[§]	Wide excision

§ well-defferentiated

α safe margin less than 1 mm due to preserve facial nerve

β local recurrence after local excision by CO2 laser with adjuvant radiotherapy (interval : 8 months)

Reference

1. Enzinger FM, Weiss SW. Liposarcoma. In Soft tissue tumours. 2nd edition. St. Louis, MO: Mosby-Year Book; 1988:346-382.
2. Einarsdottir H, Soderlund V, Larsson O, et al. 110 subfascial lipomatous tumors. MR and CT findings versus histopathological diagnosis and cytogenetic analysis. Acta Radiol 1999; 40: 603-609
3. Kransdorf MJ, Bancroft LW, Peterson JJ et al. Imaging of fatty tumors: distinction of ipoma and well-differentiated liposarcoma. Radiology. 2002 Jul;224(1):99-104.
4. Ryoko SUZUKI, Hideomi WATANABE, Takashi YANAGAWA et al. PET evaluation of fatty tumors in the extremity:Possibility of using the standardized uptake value (SUV) to differentiate benign tumors from liposarcoma. Annals of Nuclear Medicine 2005; 19(8): 661-670,