ORIGINAL RESEARCH PAPER

Cardiology

KEY WORDS: Bifurcation, Percutaneous coronary intervention, Side branch predilation.

IMPACT OF SIDE BRANCH PREDILATION BEFORE MAIN VESSEL STENTING ON PROCEDURAL OUTCOMES IN CORONARY ARTERY BIFURCATION LESIONS

Balaji Pandian P Assistant Professor, Institute Of Cardiology, Madras Medical College. Chennai-3

Rajasekar Ramesh* Assistant Professor, Institute Of Cardiology, Madras Medical College. Chennai-3 *Corresponding Author

Swaminathan. N Director, Institute Of Cardiology, Madras Medical College. Chennai-3

ABSTRACT

Background: A simple approach is the predominant strategy for the percutaneous coronary intervention of bifurcation lesions. Performing side branch (SB) predilation in this context is currently a matter of controversy. In this study, we assess the efficacy of SB predilatation before a provisional T-stent strategy for bifurcation lesions.

Methods: 41 patients with true bifurcation lesions were randomized to either predilation of the SB (n = 21) or no predilatation (n = 20) before main branch (MB) stent implantation.

Results: After MB stent implantation, the TIMI flow of the SB was higher in the patients with SB predilation. The failure rate of SB rewiring, the time of rewiring, the number of wires used, and the incidence of major events were similar in both groups of patients.

Conclusions: Predilation of the SB resulted in improved TIMI flow after MB stenting and less indication to subsequently treat the SB. If rewiring of the SB is required, predilation did not hinder this maneuver.

BACKGROUND

Bifurcation lesions remain a therapeutic challenge and present an increased risk of complications. It also seems clear that the provisional stenting strategy, using only one drug-eluting stent(2) in the main vessel (MV), is the first choice of treatment for most patients. Simple approach or provisional side branch stenting is the current preferred strategy for the PCI of bifurcation lesions. The procedure could be so simple. After main vessel stent implantation, compromise of the side branch ostium or even complete occlusion of the vessel may occur(1). Predilation of the side branch could improve the patency of and the TIMI III flow of this vessel after main vessel stent implantation. Based on observational studies, some experts have recommended avoiding side branch predialtaion(5).

MATERIALS AND METHODS

41 patients with bifurcation lesions (1,1,1), (0,1,1), (1,0,1) treated with provisional stenting were alloted in a non randomized manuver to either side branch predilation or no predilation of SB, before stenting of the main vessel.

Inclusion criteria

Patents with stable angina or acute coronary syndromes or inducible ischemia, who had a lesion located in a major bifurcation point, regardless of morphology and angulation.

Main vessel ≥ 2.5 mm diameter.
SB ≥ 2.25 mm diameter.

Significant stenosis at SB ostium by visual inspection (Medina {1,1,1}, {0,1,1}, {1,0,1})

Any stenosis length at main vessel and a stenosis length ≤ 5 mm at the SB.

Exclusion criteria

- Patients with contraindications to one-year antiplatelet therapy.
- Cardiogenic shock.
- Coexisting severe comorbidities.
- Impossibility to place a wire at the SB before MV stent implantation.

Primary end point

TIMI flow at side branch after main vessel stent implantation.

Secondary end point

Need for side branch Postdilation
Time of rewiring
Number of used wires
% stenosis at the side branch
Levels of markers of myocardial damage after the procedure

Table:1 BASELINE CHARACTERS

	Side branch Predilatation (n=21)	No side branch Predilation (n=20)
CLINICAL		
AGE (years	55+10	53+9
MALE%	14	12
SMOKING	13	11
CHOLESTEROL	15	14
HYPERTENSION	12	11
DIABETES	10	9
ACS	12	13
BIFURCATION LESIONS		
LAD	15	14
LCX	3	2
RCA	3	4
MEDINA CLASSIFICATION		
1,1,1	16	14
1,0,1	2	2
0.,1,1	3	4

TABLE:2

	Side branch Predilatation (n=21)	No side branch Predilation (n=20)
Side branch Predilatation	50±5	51±4
MAIN VESSEL		
SIZE	2.75±0.4mm	2.6±0.3mm
LESION LENGTH	20±8 mm	18±7 mm
MINIMAL LUMEN		
BASELINE	0.60± 0.4	0.70± 0.4
POST PRECEDURE	2.70± 0.4	2.60± 0.4
%STENOSIS.		
BASELINE	80+5	70+5
POST PROCEDURE	10+5	10+5
SIDE BRANCH		
SIZE	2.25+0.4mm	2.1+0.3mm
LESION LENGTH		
MINIMAL LUMEN		
BASELINE	0.70+ 0.4	0.90+ 0.4
POST PRECEDURE	2.0+ 0.4	2.25+ 0.4
%STENOSIS.		
BASE LINE	60+5	50+5
POST PROCEDURE	10+5	20+5

DISCUSSION

FLOW CHART

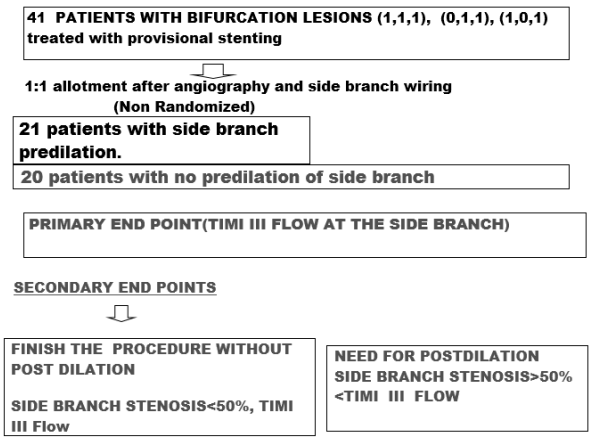

Predilatation of the SB before main vessel stenting was performed in 21 patients. The baseline clinical characteristics were not significantly different between the groups. TIMI flow 0 to 1 was noted in 20% (n=4) in predilated group versus 10%(n=2) in no predialation group. P< .001. TIMI flow III was noted in 80% (n=17) in predilated group versus 60 %(n=12) in no predialation group. P< .001; In addition, 15 patients (70%) from the SB predilation group presented SB residual stenosis by visual inspection <50%, and TIMI flow ≥III did not require any additional treatment. The procedural success rate for SB was higher in the predilatation group, even though there were no significant differences in the rate of PCI-related acute closure in the main vessel or SB(1).

Predilation lowers the risk of SB compromise after MV stenting, and also relieves the ischemia in the myocardial territory of SB(6). But it may complicate the procedure with the higher risk of peri-procedural MI, and increase the risk of SB dissection. Side branch predilatation may lead to dissection of the SB and increase the risk of recrossing the more proximal strut through a dissection plane(3).

Recent randomized trial, however, showed that the predilation reduced the risk of SB compromise after the MV stenting(4). Long-term clinical outcome was not improved by predilation in these studies. So predilation is reasonable way to prevent SB compromise in the high-risk lesion. But the operators should be careful not to make dissection in SB, which will complicate the SB rewiring after MV stenting, if needed.

Study Limitations

The present study has several limitations. First, this study was not randomized and therefore potential confounding factors may have significantly affected the results. For example, predilatation of the SB was performed more frequently in patients with unfavorable lesion characteristics, according to the operators' decision. Unavoidably, therefore, the groups were unequal.

CONCLUSION

Predilatation of the side branch in patients with true bifurcation lesions is a useful maneuver. Predilation of the SB resulted in improved TIMI flow after MB stenting and less indication to subsequently treat the SB(4). If rewiring of the SB is required, predilation did not hinder this maneuver. Predilation of the SB is recommended when SB compromise after MV stenting is highly anticipated, such as in long ostial SB lesions or heavily calcified lesions(2).

REFERENCES

1. Ghassan S. Kassab, PhD; Gerard Finet , MD, PhD Anatomy and function relation in the coronary tree: from bifurcations to myocardial flow and mass Eurointervention 2015;11.suppl V:V13-7
2. Colombo A, Moses JW, Morice MC, Ludwig J, Holmes DR, Spanos V, et al. Randomized study to evaluate sirolimus-eluting stents implanted at coronary bifurcation lesions. Circulation.2004;109:1244-9.
3. Song YB, Hahn JY, Song PS, Yang JH, Choi JH, Choi SH, et al. Randomized comparison of conservative versus aggressive strategy for provisional side branch intervention in coronary bifurcation lesions: results from the SMART-STRATEGY (Smart Angioplasty Research Team-Optimal Strategy for Side Branch Intervention in Coronary Bifurcation Lesions) randomized trial.JACC Cardiovasc Interv. 2012;5:1133-40.
4. ManuelPanMD, PhD,AlfonsoMedinaMD, PhD MiguelRomeroMD, PhD SoledadOjedaMD, PhD PedroMartinMD, PhD JavierSuarez de LezoMD, PhD JoseSeguraMD, PhD FranciscoMazuelosMD, PhD JoseNovoaMD, PhD JoseSuarez de LezoMD, PhD Assessment of side branch predilation before a provisional T-stent strategy for bifurcation lesions. A randomized trial. American Heart Journal 2014 Sep;168(3):374-80. doi: 10.1016/j.ahj.2014.05.014
5. Joo-Yong Hahn, Woo Jung Chun, Ji-Hwan Kim, Young Bin Song, Ju Hyeon Oh, Bon-Kwon Koo, Seung Woon Rha, Cheol Woong Yu, Jong-Sun Park, Jin-Ok Jeong, Seung-Hyuk Choi, Jin-Ho Choi, Myung-Ho Jeong, Jung Han Yoon, Yangsoo Jang, Seung-Jea Tahk, Hyo-Soo Kim, Hyeon-Cheol Gwon. Predictors and Outcomes of Side Branch Occlusion After Main Vessel Stenting in Coronary Bifurcation Lesions: Results From the COBIS II Registry (COronary BIfurcation Stenting) Journal of the American College of Cardiology, Volume 62, Issue 18, 2013, pp. 1654-1659
6) GWON HC MD., PhD. Understanding the Coronary Bifurcation Stenting. Korean Circ J. 2018 Jun;48(6):481-491. Published online April 13, 2018. https://doi.org/10.4070/kcj.2018.0088.