Research Paper Pathology

Large Scale Study of H1N1 Influenza Cases: A Novel Approach Using Post-Mortem Needle Biopsy

Dr. Savita S. Patil	MD Department of Pathology, First floor, B J Medical College, Sassoon Hospital Compound, Station Road, Pune, Maharashtra, India,411001
Dr. Puranik S C	MD Department of Pathology, First floor, B J Medical College, Sassoon Hospital Compound, Station Road, Pune, Maharashtra, India,411001
Dr. Kulkarni K K	MD Department of Pathology, First floor, B J Medical College, Sassoon Hospital Compound, Station Road, Pune, Maharashtra, India,411001
Dr. Kudrimoti J K	MD Department of Pathology, First floor, B J Medical College, Sassoon Hospital Compound, Station Road, Pune, Maharashtra, India,411001
Dr. Kadgi N V	MD Department of Pathology, First floor, B J Medical College, Sassoon Hospital Compound, Station Road, Pune, Maharashtra, India,411001

ABSTRACT

Considering few H1N1 pathology reports based on autopsies & biopsy studies only in seasonal influenza; our series of 70 postmortem needle biopsies in H1N1 Influenza is worth documenting. Decedents with severe respiratory illness & strong clinical suspicion of H1N1 influenza in 2009 pandemic were studied. Nasopharyngeal swabs for RT-PCR & post mortem biopsies were taken. 51.4% were H1N1 positive & 48.6% were negative on RT-PCR. Most of H1N1+ve cases showed interstitial pneumonia & intra-alveolar hemorrhages & DAD in lung & fatty change in liver. Similar histopathology of majority of H1N1 RT-PCR negative & positive cases prompts need for confirmation of negative cases by ancillary methods. Rapid & safe diagnosis of H1N1 Influenza can be obtained by biopsy if supplemented by IHC to get accurate estimate of disease prevalence & mortality. Sufficient biopsy sampling can provide insight into H1N1influenza pathology & eliminate need for autopsies considering high infectivity of disease.

KEYWORDS H1N1 influenza, post mortem, needle biopsy, RT-PCR.

Introduction:

Influenza A (H1N1) virus is a result of a genetic re-assortment of endemic strain of human, avian and swine flu, with an inherent ability to mutate continuously; and is causing present flu in humans.[4] The 'herald wave' of the H1N1 pandemic spread from Mexico to the United States in spring 2009.[5] It has swept the globe with unprecedented speed as a result of airline travel. On June 11, 2009, the World Health Organization raised its pandemic alert to the highest level, Phase 6, indicating widespread community transmission in at least two continents.[2,3] The Indian Sub-continent was also affected in this pandemic with the maximum number of cases seen in the Pune region in the state of Maharashtra. In August 2009, the first death of Influenza A (H1N1) in India occurred in Pune followed by a series of fatalities till date.

There are a relatively few reports on pathology of H1N1 influenza. Of these all were based on complete post-mortem examination.[4-8] A few lung biopsy studies have been done earlier but only in cases of seasonal influenzal pneumonia.[9,10]

Further, the magnitude of the present study is second only to that in a previous study done at the CDC involving 100 cases.[6]

In this context, we thought our series of 70 post mortem needle biopsies was worth documenting ,which employs needle biopsy as a simple yet effective tool. Rapid and safe diagnosis of Novel H1N1 Influenza can be obtained by needle biopsy especially if supplemented by ancillary methods such as Immunohistochemistry.[6] Sufficient sampling by needle biopsies can provide an insight into the pathology of H1N1 Influenza, and thus eliminate the need for complete post-mortem examination, considering the highly infectious nature of the disease.

Materials & Methods:

The case was defined as a patient who presented with severe and acute respiratory illness with strong clinical suspicion of H1N1 influenza and later succumbed to death despite medical intervention, in a setting of known H1N1 pandemic.

Nasopharyngeal swabs were sent for RT-PCR at National Institute of Virology, Pune.

Simultaneous needle biopsies were taken from these cases after declaration of death.

The biopsies were taken from lung (69), liver (66), kidneys (37) and heart (7).

These biopsies were fixed in 10% Formalin, routinely processed, sectioned at 3-5µ thickness and stained with Hematoxylin and Eosin.

Microscopic examination was done by a panel of expert histopathologists in our department.

The results were tabulated and correlated with the demographic and clinical data as well as RT-PCR status.

Observations and Results:

During August 2009 to November 2009, total 70 cases were biopsied; the organ-wise distribution of biopsies is as given in table 1.

Table 1:
Organ-wise distribution of post-mortem needle biopsies

Biopsied Organs	Number of cases (%)
Lung	70 (100%)
Liver	66 (94.3%)
Kidney	37 (53%)
Heart	7 (10%)

Out of the 70 cases, 36 (51.4%) were H1N1 positive and 34 (48.6%) were H1N1 negative on RT-PCR.

The post-mortem biopsy findings were correlated with the clinical data .All patients presented with fever, cough, and respiratory distress. Few patients also had complaints of throat pain, hemoptysis, bodyache and diarrhea. All patients showed radiographic changes suggestive of ARDS and needed ventilatory support.

As per Table 2, most of the cases were in the first decade of life followed by those in the third decade. A female predominance was noted with Male:Female ratio of 0.6:1.

TABLE 2:
Age and Sex distribution

Age group(yrs)	H1N1+ve(n=36)		H1N1-ve(n=34)		Total (N=70)
	Male	Female	Male	Female	
0-10	4	6	3	5	18
11-20	0	2	2	3	7
21-30	1	8	1	3	13
31-40	4	4	5	2	15
41-50	3	2	0	6	11
51-60	2	0	0	1	3
61-70	0	0	0	2	2
71-80	0	0	0	1	1

As shown in Table 3,preexisting medical conditions, predominantly Rheumatic heart disease and pregnancy followed by Diabetes and Hypertension were noted in 17 (24.3%) H1N1 positive cases.

TABLE 3:
Preexisting medical conditions

Preexisting medical conditions	H1N1 + ve cases	H1N1-ve cases
Rheumatic heart disease	4	0
Pregnancy	4	1
Diabetes	2	1
Hypertension	2	1
Congenital heart disease	1*	0
Asthma	1	0
Psychiatric illness	1	0
HIV	1	0
Obesity	1	2

***Patent Ductus Arteriosus**

Microscopic Findings:
On histo-pathological examination (HPE), 19 (27.5%) lung, 3 (4.5%) liver, 1 (14.3%) heart & 28 (75.7%) kidney samples showed inadequacy.

Table 4 shows spectrum of HPE changes in lung. Majority of the H1N1+ve cases showed interstitial pneumonia followed by intra-alveolar hemorrhages, diffuse alveolar damage and cytopathic effect in alveolar epithelium. Other findings observed were bronchopneumonia, pulmonary edema, partial collapse and necrotizing pneumonia. Vasculitis and squamous metaplasia were the findings in occasional cases. A similar spectrum of HPE changes was also noted in H1N1 negative cases in a comparable manner.

TABLE 4:
Spectrum of histopathological changes in Lung

Histopathological changes	H1N1+ve cases(n=36)	H1N1-ve cases(n=34)
Interstitial pneumonia	14	9
Intraalveolar hemorrhages	10	11
Diffuse alveolar damage	9	8
Cytopathic effect	7	6
Bronchopneumonia	5	8
Necrotising pneumonia	3	0
Partial collapse	5	7
Pulmonary edema	5	4

Figure1

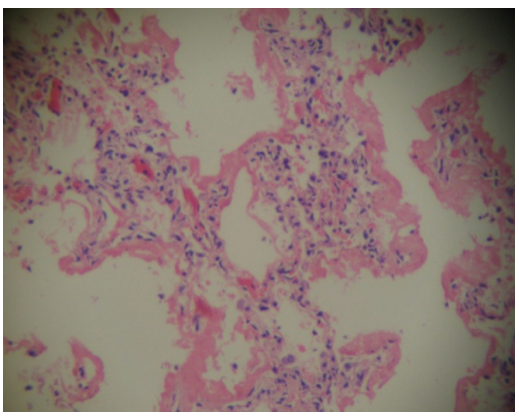

diffuse alveolar damage

Figure 2

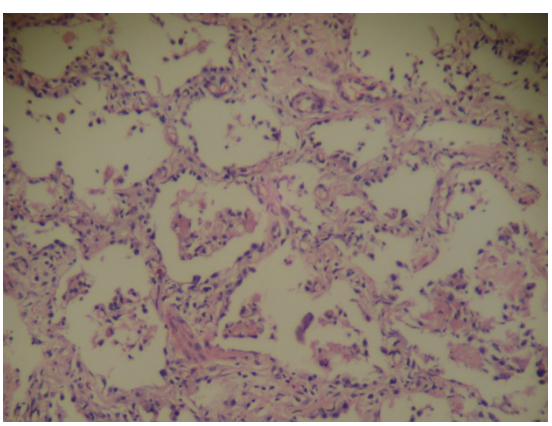

interstitial pneumonia

Figure 3

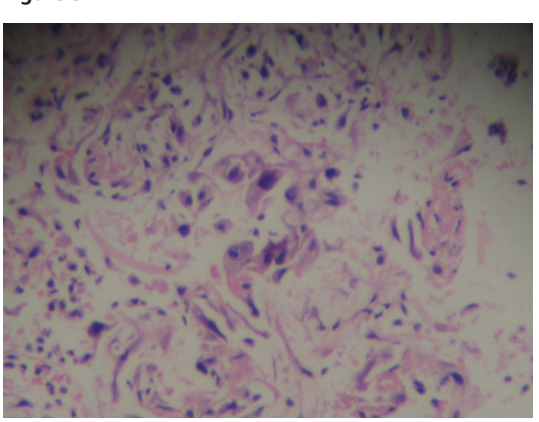

cytopathic effect

Liver also showed distinctive findings. As evident from Table 5, majority of the H1N1 positive cases showed diffuse fatty change, portal triaditis and kupffer cell hyperplasia. Other findings were hepatocyte drop out necrosis and sinusoidal neutrophilic infiltrate. Sub-massive liver necrosis and focal parenchymal hemorrhages were noted in occasional cases.

Table 5:
Spectrum of histopathological changes in Liver

Histopathological changes	H1N1 +ve cases	H1N1-ve cases
Fatty change Portal triaditis	33 15	21 12
Kupffer cell hyperplasia	9	6
Hepatocyte drop-out necrosis	2	1
Sinusoidal neutrophilic infiltrate	2	2

Figure 4

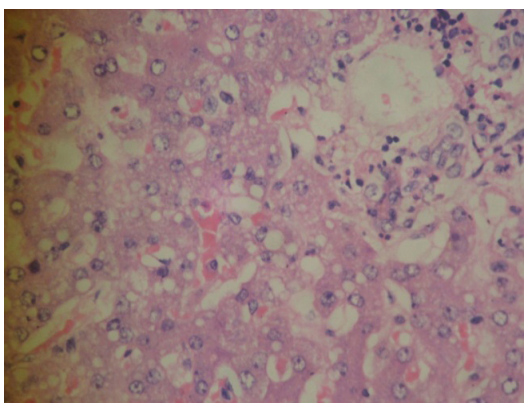

fatty change

As in lungs, liver biopsies of H1N1 negative cases also showed a similar pattern of HPE changes as that of the H1N1 positive cases.
In few cases kidney and heart biopsies were also received, of which some were inadequate for definitive comment while others did not show any peculiar change.

Discussion:
The most common organ biopsied in our study was lung (98.6%) and the most common pathology observed in H1N1 Positive cases (n=36) was Interstitial pneumonia (38.89%), followed by intra-alveolar hemorrhage(27.78%), and Diffuse alveolar damage(25%).

This was in contrast to previous studies which found diffuse alveolar damage as the most common lung pathology in H1N1.[4-7] However ,Gill et al reported viral pneumonia with focal or diffuse DAD as the predominant finding.[8]

In our study, cytopathic effect was prominently noted in 19.4% H1N1 positive cases, which was comparable to findings of Mauad et al[4] (23.8%), and was strikingly in contrast with Harms et al[7] who ruled out the possibility of any such specific cellular alterations in influenza.

Pulmonary thromboembolism which was observed very commonly in previous studies [4,5,7,8] was not seen in any of our cases.

Necrotising bronchitis/ bronchiolitis are considered to be classic features of influenza pneumonia and were observed by other researchers.[4,11] However, these findings were not seen in our series which was in accordance with studies by Mukhopadhayaya et al.[6]

Hemophagocytosis as reported by Harms et al[7] was not seen in our series.

Ours being a needle biopsy study, the amount of lung tissue studied was very scanty as compared to that in autopsy studies done by other researchers.This could explain the disparity regarding DAD being not the most common pulmonary pathology in this series, and the absence of Bronchitis/bronchiolitis and thromboembolism.

Two early reviews of severe cases of 2009 H1N1 influenza A pandemic showed no evidence of bacterial pneumonia among 30 cases in California[12] and 10 cases in Michigan.[13]

However, 13.9% H1N1 positive cases in this study showed bronchopneumonia, suggesting bacterial co-infection which was also documented by Sheih[5] and Louie J et al.[14]

These findings are in accordance with Louie et al[14] and thus underscore the importance of Pneumococcal vaccination for persons at increased risk of pneumococcal pneumonia, as well as the need for early recognition of bacterial pneumonia in persons with influenza since these patients will need antibacterial therapy in addition to antiviral drugs.

The most common liver pathology observed in our case series was fatty change, seen in 91.67% cases. This is in accordance with Esper et al[15], whereas Harms et al [7]did not find any specific pathology in liver. Duchini et al were of the opinion that hepatic dysfunction is an uncommon complication of Influenza A H1N1.[16] The pathogenesis of fatal illness and extrapulmonary involvement associated with Influenza A H1N1 is still not well understood. Liver affection during Influenza virus infection has been shown in experimental animal models.It was proposed that no viral replication is needed to produce hepatic damage as there is evidence of hepatic oxidative stress and decrease in antioxidant defenses even when the virus is isolated only from the lung.This might be explained by the production of Interleukin-6 (IL - 6), IL-8, IL-10,Tumour Necrosis Factor α (TNF α),Interferon α , β and γ in the respiratory airway that leads to changes in fatty acid metabolism and decrease activity of enzymes like ornithine carbamyl transferase (OCT)[17], succinic dehydrogenase with impaired β-oxidation of palmitic and octanoic acids at mitochondrial levels producing an increase in fatty liver deposits and loss of glycogen in the liver parenchyma.[16,18]

Murphy described that Influenza viruses can directly activate monocytes and polymorphonuclear leucocytes that generate reactive oxygen species (ROS) by an increase in the activity of the xanthine/xanthine oxidase (superoxide generating enzyme) and decrease in the superoxide dismutase, producing oxidative stress with decreased concentrations of antioxidants such as Vitamin C and glutathione in the early stages of infection.[18] The findings in the study of liver injury and viral influenza infection in animal models supported that the primary insult to produce liver injury was the overproduction of free radicals by the host immune response and the diminished production of mitochondrial antioxidants by the hepatocytes.

Common extrapulmonary complications of Influenza include myositis, renal failure, myocarditis, pericarditis and meningoencephalitis.[19]

However, myocarditis was not noted in our study which was in accordance with studies by Sheih.[5]

In the present series, 24.3% H1N1 positive cases presented with pre-existing medical conditions contributed mainly by rheumatic heart disease, pregnancy followed by diabetes and hypertension. Similar as well as additional co-morbid conditions were noted in studies by different authors as well of which obesity and cardiovascular diseases were more common among all these studies.[4,5,7,8] The pregnant females in our case studies were more prone to develop fatal H1N1 influenza (11%) as compared to the study group of Gill et al(6.25%).[8]

The most interesting finding in the present series was the

striking resemblance of most of the H1N1 RT-PCR negative cases to the positive cases with respect to HPE changes in lungs and liver. Out of the 70 cases, 34 cases were highly suspected clinically as H1N1 influenza, however, the RT-PCR was negative. The presence of similar HPE findings in both the study groups is confusing.The RT-PCR has a sensitivity and specificity of 99.3 % and 92.3% respectively, which rules out any doubts over the capability of RT-PCR. But the fact that the two groups demonstrated similar HPE findings should prompt further confirmation of the H1N1 negative cases in our case series by other ancillary methods such as Immunohistochemistry using Anti-Nucleoprotein antibodies. Other methods like viral isolation by culture is not feasible as only paraffin embedded blocks are available.

As per studies by Sheih,the negativity on RT-PCR was seen more in cases with more than 10 days of illness as compared to those with less than 10 days. Probably a similar explanation can be offered in our case series, considering that the exact duration of illness was not known in most of the cases that were treated empirically outside our centre before presenting with serious illness.[5]

Study done by Iwasenko et al[20] claims that one-thirds of H1N1 cases may not have ; laboratory confirmation of infection unless serological testing is included for suspected cases.[20] The WHO also recommends additional lab testings by alternative methods for patients who have symptoms strongly suggestive of influenza.[21] So, we believe that the 34 cases in our study, which were highly suspected for novel H1N1 but RT-PCR negative, could have been diagnosed if adjuvant serological testing was done. As stated by Iwasenko[20], we also suggest that in cases of influenza-like critical illness during known influenza pandemic, influenza treatment should be initiated prior to receiving laboratory confirmation. And in cases where RT-PCR does not detect H1N1, the clinical symptoms should determine whether treatment for influenza should be continued. We also suggest continuing the quarantine of such cases, till complete clinical recovery.

Taking into consideration the stringent criteria and resources for conducting post mortem examination of highly infectious, proven H1N1 positive cases, a complete autopsy study was not feasible at our centre. In order to minimize the risk of exposure to the health professionals as well to serve the purpose of HPE examination, post mortem needle biopsy seemed to be the most promising apporoach. However, the yield and efficiency could have been further enhanced by taking multiple samples from each lung lobe bilaterally , and might have eliminated the disparity of findings between our study and other autopsy based studies.

To conclude, the pathology of H1N1 Influenza can be effectively studied by a needle-biopsy approach, thus avoiding the need for complete post-mortem examination in view of high infectivity. It can also help in establishing H1N1 status when coupled with IHC so that an accurate estimate of the disease prevalence and mortality can be obtained for epidemiological purposes.

REFERENCES

Chawla R, Sharma RK, &Bhardwaj JR. &Influenza A (H1N1) outbreak and challenges for pharmacotherapy. Indian J Physiol Pharmacol. 2009; 53(2):113-26. | 1. Cunha BA, &Syed U, &Mickail N, &Strollo S.Rapid clinical diagnosis in fatal swine influenza (H1N1) pneumonia in an adult with negative rapid influenza diagnostic tests (RIDTs): diagnostic swine influenza triad. Heart Lung.2010; 39(1):78-86. | 2. Al Hajjar S,& McIntosh K. The first influenza pandemic of the 21st century. Ann Saudi Med.2010; 30 (1):1-10. | 3. Mauad T,& Hajjar LA,& Callegari GD et al. Lung pathology in fatal novel human influenza A(H1N1) infection. Am J Respir Crit Care Med.2009;181:72-79 | 4. Sheih Wun-Ju. Pathology and Pathogenesis of 2009 Pandemic H1N1 Influenza.Centers For Disease Control And Prevention. Retrived from:http://www.uscap.org/site~/99th/pdf/companion05h03.pdf | 5. Mukhopadhayaya S, &Philip AT, &Stoppacher R.Pathologic Findings In Novel Influenza A(H1N1) Virus("Swine Flu") Infection. Am J Clin Pathol.2010; 133:380-87. | 6. Harms PW, &Schmidt LA, &Smith LB et al. Autopsy Findings in Eight patients With Fatal H1N1 Influenza. Am J Clin Pathol. 2010; 134:27-35. | 7. Gill JR, &Sheng ZM, &Ely SF.Pulmonary Pathologic Findings of Fatal 2009 Pandemic Influenza A/H1N1 Viral Infections. Arch Pathol Lab Med. 2010; 134:235-43. | 8. Noble RL, &Lillington GA, &Kempson RL.Fatal Diffuse Influenzal Pneumonia: Pre-mortem Diagnosis by Lung Biopsy.Chest.1973; 63: 644-47. | 9. Yeldandi AV&,Colby TV.Pathologic Features Of Lung Biopsy Specimens From Influenza Pneumonia Cases.Hum Pathol.1994;25:47-53. | 10. Takiyama A,&Wang L,&Tanino M et al.Sudden Death Of A Patient With Pandemic Influenza (A/H1N1 pdm) Virus Infection By Acute Respiratory Distress Syndrome.Jpn J Infect Dis.2010;63:72-74. | 11. CDC. Hospitalised patients with novel Influenza A (H1N1) virus infection-California, April-May 2009.MMWR 2009; 58:536-41. Retrived from: http://www.cdc.gov/mmwr/preview/mmwrhtml/mm5819a6.htm | 12. CDC. Intensive–care patients with severe novel Influenza A (H1N1) virus infection- Michigan, June 2009.MMWR 2009; 749-52Retrived from: http://www.cdc.gov/mmwr/preview/mmwrhtml/mm5827a4.htm | 13. Louie J,&Jean C,& Chen TH et al.Bacterial coinfections in lung tissue specimens from fatal cases of 2009 pandemic influenza A(H1N1)-United States ,May-August 2009.MMWR.Retrived from:http://www.cdc.gov/mmwr/preview/mmwrhtml/mm58e0929a1.htm | 14. Esper RC,& Bustos EP,&Arroyo SO et al.Liver Involvement in severe human influenza A H1N1.Annals of Hepatology .2010;9(1):107-11. | 15. Duchini A et al. Hepatic decompensation with cirrhosis during infection with Influenza A.Arch Intern Med .2000; 160:113-15. | 16. Kang ES et al.Potential for hepatic and renal dysfunction during Influenza B infection, convalescence, and after induction of secondary viremia.J Exp Pathol.1992; 6:133-44. | 17. Murphy M. Sequestration of Coenzyme A by the industrial surfactant,Toximul MP8 A possible role in the inhibition of fatty acid β-oxidation in surfactant/influenza B mouse model for acute hepatic encephalopathy. Biochemica et Biophysica Acta.1997;1361:103-13. | 18. Murphy B, &Webster R.Orthomyxoviruses.Philadelphia, USA: JB Lippincott; 1996. | 19. Iwasenko J M, &Cretikos M, &PatersonDL et al .Clinical Infectious Diseases. 2010; 51(1):70-72. | 20. World Health Organization (WHO). WHO information for laboratory diagnosis of pandemic (H1N1) virus in humans- revised. 23Nov2009 Retrived from. http://www.who.int/csr/resources/publications/swineflu/WHO_Diagnostic_RecommendationsH1N1_20090521.pdf.Accessed10May2010. |